

# Secondary malignancies mimicking primary pancreatic lymphoma

Primer pankreatik lenfomayı taklit eden sekonder malignensiler

**İbrahim Petekkaya<sup>1</sup>, Emir Charles Roach<sup>2</sup>, Gamze Gezgen<sup>2</sup>, Musturay Karcaaltıncaba<sup>3</sup>, Ayşegül Üner<sup>4</sup>, Emine Petekkaya<sup>5</sup>, Kadri Altundağ<sup>2</sup>**

<sup>1</sup>Gaziantep Dr. Ersin Arslan State Hospital, Department of Medical Oncology, Gaziantep, Turkey

<sup>2</sup>Hacettepe University, Faculty of Medicine, Department of Oncology, Ankara, Turkey

<sup>3</sup>Hacettepe University, Faculty of Medicine, Department of Radiology, Ankara, Turkey

<sup>4</sup>Hacettepe University, Faculty of Medicine, Department of Pathology, Ankara, Turkey

<sup>5</sup>Zirve University, Emine Bahaeddin Nakıboğlu Medical Faculty, Department of Anatomy, Gaziantep, Turkey

## Abstract

Malignancies localized to the pancreas at times can mimic many other types of cancer. In imaging studies, tumors localized to the pancreas can resemble lymphoma. Especially in elderly patients, these tumors which appear like pancreatic cancer are sometimes left untreated by physicians, without confirming with biopsy, because the expected survival is extremely short. In this case report we examine how these discrepancies could be resolved.

**Keywords:** Lymphoma; pancreas

## Özet

Pankreas yerleşimli malignensiler birçok kanser alt tipi ile karışabilmektedir. Pankreas bölgesi tümörleri görüntüleme lenfoma ile karışabilir. Özellikle yaşlı hastalarda pankreas kanseri görünümü veren bu tümörler doktorlar tarafından ilginç olarak biyopsi yapılmadan yaşam süresi kısa olduğu belirtilip tedavisiz bırakılmaktadırlar. Vaka çalışmamızda bu tür karışıklıkların nasıl giderileceğini inceleyeceğiz.

**Anahtar kelimeler:** Lenfoma; pankreas

## Introduction

The differentiation of pancreatic malignancies can pose a challenge in some cases. Imaging studies form the basis of diagnosis in most cases. The gold standard for diagnosis, however, is biopsy. Primary pancreatic lymphoma (PPL) is a very rare clinical entity which makes up to 0.5% of all pancreatic malignancies, should be considered in the differential diagnosis in cases with suspected primary pancreatic malignancies such as pancreatic adenocarcinoma or cholangiocellular carcinoma which can also present in the same vicinity. Here we present a case which was initially considered for palliative treatment with a diagnosis of a primary pancreatic malignancy that was identified as primary pancreatic lymphoma. After successful diagnosis, administration of chemotherapy led to complete regression.

## Methods

The demographics of the patient were acquired by a thorough medical history; the clinical progress was followed up closely. The medical files were obtained from their respective institutions. The clinical opinions regarding the treatment protocols of the patient, pathological examinations, imaging studies

were obtained from oncology, pathology and radiology specialists respectively. The initial diagnosis was established by recommendations of the abdominal imaging specialist, however treatment was not initiated until the diagnosis was confirmed by pathological examination.

## Case Report

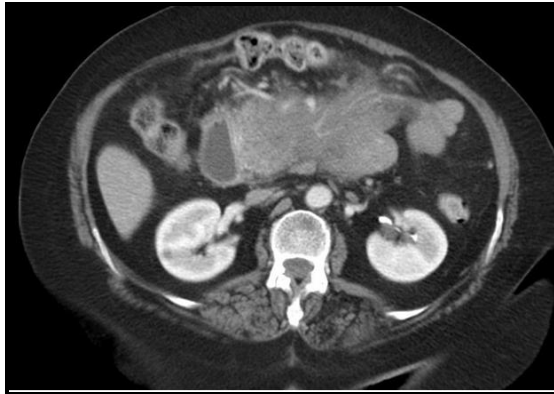A 72 year old patient presented with abdominal pain, constipation, lack of appetite, distention, nausea and vomiting, night sweats, fever, weight loss, which had been going on for a week. The patient was admitted to the hospital and was followed up with restriction of oral intake. At first, the clinical presentation suggested primary cholangiocellular carcinoma or pancreatic adenocarcinoma. An abdominopelvic computed tomography (CT) was performed which revealed a mass originating from the uncinate process of the pancreas and showing vascular invasion, extension into the jejunum and duodenum, causing stenosis of superior mesenteric vein (Figure 1). Additionally, an increase in the density of the omentum which suggested infiltration was observed. For histopathological diagnosis, the patient was referred to interventional radiology. Fine needle aspiration biopsy revealed atypical cells, blastic in character, with large nuclei, apparent nucleoli, increased mitosis, consistent with high grade

**Correspondence:** İbrahim Petekkaya, Gaziantep Dr. Ersin Arslan State Hospital, Department of Medical Oncology, Şahinbey, 27100 Gaziantep, Turkey  
Tel: +90 342 2210700/3222 [drpetekkaya@gmail.com](mailto:drpetekkaya@gmail.com)

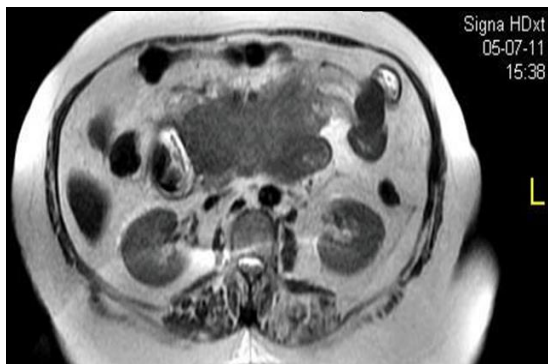
**Received:** 27.03.2014 **Accepted:** 15.04.2014  
ISSN 2148-3132 (print) ISSN 2148-2926 (online)  
[www.gaziantepmedicaljournal.com](http://www.gaziantepmedicaljournal.com)  
DOI: 10.5455/GMJ-30-156212



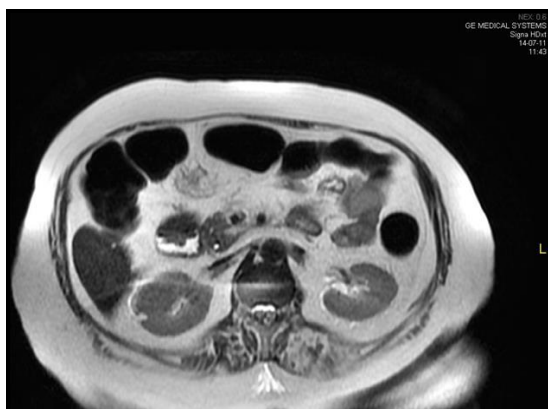
lymphoma. Flow cytometry was inconclusive. A bone marrow biopsy was performed in order to identify the clinical prognosis and chemotherapy regimen. Bone marrow biopsy showed normocellular pattern. In order to evaluate the invasion pattern, an abdominal magnetic resonance imaging was performed which revealed a soft tissue mass which extended from the uncinate process of the pancreas, to the root of the mesentery, consistent with lymphoma (Figure 2A).



**Figure 1.** Mass originating from the uncinate process of the pancreas and showing vascular invasion, extension into the jejunum and duodenum, causing stenosis of superior mesenteric vein.



A



B

**Figure 2.** Magnetic resonance imaging showing a soft tissue mass which extended from the uncinate process of the pancreas, to the root of the mesentery, consistent with lymphoma (A). MRI performed a week after the initiation of the treatment, revealing near-complete regression of the mass (B).

The patient was then referred to the gastroenterology department due to invasion into the duodenum and jejunum and the clinically apparent obstruction. An endoscopy was performed. Gastric contractions were seen to be insufficient, and the gastrointestinal tract was dilated. Furthermore, hyperemic lesions in the second part of the duodenum (D2) which were assumed to be a result of the malignant infiltration were identified. A biopsy was performed. The histopathological studies were consistent with high grade B-cell infiltration. Rituximab-Cyclophosphamide-Oncovine-Prednisone (R-CVP) regimen was initiated. The patient's LDH level was identified as 749  $\mu$ /l,  $\beta_2$  microglobulin was measured to be 1835 ng/ml, which suggested tumor lysis syndrome, after which prophylactic hydration and allopurinol treatment was initiated. Immunohistochemical studies conducted on the pathology specimens revealed that the neoplastic cells were CD 20 positive and the ki-67 index was shown to be 90-95%. Patient received 3 courses of R-CVP; however, he passed away due to neutropenic fever and sepsis as a complication of the chemotherapy.

For evaluation of response to the treatment an abdominal MR was performed a week after the initiation of the treatment, which revealed near-complete regression of the mass (Figure 2B). In addition to the radiological regression, the intestinal obstruction was also resolved. The patient's nausea and vomiting lessened. Due to the clinical improvement, oral intake was started. In physical examination the patient's abdominal distention was also relieved. The bilirubin levels which rose, due to the obstructive effects of the mass, also decreased from 4.3 mg/dl to 2.25 mg/dl.

### Discussion

Primary pancreatic lymphoma, is a very rare clinical entity which makes up 0.5% of all pancreatic malignancies, that should be considered in the differential diagnosis in cases with suspected primary pancreatic malignancies. Among the diagnostic criteria for primary pancreatic lymphoma are the lymph node enlargement of superficial or mediastinal lymph nodes, a normal leukocyte count in the peripheral blood, main mass in the pancreas with lymph nodal involvement confined to the peripancreatic region, and no hepatic or splenic involvement. PPL predominantly occurs in men (male to female ratio of 7:1) and the mean age at presentation is 55.0 years (1). However, a more recent study has shown the male-female ratio to be 1.9 (1:9). The same article by Du et al. (2) included a literature review which identified 85 cases in English literature with primary pancreatic lymphoma. This case is the second that has been followed up in our institution (3).

The best modality for diagnosis of primary pancreatic lymphoma has been a subject of debate.

However, authors agree that whichever imaging procedure is selected, clinicians have to obtain a cytohistological evidence for the precise diagnosis and further treatment planning. CT and ultrasound are the most common imaging techniques used for the detection of PPL. A study conducted in 2006 has identified unique qualities of PPL in CT: a well-defined mass and a large infiltrating lesion with poorly defined contours (4). Another study has shown that endoscopic ultrasound shows a hypoechoic lesion that has cystic and solid components and a central stellate fibrous tissue band that is echogenic opposed to the mass (5). We used both imaging techniques together. In our patient the initial suspicion that this might be a case of primary pancreatic lymphoma arose from the interpretation of the abdominal imaging specialist. Afterwards, an endoscopic fine needle aspiration biopsy was performed. This approach is consistent with literature which has shown that not only endoscopic ultrasound-guided fine-needle aspiration (EUS-FNA) has dramatically improved our ability to sample pancreatic solid lesions (6), but also that EUS-FNA is a safe and accurate method in evaluating pancreatic masses, especially in the presence of an on-site cytopathologist who can provide a real-time determination of whether a specimen is adequate or additional samples are necessary (7-9). Other studies however, have shown that CT guided biopsy may also be an option (10).

PPL does not have a specific biochemical marker. The serum CA19-9 level is normal or slightly elevated in PPL patients, whereas in pancreatic adenocarcinoma patients, 80% of the patients have a high CA19-9 level (11). Another study has shown that a higher than 200 U/ml value of CA19-9 is strongly suggestive of pancreatic adenocarcinoma, a finding that may help in differential diagnosis (12).

The treatment of primary pancreatic lymphoma varies in literature. The variety of options includes chemotherapy, radiotherapy, or a combination. Behrns et al. (13) has reported that it is difficult to obtain long-term survival by chemotherapy alone, and Battula et al. (4) has shown that 5-year survival rate of PPL treated with current chemotherapy was less than 50%, and its rate was inferior to combination of surgical procedure and chemotherapy, therefore they concluded that pancreaticoduodenectomy may have a therapeutic role in association with chemotherapy. On the other hand, another study has shown that out of 10 PPL patients who underwent explorative surgery, in only 3 of them, the tumor could be fully resected (14). Sugishita et al. (15) has successfully treated a patient with the combination of surgery and 8 cycles of R-CHOP and followed up the patient with no signs of recurrence for 4 years. Our patient has shown a dramatic response to the R-CVP regimen.

To summarize, primary pancreatic lymphoma should be involved in the differential diagnosis of primary pancreatic and peripancreatic malignancies. At first, our patient's clinical presentation suggested primary cholangiocellular carcinoma or pancreatic adenocarcinoma both of which have worse prognosis when compared to primary pancreatic lymphoma, and would require completely different treatment strategies.

We would like to conclude by stating that the gold standard for the differential diagnosis and treatment of PPL is yet to be established. A prospective controlled study with a large population of patients is warranted to clear out the controversies.

### References

1. Nayer H, Weir EG, Sheth S, Ali SZ. Primary pancreatic lymphomas: a cytopathologic analysis of a rare malignancy. *Cancer* 2004;102(5):315-21.
2. Du X, Zhao Y, Zhang T, Liao Q, Dai M, Liu Z, et al. Primary pancreatic lymphoma: a clinical quandary of diagnosis and treatment. *Pancreas* 2011;40(1):30-6.
3. Kav T, Soyuzo AG, Altundag K, Bayraktar Y. Primary pancreatic lymphoma or secondary involvement: what is the difference? *JOP. J Pancreas (Online)* 2010;11(5):482-3.
4. Battula N, Srinivasan P, Prachalias A, Rela M, Heaton N. Primary pancreatic lymphoma: diagnostic and therapeutic dilemma. *Pancreas* 2006;33(2):192-4.
5. McCauley AM, Gottlieb KT. Primary pancreatic lymphoma coexisting with chronic lymphocytic leukemia: EUS findings. *Gastrointest Endosc* 2008;68(1):188-9.
6. Chang KJ. State of the art lecture: endoscopic ultrasound (EUS) and FNA in pancreatico-biliary tumors. *Endoscopy* 2006;38(Suppl 1):S56-60.
7. Klapman JB, Logrono R, Dye CE, Waxman I. Clinical impact of on-site cytopathology interpretation on endoscopic ultrasound-guided fine needle aspiration. *Am J Gastroenterol* 2003; 98(6):1289-94.
8. Jhala NC, Jhala DN, Chhieng DC, Eloubeidi MA, Eltoun IA. Endoscopic ultrasound-guided fine-needle aspiration. A cytopathologist's perspective. *Am J Clin Pathol* 2003;120(3):351-67.
9. Rossi ED, Larghi A, Verna EC, Martini M, Galasso D, Carnuccio A, et al. Endoscopic ultrasound-guided fine-needle aspiration with liquid-based cytologic preparation in the diagnosis of primary pancreatic lymphoma. *Pancreas* 2010;39(8):1299-302.
10. Tucheck JM, De Jong SA, Pickleman J. Diagnosis, surgical intervention, and prognosis of primary pancreatic lymphoma. *Am Surg* 1993;59(8):513-8.
11. Lin H, Li SD, Hu XG, Li ZS. Primary pancreatic lymphoma: report of six cases. *World J Gastroenterol* 2006;12(31):5064-7.
12. Forsmark CE, Lambiase L, Vogel SB. Diagnosis of pancreatic cancer and prediction of unresectability using the tumor-associated antigen CA19-9. *Pancreas* 1994;9(6):731-4.
13. Behrns KE, Sarr MG, Strickler JG. Pancreatic lymphoma: is it a surgical disease? *Pancreas* 1994;9(5):662-7.
14. Bouvet M, Staerckel GA, Spitz FR, Curley SA, Charnsangavej C, Hagemester FB, et al. Primary pancreatic lymphoma. *Surgery* 1998;123(4):382-90.
15. Sugishita H, Watanabe Y, Yamamoto Y, Yoshida M, Sato K, Horiuchi A, et al. Primary pancreatic lymphoma: the role of surgical treatment. *Case Rep Gastroenterol* 2010;4(1):104-10.

**How to cite:**

Petekkaya İ, Roach EC, Gezgen G, Karcaaltıncaba M, Üner A, Petekkaya E, Altundag K. Secondary malignancies mimicking primary pancreatic lymphoma. Gaziantep Med J 2014;20(3):270-273.