

Striatocapsular infarction and acquired stuttering

Striatokapsüler enfarktüs ve edinilmiş kekemelik

Osama Shukir Muhammed Amin

Department of Neurology and Stroke, Shorsh Military General Hospital, Sulaimaniya, Iraq.

Abstract

Striatocapsular infarction may result in a multitude of language and speech disturbances. Acquired stuttering is a rare speech disorder that occurs as an aftermath of this stroke syndrome. We report on the case of 60-year-old right-handed woman who presented with acute right-sided hemiparesis and stuttering. Language assessment revealed intact comprehension, naming, reading and writing. When the patient spoke spontaneously, there were frequent initial prolongations with repetition of initial syllables. There was no word-finding difficulty or paraphasia. Her stuttering improved remarkably after few weeks but persistent in a very mild degree. Acute striatocapsular infarction-induced acquired stuttering is rare. It may be a transient event and generally holds a good prognosis. It can occur without subcortical aphasia or dysarthria.

Keywords: Striatocapsular infarction; acquired stuttering; speech disorder

Özet

Striatokapsüler enfarktüs bir çok dil ve konuşma bozukluklarına neden olabilmektedir. Edinilmiş kekemelik bu inme sendromunun ardından ortaya çıkan nadir bir konuşma bozukluğudur. Akut sağ-tarafli hemiparezi ve kekemelik ile başvuran 60 yaşındaki sağ el-dominant bir kadın vakayı sunmaktayız. Dil değerlendirmesinde anlama, adlandırma, okuma ve yazma intakt saptandı. Hasta spontan konuştuğunda ilk hecelerin tekrarı ile uzatması saptandı. Parafazi ya da kelime bulmakta güçlük yoktu. Kekemeliği birkaç hafta sonra belirgin olarak iyileşti ancak çok hafif derecede kaldı. Akut striatokapsüler enfarktüs kaynaklı edinilmiş kekemelik nadir olup, prognozu genellikle iyi olup, geçicidir. Subkortikal afazi ya da dizartri olmaksızın da oluşabilir.

Anahtar kelimeler: Striatokapsüler enfarktüs; edinilmiş kekemelik ; konuşma bozukluğu

Introduction

Striatocapsular infarction is an uncommon form of deep hemispheric (sub cortical) ischemic strokes. It generally results in a variable combination contra lateral facial weakness, hemi paresis and hemi sensory neglect/inattention. A variety of language and speech disorders have been documented. Stuttering is a form of speech dysfluency which repetition of sounds or words, prolonged pauses or excessively long sounds in words occur. Approximately 80% of stuttering cases are developmental; the rest are acquired. Acquired stuttering results from brain injuries (e.g. ischemic stroke, tumours, and head trauma). Psychogenic stuttering is a rare cause of acquired stuttering. Stuttering should be differentiated from other forms of language and speech disorders such as dysphasia, dysarthria, apraxia of speech, anomia, palilalia, and acute global confusional states (1-4).

Case presentation

A 60-year-old right-handed woman was brought to Emergency Department because of few hours' history of sudden right-sided weakness and speech disturbance. The patient was a high school teacher and was hypertensive and hyperlipidemic. Her daily medications were ramipril, hydrochlorothiazide, and

atorvastatin. The patient's family denied head trauma or illicit drug ingestion. The blood pressure was 175/100 mmHg with a regular pulse rate of 92 beats per minute and a respiratory rate of 10 cycles per minute. She was afebrile.

The patient was consciousness and oriented to time, place, and person. As an instrument to assess language function and aphasia, the Western Aphasia Battery-Revised (WAB-R) was carried out by 3 independent examiners; the full battery was conducted. Language assessment revealed intact comprehension, naming, reading, and writing. When the patient spoke spontaneously, we noticed frequent initial prolongations with repetition of initial syllables. She spoke English very well. She said, "I I I'm aaattteacher." There was no word finding difficulty or paraphasias. Muscle power testing revealed right-sided pyramidal weakness of grade 2 in the upper limb, and grade 3 in the lower limb. There was right-sided extensor planter reflex.

The results of complete blood counts, erythrocyte sedimentation rate, urea and electrolytes, liver function testing, serum thyroid stimulating hormone, and general urine examination were within their normal reference range. Serum lipid profile on the day of admission revealed combined hyperlipidemia with serum cholesterol of 260 mg/dl (normal <200 mg/dl) and serum

Correspondence: Osama S.M. Amin MD, MRCP(Ire), FCCP, FACP, FRCP(Glasg) Sulaimaniya Post-Office, PO BOX 196, Sulaimaniya City, Kurdistan Region, Iraq
Tel:+96 47703515964 dr.osama.amin@gmail.com

Received:02. 07. 2014 Accepted: 23. 10. 2014
ISSN 2148-3132 (print) ISSN 2148-2926 (online)
www.gaziantepmedicaljournal.com
DOI: 10.5455/GMJ-30-163323



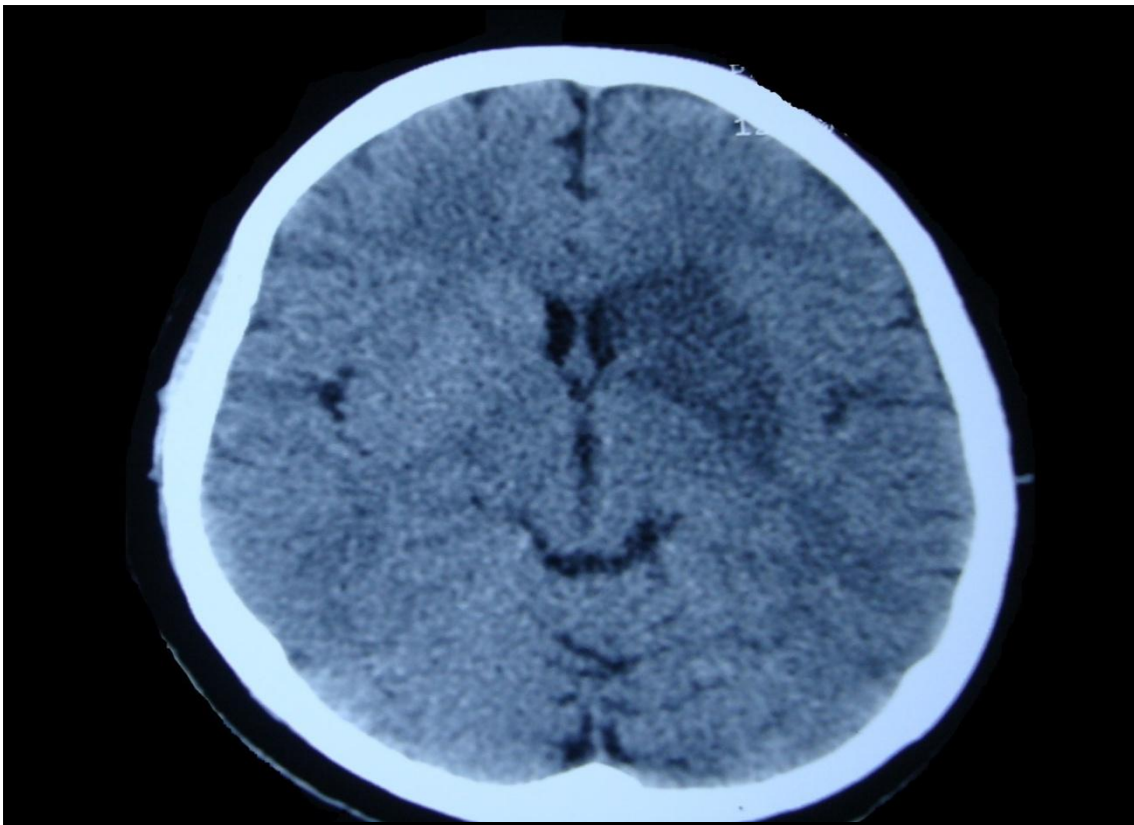


Figure 1. Non-contrast CT scan of the patient at the level of the basal ganglia and thalami which was performed 24 hours after presentation to the Emergency department, as the initial CT scan was normal-looking. There is a left-sided inverted comma-shaped hypodense lesion which covers the area of the left putamen, globus pallidus, head of caudate nucleus, and the anterior limb of the internal capsule. The overlying cortex and adjacent thalamus are intact. This is striatocapsular infarction.

triglyceride of 220 mg/dl (normal <150 mg/dl). 12-lead ECG was unremarkable and transthoracic echocardiography revealed diastolic dysfunction with an ejection fraction of 62%. Carotid Doppler assessment showed right common carotid artery stenosis of 43% and left common/internal carotid artery stenosis of 57%. Urgent non-contrast CT brain scan was unremarkable at the time of presentation and it was repeated after 24 hours; there was infarction of the left putamen and globus pallidus (figure one). The patient was discharged after one week of hospitalization and was prescribed aspirin in addition to increasing the daily doses of the previous medications. She demonstrated muscle power of grade 3 in the right arm and grade 4 in the right leg. Her stuttering had improved a little bit. The patient was seen after 6 and 12 weeks; the right-sided weakness was more or less the same. There was mild repetition of initial syllables. The patient herself had noticed a remarkable improvement in her speech.

Discussion

The human putamen, parts of the globus pallidus, body of caudate nucleus, claustrum, and anterior and posterior limbs of internal capsules are supplied by the lateral lenticulostriate arteries which branch of the posterior/superior aspect of the main stem of the middle cerebral artery; some minor vascular

contribution also comes from the artery of Heubner and anterior choroidal arteries. When the lateral lenticulostriate arteries become blocked, striatocapsular infarction ensues (1-4). This is defined as an inverted comma-shaped softening in the area of the basal ganglia of at least 3 cm in length and 1 cm in width (1,2).

A variety of subcortical language and speech disorders have been described in this syndrome; subcortical aphasia, subcortical dysarthria, hypokinesia of speech, and abulia were considered common accompaniments of striatocapsular infarctions of the dominant hemisphere (1, 5,6).

Acute stroke-induced stuttering has been observed by many researchers but stuttering resulting from striatocapsular infarction was rarely reported (7-14). Research concerning the nature of stuttering has produced an extensive amount of data during the past century, but the mechanisms behind the speech disruptions and the speech initiation problems are still not clear (15). In the year 2005, Alm published an extensive review article about the role of basal ganglia circuits in the development of stuttering (15). Alm concluded that there are strong indications that the basal ganglia-thalamocortical motor circuit, through the putamen to the supplementary motor

area, plays an important role in the pathophysiology of stuttering. The dysfunction may have various causes and may be the effect of interaction between several factors (15). He also found that the core dysfunction in stuttering is suggested to be impaired ability of the basal ganglia to produce timing cues.

According to Grant and colleagues, the clinical presentation of stroke-associated stuttering is variable, as are the locations of the implicated infarctions (13). However, they found that there is a core and common features; most cases of acquired stuttering resulted from injury to the dominant hemisphere (as in our patient). Kono and coworkers concluded that in striatocapsular infarctions, the stuttering arose from a collapse of basal ganglia circuits that connect the cerebral cortex and basal ganglia, including the extrapyramidal tract system (14).

According to Ciabarra and colleagues, the following mechanisms are proposed to be the culprits behind the development of acquired stuttering in subcortical ischemic strokes: impaired regulatory callosal transmission; damage to circuits connecting the basal ganglia to the cortex; and cortical dysfunction resulting from subcortical infarction (10). Grant and colleagues studied four cases of stroke-induced acquired stuttering; these cases demonstrate that acquired stuttering may occur with or without an associated aphasia or dysarthria, and may be transient or permanent (13).

In summary, our patient's acquired stuttering had resulted from left (dominant) striatocapsular infarction. The patient's stuttering was severe at the outset and was not associated with subcortical aphasia or dysarthria. The stuttering improved remarkably after few weeks but had persisted in a mild degree.

References

1. Amin OS, Abdullah AA, Xaznadar A, Shaikhani M. Striatocapsular infarction; a single institutional experience. *Acta Inform Med* 2012;20(2):106-12.
2. Amin OS. Severe expressive dysphasia and an inverted comma: is it striatocapsular infarction? *J Neurol Disord Stroke* 2014; 2(2): 1040.
3. Amin OS. Acute dysarthria, dense left hemiparesis, and left sensory neglect: Is it striatocapsular infarction? *BMJ Case Reports* 2012; 10.1136/bcr-2012-007264, 19 October 2012.
4. Amin OS, Zangana HM, Ameen NA. The striatocapsular infarction and its aftermaths. *BMJ Case Rep* 2010; 10.1136/bcr.2010.270, 7 September 2010.
5. Nadeau SE, Crosson B. Subcortical aphasia. *Brain Lang* 1997;58(3):355-402. discussion: 418-23.
6. Bhatia KP, Marsden CD. The behavioural and motor consequences of focal lesions of the basal ganglia in man. *Brain* 1994;117(Pt 4):859-76.
7. Sahin HA, Krespi Y, Yilmaz A, Coban O. Stuttering Due To Ischemic Stroke. *Behavioural Neurology* 2006; 16(1):37-9.
8. Fawcett RG. Stroke-associated acquired stuttering. *CNS Spectr* 2005;10(2):94-5.
9. Turgut N, Utku U, Balci K. A case of acquired stuttering resulting from left parietal infarction. *Acta Neurol Scand* 2002;105(5):408-10.
10. Ciabarra AM, Elkind MS, Roberts JK, Marshall RS. Subcortical infarction resulting in acquired stuttering. *J Neurol Neurosurg Psychiatry* 2000; 69: 546-9.
11. Franco E, Casado JL, López Domínguez JM, Díaz Espejo C, Blanco A, Robledo A. [Stuttering as the only manifestation of a cerebral infarct]. *Neurologia* 2000;15(9):414-6.
12. Tsumoto T, Nishioka K, Nakakita K, Hayashi S, Maeshima S. [Acquired stuttering associated with callosal infarction: a case report]. *No Shinkei Geka* 1999;27(1):79-83.
13. Grant AC, Biousse V, Cook AA, Newman NJ. Stroke-associated stuttering. *Arch Neurol* 1999;56:624-7.
14. Kono I, Hirano T, Ueda Y, Nakajima K. [A case of acquired stuttering resulting from striatocapsular infarction]. *Rinsho Shinkeigaku* 1998;38(8):758-61.
15. Alm PA. Stuttering and the basal ganglia circuits: a critical review of possible relations. *J Commun Disord* 2004;37(4):325-69.

How to cite:

Amin O.S.M. Striatocapsular infarction and acquired stuttering. *Gaziantep Med J* 2014; 20(4): 342-344.