

## Extremely elevated serum CA125 and CA19-9 levels following the rupture of ovarian endometrioma: a case report

Ovaryan endometrioma rüptürünü takiben anormal düzeyde yükselen CA125 ve CA19-9 seviyeleri: olgu sunumu

Hüseyin Cengiz<sup>1</sup>, Şükrü Yıldız<sup>1</sup>, Levent Yaşar<sup>1</sup>, Murat Ekin<sup>1</sup>, Cihan Kaya<sup>1</sup>

<sup>1</sup>Bakırköy Dr. Sadi Konuk Research and Education Hospital, İstanbul

### Abstract

In gynecology, the serum CA125 and CA19-9 levels are elevated in patients with malignant and benign conditions especially in ovarian tumors. Although endometriosis is a benign condition, increased levels of the tumor markers CA125 and CA19-9 may be seen. We present a case demonstrated that abnormally high levels of plasma CA125 and CA19-9 encountered in bilaterally large ovarian endometrioma with rupture and the overflow of the thick "chocolate" cyst fluid throughout the abdominal cavity.

**Keywords:** CA125; CA 19-9; endometriosis; rupture

### Özet

Jinekolojide; serum CA125 ve CA19-9 düzeyleri başta over tümörleri olmak üzere benign ve malign durumlarda artış göstermektedir. Endometriosis benign bir durum olmasına rağmen CA125 ve CA19-9 düzeylerinde artış görülebilmektedir. Biz; bilateral ovaryan endometriomalı, abdominal kavitede kalın çikolata kist sıvısının izlendiği ve anormal yükseklikte CA125 ve CA19-9 plazma düzeylerinin saptandığı bir olgu sunmaktayız.

**Anahtar kelimeler:** CA125; CA19-9; endometriyoz; rüptür

### Introduction

The antigen CA125 was identified by Bast et al. (1) through the use of monoclonal antibodies raised against cells derived from the OVAL 433 ovarian cancer cell line; therefore, it has been proposed as a specific ovarian carcinoma marker. Serum CA19-9 levels are elevated in patients with certain types of malignant tumors, such as gastrointestinal adenocarcinoma, pancreatic carcinoma, and lung carcinoma (2,3); thus, measuring serum CA19-9 levels is useful to diagnose these tumors.

Serum CA125 and CA19-9 levels are elevated in patients with malignant and benign conditions, particularly ovarian tumors. Patients with endometriosis rarely have a CA125 concentration > 100 IU/ml, and the highest value reported thus far with histologically confirmed endometriosis is 9,300 IU/ml (4). Although endometriosis is a benign condition, increased levels of the tumor markers CA125 and CA19-9 may be observed. However, these tumor markers rarely reach very high levels. Here, we present the case of a patient with a ruptured ovarian endometrioma and exceptionally high serum CA125 and CA19-9 concentrations.

### Case

A 25-year-old, gravida 0, para 0 woman presented to our emergency department (ED) following 12 hr acute-onset, constant right-sided abdominal pain and nausea. Her menstrual cycle was regular and she was on day 8 of

a 28-day cycle. No remarkable history was noted, including sexually transmitted diseases, pelvic inflammatory disease, endometriosis, infertility, or prior abdominal surgery. A pelvic examination was performed by the ED physician using a bedside ultrasound performed. The examination revealed a left adnexial mass, which appeared to be large (6 × 8 cm in diameter). The echotexture was heterogeneous, and the mass had no solid areas with neovascular type peripheral flow. Free fluid in the pelvis was observed. (Figure 1).

On the physical examination, her pulse rate was 102 bpm and full and rhythmic arterial blood pressure was 100/70 mmHg. Her pelvic examination was remarkable for lower abdominal pain with light palpation. The white blood cell count was 18,000/mm<sup>3</sup> and hematocrit was 34.1%. CA125 and CA19-9 concentrations were 174.87 U/ml (enzyme immunoassay [EIA]; normal, < 35 IU/ml) and 1,198.38 U/ml (EIA; normal, < 35 IU/ml), respectively, before surgery. Emergency laparoscopic surgery was performed after admission.

During the laparoscopy, the uterus, bilateral fallopian tubes, and the right ovary were observed to be normal. A ruptured endometriotic cyst with dimensions of 6 cm x 6 cm was observed in the left ovary. The peritoneum was entirely covered by thick brown fluid from the ruptured cyst. Dense adhesions completely obliterated the cul-de-sac. The adhesions were lysed, and the cysts were enucleated. The pelvic cavity was irrigated thoroughly with saline. A histological examination confirmed the

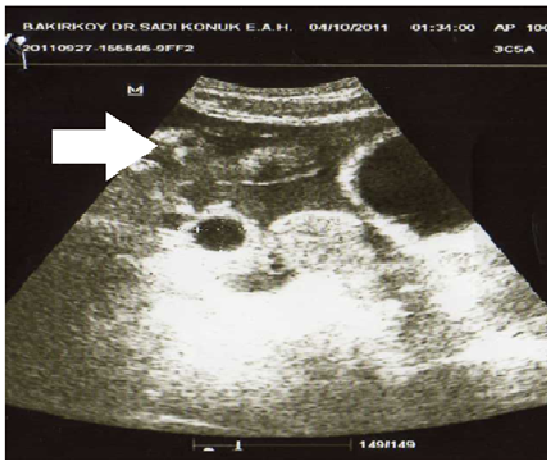**İletişim/Correspondence to:** Hüseyin Cengiz, Bakırköy Dr. Sadi Konuk Research and Education Hospital, İstanbul, TURKEY

Tel: +90 532 595 04 54 [obstetrik@gmail.com](mailto:obstetrik@gmail.com)

**Received:** 01.05.2012 **Accepted:** 16.05.2012  
**Geliş Tarihi:** 01.05.2012 **Kabul Tarihi:** 16.05.2012

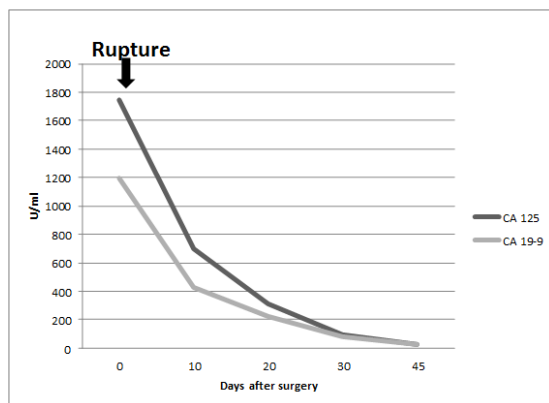
DOI: 10.5455/GMJ-30-2012-93  
[www.gantep.edu.tr/~tipdergi](http://www.gantep.edu.tr/~tipdergi)  
ISSN 1300-0888

diagnosis of endometrioma. The patient's postoperative course was uneventful.



**Figure 1.** Pelvic ultrasound before operation. White arrow: Fluid collection in pelvis.

Serum CA125 and CA-19-9 levels were periodically checked as follows: day 10 CA125, 697.9 U/ml and CA-19-9, 425.48 IU/ml; day 18 CA125, 311.5 U/ml and CA-19-9, 221.28 IU/ml; one month CA125, 92.4 U/ml and CA-19-9, 83.63 IU/ml. The markers were below the detection limit on postoperative day 45 (Figure 2). A postoperative physical examination, ultrasound scan, and magnetic resonance imaging were all normal, and the patient has not had any complaints.



**Figure 2.** Changes in serum CA125 and CA19-9 levels.

### Discussion

CA125 may be elevated in patients with endometriosis, benign ovarian cysts, torsion of an ovarian tumor, tubo-ovarian abscess, hyperstimulation syndrome, ectopic pregnancy, and fibroids (5-8). CA19-9 may increase with many types of gastrointestinal malignancies, pulmonary cancers, and some ovarian tumors. CA19-9

levels also increase in cases of endometriosis, but its sensitivity is less than that of CA125 (9). The diffusion of cyst fluid containing CA125 and CA19-9 molecules after rupture of the endometrioma through the peritoneal surface into the circulation likely contributed to the rapid increase in serum CA125 and CA19-9 concentrations in the present case, but not to their persistent elevation (10).

In our case, the contents of the ruptured endometrioma may have increased the serum tumor antigen levels. However, the serum tumor antigen levels did not continuously increase due to the absence of malignant conditions.

In conclusion, some CA125 and CA19-9 molecules from the ruptured ovarian tumor may have been transferred through the peritoneum, thereby increasing serum CA125 and CA19-9 concentrations to very high levels in our patient. In young patients whose serum tumor antigen levels are extremely high, the diagnosis may also be a ruptured endometrioma, and the first-line treatment should be laparoscopy. In addition, CA125 and CA19-9 concentrations should be used as a part of the treatment and follow-up for patients.

### References

1. Bast RCJ, Feeney M, Lazarus H. Reactivity of a monoclonal antibody with human ovarian carcinoma. *J Clin Invest* 1981;68:1331-37.
2. Ohshio G, Yamaki K, Imamura T, Suwa H, Chang CY, Wada H, et al. Distribution of the carbohydrate antigens, DU-PAN-2 and CA19-9, in tumors of the lung. *Tumori* 1995;81:67-73.
3. Del Villano BC, Brennam S, Brock P, Bucher C, Liu V, McClure M, et al. Radioimmunometric assay for a monoclonal antibody-defined tumor marker, CA19-9. *Clin Chem* 1983;29:549-52.
4. Johansson J, Santala M, Kauppila A. Explosive rise of serum CA 125 following the rupture of ovarian endometrioma. *Hum Reprod* 1998;13:3503-4.
5. Kashyap RJ. Extremely elevated serum CA125 due to endometriosis. *Aust New Zealand J Obstet Gynaecol* 1999;39:269-70.
6. Kammerer-Doak DN, Magrina JE, Nemiro JS, Lidner TK. Benign gynecologic conditions associated with a CA-125 level > 1000 U/ml. A case report. *J Reprod Med* 1996;41:179-82.
7. Guerriero S, Ajossa S, Caffiero A, Mais V. Relationship between abnormally high levels of plasma CA 125 and resolution of acute pelvic pain in two women with endometrioma. *Gynecol Obstet Invest* 1995;40:61-3.
8. Abad A, Cazorla E, Ruiz F, Aznar I, Asins E, Llixiona J. Meigs' syndrome with elevated CA125: case report and review of the literature. *Eur J Obstet Gynecol Reprod Biol* 1999; 82:97-9.
9. Harada T, Kubota T, Aso T. Usefulness of CA19-9 versus CA125 for the diagnosis of endometriosis. *Fertil Steril*. 2002;78:733-9.
10. Kurata H, Sasaki M, Kase H, Yamamoto Y, Aoki Y, Tanaka K. Elevated serum CA125 and CA19-9 due to the spontaneous rupture of ovarian endometrioma. *Eur J Obstet Gynecol Reprod Biol*. 2002;105(1):75-6.