

Giant pulmonary artery aneurysm associated with mild congenital pulmonary stenosis

Hafif konjenital pulmoner darlık ile ilişkili dev pulmoner arter anevrizması

Osman Başpınar¹, Ahmet İrdem¹

¹University of Gaziantep, Faculty of Medicine, Department of Pediatric Cardiology, Gaziantep

Abstract

Pulmonary artery aneurysm is a rare condition. Poststenotic pulmonary artery dilatation and aneurysm may occur in congenital valvular pulmonary stenosis. We present an 11-year old girl referred to our clinic due to cardiac murmur detected by a physician during evaluation for back pain. We have noted mild congenital pulmonary stenosis and aneurysmatic dilatation of the main pulmonary artery (pulmonary artery diameter 5.6 cm) and performed pulmonary balloon valvuloplasty. Poststenotic aneurysmatic dilatation secondary to congenital valvular pulmonary stenosis is a rare clinical entity. Balloon valvuloplasty is a safe and effective treatment method if there is no pulmonary hypertension or congenital heart disease with left-to-right shunt.

Keywords: Pulmonary artery aneurysm; pulmonary valve; valvuloplasty.

Özet

Pulmoner arter anevrizması oldukça nadir görülen bir durumdur. Konjenital valvüler pulmoner darlıkta poststenotik pulmoner arter dilatasyon ve anevrizması gelişebilir. Sırt ağrısı şikâyeti ile gittikleri doktor tarafından kalpte üfürüm olması nedeni ile kliniğimize başvuran; pulmoner balon valvüloplasti uyguladığımız, hafif konjenital pulmoner darlık ve ana pulmoner arterde anevrizmatik genişleme (pulmoner arter çapı; 5.6cm) saptadığımız 11 yaşındaki olguyu sunduk. Doğumsal valvüler pulmoner darlığa seconder poststenotik anevrizmal dilatasyon nadir bir klinik tablodur. Pulmoner hipertansiyon ve soldan-sağa şanlı konjenital kalp hastalığı yoksa balon valvüloplasti güvenli ve etkili bir yöntemdir.

Anahtar kelimeler: Anevrizma; kalp; konjenital; pulmoner kapak; valvüloplasti.

Introduction

Pulmonary artery aneurysm is relatively a rare condition compared to systemic arterial aneurysm. Pulmonary artery aneurysm may occur congenitally or acquired secondary to septic emboli, tuberculosis, syphilis, atherosclerosis, Marfan syndrome, trauma (1). It is either asymptomatic or noted during autopsy. The prevalence of pulmonary artery aneurysm has been reported as 1/14000 in autopsy studies (2). Poststenotic pulmonary arterial dilatation may occur in cases of mild and moderate congenital valvular pulmonary stenosis (3-5). The dilatation may progressively transform into an aneurysm. These patients may sometimes admit to clinics due to symptoms aggravated by effort such as shortness of breath, coughing, and hemoptysis. A case of mild congenital valvular pulmonary artery stenosis admitted with back pain and successfully treated by balloon valvuloplasty is presented in this report.

Case

An 11-year old girl was referred to our clinic due to cardiac murmur detected by a physician during assessment for back pain. On physical examination, her blood pressure was noted as 110/60 mmHg and heart rate as 76/minute, rhythmic. There was no physical examination finding specific for connective tissue diseases. Genetic studies could not be done as the patient had no health insurance. Cardiovascular examination was normal except for a 3/6 systolic ejection murmur at left second intercostal space. Chest radiography revealed

enlargement of the pulmonary conus and 12-lead electrocardiography revealed right axis deviation. On transthoracic echocardiography, mild dilatation in right heart chambers, mean pulmonary valve stenosis with a gradient of 35 mmHg and an aneurysmatic dilatation of main pulmonary artery until the bifurcation were noted (Figure 1). Main pulmonary artery diameter was measured as 5.6 cm on thoracic tomography with no evidence of a significant compression on the bronchial tree (Figure 2). Following the injection of contrast medium during catheterization, the pulmonary valve was noted to be thick with limited motion; pulmonary artery was noted to be aneurysmatically dilated (Figure 3). Pulmonary valvuloplasty was performed for the stenotic pulmonary valve, and subsequent pressure gradient was noted as 17 mmHg. On postoperative transthoracic echocardiography, mild dilatation of the right heart chambers and mild tricuspid and pulmonary insufficiency and a mild residual pulmonary stenosis were noted. Poststenotic pulmonary dilatation and aneurysm were present. The patient was then discharged and called for regular follow-up visits.

Discussion

Pulmonary artery aneurysm has first been discovered as a fusiform aneurysm during the autopsy of an atherosclerotic patient by Bristowe in 1860 (6). In 1947, Deterling and Clagett have reviewed a total of 109.571 autopsies and noted pulmonary artery aneurysm in eight cases (6). Main pulmonary artery diameter of greater than 4 cm is defined as pulmonary artery aneurysm (7). Pulmonary artery aneurysm may occur as congenital or acquired due to several causes such as septic emboli,

İletişim/Correspondence to: Ahmet İrdem, University of Gaziantep, Faculty of Medicine, Department of Pediatric Cardiology, Gaziantep, TURKEY
Tel: +90 342 3606060/76449 irdem@gantep.edu.tr

Received: 07.01.2013 **Accepted:** 04.03.2013
Geliş Tarihi: 07.01.2013 **Kabul Tarihi:** 04.03.2013

DOI: 10.5455/GMJ-30-2013-126
www.gantep.edu.tr/~tipdergi
ISSN 1300-0888

tuberculosis, syphilis, atherosclerosis, Marfan syndrome, trauma and an underlying congenital heart disease with left-to-right shunt such as patent ductus arteriosus, ventricular septal defect and atrial septal defect in 50% of the patients (1). Mild valvular pulmonary stenosis was present in our patient. Development of pulmonary artery aneurysm subsequent to congenital valvular pulmonary stenosis is very rare. To our knowledge only five such case reports, most of which involving adult patients have been published (3,4).

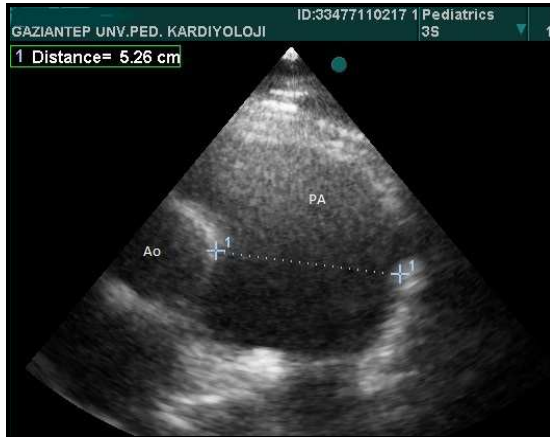


Figure 1. Aneurismatic dilatation of main pulmonary.

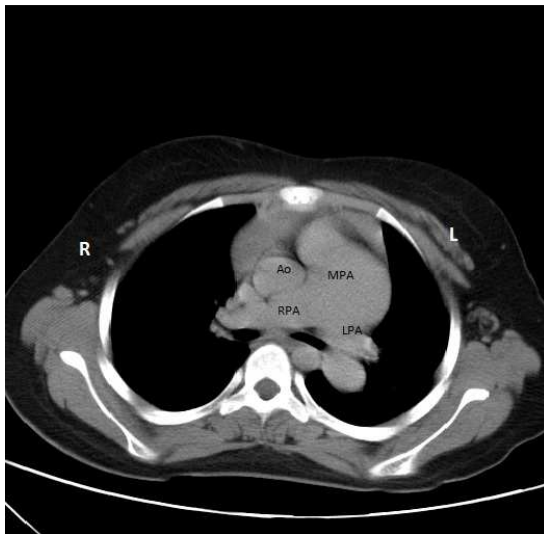


Figure 2. In the thoracic tomography no evidence of compression on the bronchial tree.

Most of these patients were asymptomatic or had nonspecific symptoms such as shortness of breath, back pain, chest pain, and hemoptysis. Surgical intervention may be considered in patients with hemoptysis and in the presence of large life-threatening aneurysms (8). Our patient had a nonspecific symptom of back pain. Back pain and chest pain can be due to the compression of surrounding structures by the dilated pulmonary artery in these patients (9). Pulmonary artery aneurysm is also associated with the risk of dissection and/or rupture (10).

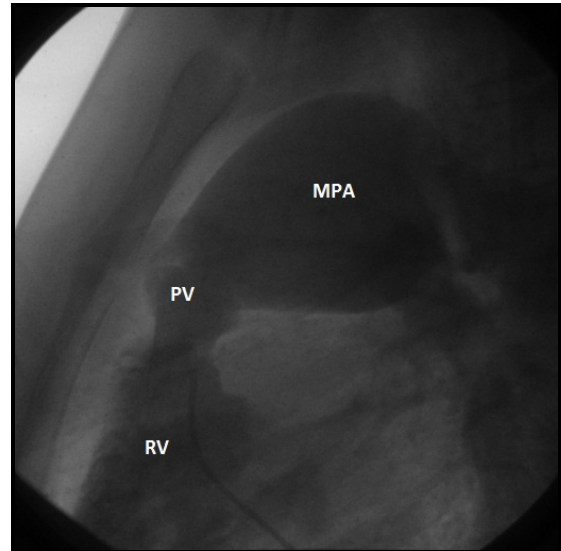


Figure 3. In the catheterization, aneurismatic pulmonary artery.

Poststenotic aneurysmal dilatation in the absence of an intracardiac shunt is possibly associated with the abnormal structure of the vessel wall. Balloon valvuloplasty is a safe and effective conservative approach which can be recommended in congenital valvular pulmonary stenosis in the absence of left-to-right shunt and pulmonary hypertension (3). Shindo et al. (5) reported that the dilatation of the pulmonary artery can slow blood flow, leading a small decrease in pulmonary artery pressure between the right ventricle and pulmonary artery. Balloon valvuloplasty was to be performed even to mild-moderate pulmonary artery stenosis as abnormal pulmonary artery wall structure can lead to aneurysmal dilatation of pulmonary arteries in follow-up of these patients. We agree Shindo and his colleagues opinion. In these patients the amount of pulmonary pressure gradient does not show the severity of pulmonary stenosis and the relief of the stenosis may have a positive effect on the aneurysmal dilatation. The rupture of the aneurysmal pulmonary artery can be very dangerous so we preferred to correct the comorbid problem.

References

1. Arom KV, Richardson JD, Grover FL, Ferris G, Trinkle JK. Pulmonary artery aneurysm. *Am Surg* 1978;44(10):688-92.
2. Shih HH, Kang PL, Lin CY, Lin YH. Main pulmonary artery aneurysm. *J Chin Med Assoc* 2007;70(10):453-5.
3. Fernandes V, Kaluza GL, Zymek PT, DeFelice CA, Hust R, Raizner AE. Successful balloon valvuloplasty in an adult patient with severe pulmonic stenosis and aneurysmal poststenotic dilatation. *Catheter Cardiovasc Interv* 2002;55(3):376-80.
4. Tami LF, McElderry MW. Pulmonary artery aneurysm due to severe congenital pulmonic stenosis. Case report and literature review. *Angiology* 1994;45(5):383-90.
5. Shindo T, Kuroda T, Watanabe S, Hojo Y, Sekiguchi H, Shimada K. Aneurysmal dilatation of the pulmonary trunk with mild pulmonic stenosis. *Intern Med* 1995; 34(3):199-202.
6. Deterling RA Jr, Clagett OT. Aneurysm of the pulmonary artery; review of the literature and report of a case. *Am Heart J* 1947;34(4):471-99.
7. Chetty KG, McGovern J, Mahutte CK. Hilar mass in a patient with chest pain. *Chest* 1996;109(6):1643-4.

8. Bartter T, Irwin RS, Nash G. Aneurysms of the pulmonary arteries. *Chest* 1988;94(5):1065-75.
9. Decuyper V, Delcroix M, Budts W. Left main coronary artery and right pulmonary vein compression by a large pulmonary artery aneurysm. *Heart* 2004; 90(4):e21.
10. Smalcelj A, Brida V, Samarzija M, Matana A, Margetic E, Drinkovic N. Giant, dissecting, high-pressure pulmonary artery aneurysm: case report of a 1-year natural course. *Tex Heart Inst J* 2005;32(4):589-94.