

# Laparoscopy-assisted mini-laparotomy: management of a giant (32 cm) ovarian cyst

Laparoskopi asiste mini-laparotomi: dev bir over kistinin (32 cm) yönetimi

Kahraman Ülker<sup>1</sup>, Mehmet Karaca<sup>2</sup>, İsmail Temur<sup>1</sup>, İslim Volkan<sup>1</sup>, Abdülaziz Gül<sup>1</sup>

<sup>1</sup>Kafkas University, School of Medicine, Department of Obstetrics and Gynecology, Kars

<sup>2</sup>Antalya Education and Research Hospital, Clinics of Obstetrics and Gynecology, Antalya

## Abstract

Ovarian cysts over 5 and 15 cm are described as large and giant, respectively. Ovarian cysts over 5 cm without regression in 6-8 weeks are indicated for surgery. Although there are published data about the laparoscopic or laparoscopy assisted management of the large and giant cysts, especially in cases of giant cysts midline laparotomy is preferred by many surgeons. In this paper, we present the management of a 32 cm mucinous ovarian cyst by laparoscopy-assisted mini-laparotomy.

**Keywords:** laparoscopy; laparoscopy-assisted surgery; minimal access surgical procedures; mucinous cystadenoma; ovary

## Özet

Over kistleri 5 cm'i aştıklarında büyük, 15 cm'i aştıklarında dev olarak adlandırılırlar. 5 cm'den büyük over kistleri 6-8 hafta içinde gerilemezse cerrahi tedavi gerekir. Büyük ve dev over kistlerinin yönetiminde yayınlanmış laparoskopik ya da laparoskopi asiste yöntemler olsa da, özellikle dev kistlerde laparotomi pek çok cerrah tarafından tercih edilir. Bu yazıda 32 cm'lik dev bir over kistinin laparoskopi asiste mini-laparotomi ile sağaltımını sunuyoruz.

**Anahtar kelimeler:** laparoskopi; laparoskopi asiste cerrahi; minimal access cerrahi işlemler; musinöz kistadenom; over

## Introduction

Minimally invasive surgery has been accepted widely as the standard management option when the preoperatively expected diagnosis is a benign cyst. However, the rupture of the cyst wall and spillage of its contents into the peritoneum, poorer vision caused by the large volume of the cyst and unexpected malignancy limit its use.

Ovarian cysts are the fourth most common gynecological cause of hospital admission in the United States. During their life time, 5-10% of the women in the United States are suspected to have a surgical procedure for a suspected ovarian neoplasm (1,2). Ovarian cysts over 5 and 15 cm are described as large and giant, respectively (3). Ovarian cysts over 5 cm without regression in 6-8 weeks are indicated for surgery. Although there are published data about the laparoscopic or laparoscopy-assisted management of the large and giant cysts, especially in cases of giant cysts midline laparotomy is still preferred by many surgeons.

In this report, we present the management of a 32 cm mucinous ovarian cyst by laparoscopy-assisted mini-laparotomy.

## Case

A 20 year old, unmarried female with the symptoms of abdominal pain, fullness, distension and bulging of whole abdomen resembling an eight month pregnancy applied to our hospital. At the beginning of the

symptoms she ignored the symptoms. However, bulging mass resembled pregnancy in time and the parents and her relatives began questioning her about pregnancy. The social pressure created by the surrounding people brought her to the gynaecologic consultation.

A homogeneous mass bulging through the whole abdominal cavity with a height of 32 cm from the pubis bone was noted in the physical examination of the patient (Figure 1). Ultrasound finding was a giant cyst originating from right ovary with the dimensions of 240x200x117cm. There was no sign of calcification, papillary protrusion, septate formation or multilocation of the cyst. In addition, the margins of the cyst wall were smooth and thin. Doppler ultrasound examination of the ovarian and the cyst vessels revealed no increase in vascularisation. Laboratory studies of tumour markers including CA 125 (26 U/ml), CA 19-9 (8 U/ml) and magnetic resonance imaging findings (Figure 2) supported the benign nature of the cystic mass.

Assuming the cyst to be benign in nature, we planned the surgery without oncological consultation. Under general anesthesia the patient was prepared sterile for surgery. We connected the Verres needle to the aspiration device and inserted it into the abdominal cavity at the mid-line, 2 cm above the pubic margin (Figure 3). Following the aspiration of 4 litres of fluid the cyst volume decreased, and then we created pneumoperitoneum and introduced a 10 mm trocar into the abdominal cavity from the lower border of the umbilical fold. By introducing the telescope into the trocar we performed diagnostic laparoscopy.

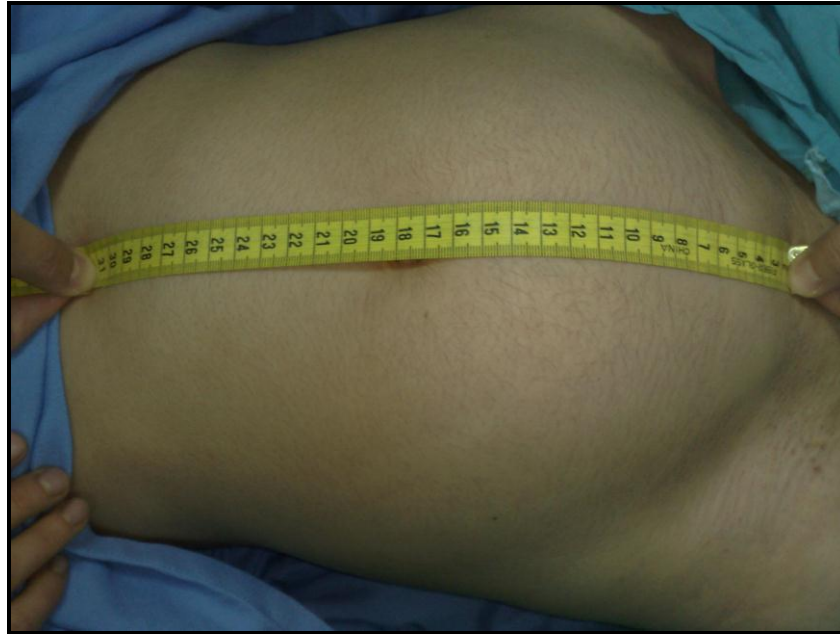**İletişim/Correspondence to:** Kahraman Ülker, Kafkas University, School of Medicine, Department of Obstetrics and Gynecology, Kars, TURKEY  
Tel: +90 505 570 0574 kahramanulker@hotmail.com

**Received:** 06.06.2011 **Accepted:** 24.06.2011  
**Geliş Tarihi:** 06.06.2011 **Kabul Tarihi:** 24.06.2011

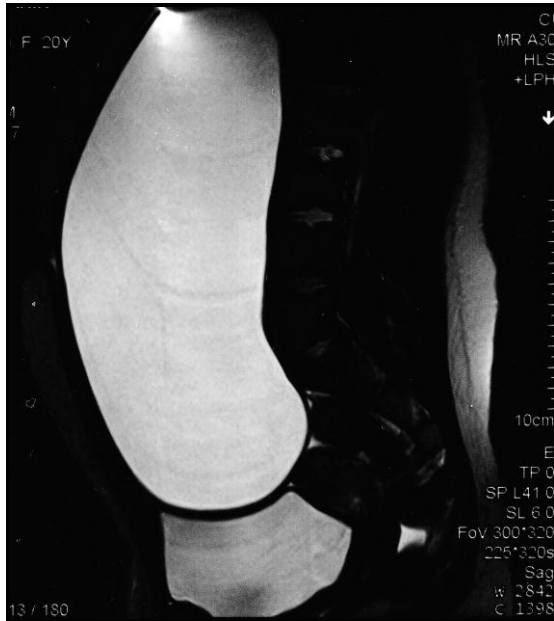DOI: 10.5455/GMJ-30-2011-42  
www.gantep.edu.tr/~tipdergi  
ISSN 1300-0888

Under telescopic vision, we created a supra-pubic 2.5 cm long incision and pulled the shrunken cyst out of the

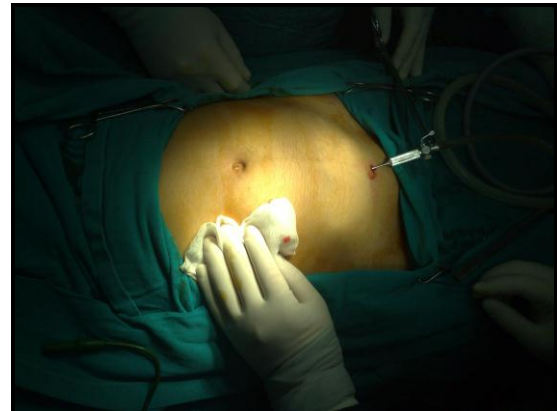abdominal cavity. We extirpated the cyst capsule as in open laparotomy (Figures 4-5).



**Figure 1.** Right ovarian cyst filling the whole abdominal cavity.

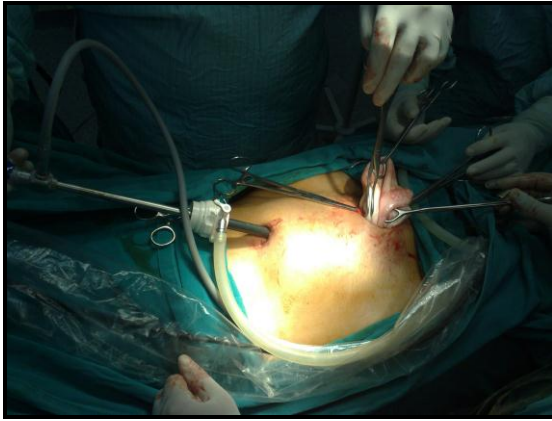


**Figure 2.** Magnetic resonance image of the cyst in sagittal section.



**Figure 3.** Insertion site of the Verres Needle connected to the aspirating device.

Pin-point coagulation was sufficient for haemostasis. The edges of the ovary tissue were approximated by four simple sutures and the right ovary was placed into its original site. The patient was discharged on the second day after the operation without any complications. The pathological diagnosis of mucinous cystadenoma confirmed the benign nature of the cyst.



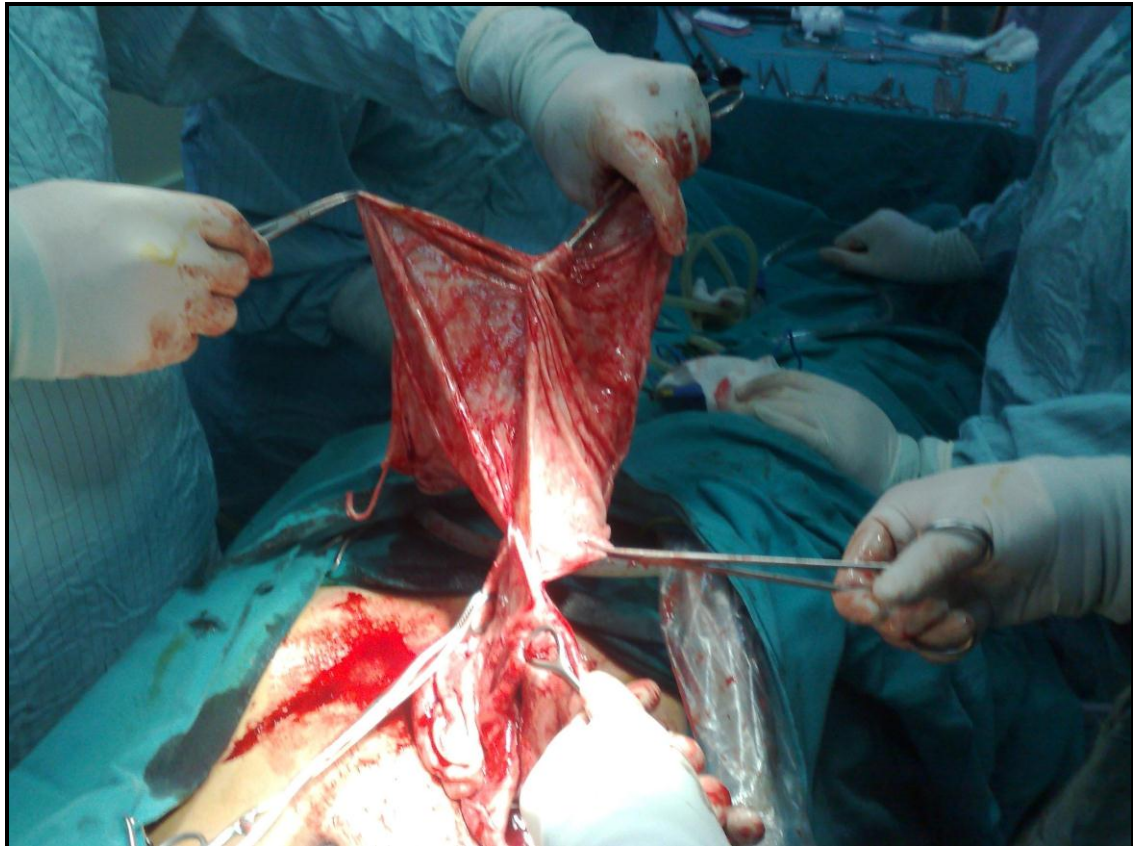
**Figure 4.** Under telescopic view taking out the cyst and the right adnexa.

#### **Discussion**

Minimally invasive surgery has many advantages compared to laparotomy. Aesthetic superiority, less blood loss during surgery, reduced hospital stay and shorter recovery time are well known advantages. However, the difficulty in tissue removal and the risk of the spillage of the malignant tissue narrow the borders of its use. Therefore, ovarian masses cystic or solid are

generally managed by a laparotomy including a full vertical midline incision (4-6), and the following procedure is generally a cystectomy and/or an oophorectomy.

Younger and nulliparous patients are more sensitive on cosmetic and fertility preserving quality of the surgery. They occasionally satisfy with the results of a full midline vertical laparotomy and oophorectomy. In this point of view, a fertility preserving minimal access technique may improve the postoperative patient satisfaction (7). However, many surgeons hesitate about the inadequate cure rates of minimally invasive surgery compared to laparotomy. This fact led many researchers to different adjunct techniques to improve the surgical outcomes of the minimally invasive surgery. Ultrasound-guided cyst aspiration, pre- or intra-operative cyst aspiration using a needle or a supra-pubic catheter, drainage and aspiration of a cyst in an endo-bag, drainage through the vagina following hysterectomy or through a posterior colpotomy are such techniques aiming to improve the surgical outcomes (8-15). Natural orifice trans-luminal endoscopic surgery (NOTES) and single-incision laparoscopic surgery (SILS) have been introduced to further reduce the postoperative pain and visible external scars (16).



**Figure 5.** Extirpation of the cyst capsule.

In our case, our patient was young and nulliparous. She cared for both for the aesthetic and fertility results of the surgery. The preoperative benign findings and the patient's insistent desire to preserve both the cosmesis and the fertility made us to prefer a technique which cared the cosmesis and the fertility. Umbilical trocar entry site and the 2.5 cm supra-pubic incision were the only sites that may interfere with the cosmetic solicitude. By taking the shrunken cyst outside the abdominal cavity, it could be possible to remove the cyst wall completely without damaging the ovarian tissue. Moreover, complete and satisfactory haemostasis could be managed easily by pin point coagulation. In laparoscopic cystectomy haemostasis and complete removal of the cyst wall can be more difficult and because of the difficulty drying the bleeding tissue, generally more than required tissue is coagulated resulting more functional tissue lost from the ovary. SILS and NOTES depend on the laparoscopic experience of the surgeons and these techniques require advanced operative instruments which are different from the conventional laparoscopic instruments. In addition, tissue retrieval or complete extirpation of the cyst wall is still very difficult in these techniques, particularly if the surgeons are operating a huge mass, as in our case.

In order to prevent the spill of probable cancer cells different approaches were described (17). We preferred to begin aspiration before the very gentle insertion of the Verres needle to avoid rupture and spill of the liquid.

In conclusion; benign natured giant ovarian cysts can be managed by laparoscopy-assisted mini-laparotomy with invasiveness comparable to the laparoscopic cystectomy. In terms of haemostasis and fertility preservation, laparoscopy-assisted mini-laparotomy is likely to be superior to laparoscopic cystectomy.

#### References

1. Eltabbakh GH. Laparoscopic management of ovarian cysts. *Contemporary Ob/Gyn* 2003;48:37-50.

2. DiSaia PJ, Creasman WT. The adnexal mass and early ovarian cancer. In: DiSaia PJ, Creasman WT, eds. *Clinical Gynecologic Oncology*. St. Louis, Missouri: Mosby Press; 1997:253-79.
3. Dolan MS, Boulanger SC, Salameh JR. Laparoscopic management of giant ovarian cyst. *JLS* 2006;10(2):254-6.
4. Kazem Moslemi M, Yazdani Z. A huge ovarian cyst in a middle-aged Iranian female. *Case Rep Oncol* 2010;3(2):165-70.
5. Sujatha VV, Babu SC. Giant ovarian serous cystadenoma in a postmenopausal woman: a case report. *Cases J* 2009;2:7875.
6. Mulayim B, Gurakan H, Dagli V, Mulayim S, Aydin O, Akkaya H. Unaware of a giant serous cyst adenoma: a case report. *Arch Gynecol Obstet* 2006;273(6):381-3.
7. Leng JH, Lang JH, Zhang JJ, Feng FZ, Liu ZF, Sun DW et al. Role of laparoscopy in the diagnosis and treatment of adnexal masses. *Chin Med J* 2006;119(3):202-6.
8. Kornblith AB, Huang HQ, Walker JL, Spirtos NM, Rotmensh J, Cella D. Quality of life of patients with endometrial cancer undergoing laparoscopic international federation of gynecology and obstetrics staging compared with laparotomy: a Gynecologic Oncology Group study. *J Clin Oncol* 2009;27(32):5337-42.
9. Mecke H, Savvas V. Laparoscopic surgery of dermoid cysts-intraoperative spillage and complications. *Eur J Obstet Gynecol Reprod Biol* 2001;96(1):80-4.
10. Ma KK, Tsui PZY, Wong WC, Kun KY, Lo LSF, Ng TK. Laparoscopic management of large ovarian cysts: more than cosmetic considerations. *Hong Kong Med J* 2004;10(2):139-41.
11. Ceyhan T, Atay V, Gungor S, Karateke A, Oral O, Baser I. Efficacy of laparoscopically-assisted extracorporeal cystectomy in patients with ovarian endometrioma. *J Minim Invasive Gynecol* 2006;13(2):145-9.
12. Vecchio R, Leanza V, Genovese F, Accardi M, Gelardi V, Intagliata E. Conservative laparoscopic treatment of a benign giant ovarian cyst in a young woman. *J Laparoendosc Adv Surg Tech A* 2009;19(5):647-8.
13. Gocmen A, Atak T, Ucar M, Sanlikal F. Laparoscopy-assisted cystectomy for large adnexal cysts. *Arch Gynecol Obstet* 2009;279(1):17-22.
14. Coccia ME, Rizzello F, Bracco GL, Scarselli G. Seven-liter ovarian cyst in an adolescent treated by minimal access surgery: laparoscopy and open cystectomy *J Pediatr Surg* 2009;44(6):E5-8.
15. Ateş O, Karakaya E, Hakgüder G, Olguner M, Seçil M, Akgür FM. Laparoscopic excision of a giant ovarian cyst after ultrasound-guided drainage. *J Pediatr Surg* 2006;41(10):E9-11.
16. Cuschieri A. Single-incision laparoscopic surgery. *J Minim Access Surg* 2011;7(1):3-5.
17. Pelosi MA II, Pelosi MA III. A novel minilaparotomy approach for large ovarian cysts. *OBG Management* 2004;16(2):17-30.