

Massive subarachnoid hemorrhage after radiofrequency trigeminal rhizotomy

Trigeminal radyofrekans rizotomi sonrası yaygın subaraknoid kanama

Ahmet Mete¹, Lütfiye Pirbudak Çöçelli², Selim Kervancıoğlu¹, Metin Bayram¹

¹University of Gaziantep, Faculty of Medicine, Department of Radiology, Gaziantep

²University of Gaziantep, Faculty of Medicine, Department of Anesthesiology, Gaziantep

Abstract

A 40-year-old man developed massive subarachnoid hemorrhage following attempted radiofrequency ablation for trigeminal neuralgia. The patient had a 10-year history of trigeminal neuralgia at the ophthalmic and maxillary branches of the left trigeminal nerve. After the procedure, the patient's pain resolved completely, but one hour later sudden onset of severe headache in the frontal region was appeared. Computed tomography (CT) scan of the cranium showed massive subarachnoid hemorrhage, and an air bubble was observed in the left cavernous sinus. Herein, we present the CT feature of this rare complication.

Keywords: Radiofrequency ablation; subarachnoid hemorrhage; traumatic; trigeminal neuralgia

Özet

Kırk yaşındaki erkek hastada trigeminal radyofrekans rizotomi sonrası yaygın subaraknoid kanama gelişti. Hastada yaklaşık 10 yıldır süren, trigeminal sinir oftalmik ve maksiller dallarına uyar traselerde ağrı şikayeti vardı. İşlem sonrası hastanın ağrısı tamamen geçti ancak 1 saat sonra frontal bölgede şiddetli baş ağrısı oldu. Kraniyal bilgisayarlı tomografisinde yaygın subaraknoid kanama ve sol kavernöz sinüste hava dansitesi saptandı. Burada bu nadir komplikasyonun bilgisayarlı tomografi bulgularını sunmayı amaçladık.

Anahtar kelimeler: Radyofrekans ablasyon; subaraknoid kanama; travmatik; trigeminal nevralsi

Introduction

Radiofrequency trigeminal rhizotomy (RF-TR) is now a frequently used treatment for medically refractory trigeminal neuralgia (TN) (1,2). This case report presents a rare but an iatrogenic complication of RF-TR for the refractory pain due to trigeminal neuralgia.

Case Report

A 40-year-old man with idiopathic left trigeminal neuralgia involving V2 and V3 dermatomes, refractory to medical treatment, was subjected to RF-TR of the trigeminal ganglion. The patient had a 10-year history of trigeminal neuralgia at the ophthalmic and maxillary branches of the left trigeminal nerve. While the patient's pain was under control with medical treatment, it became remarkably severe in the last 3 days. His preoperative magnetic resonance image (MRI) of brain was normal. Under propofol sedation, foramen ovale was entered at the first attempt. A 10 cm 22-gauge RF cannula with a 10 mm active tip (NeuroTherm™, Medipoint® GmbH, Hamburg, Germany) was employed for the technique. After the patient recovered from sedation the electrode was stimulated, which resulted in paraesthesia around left eye, and then the lesion was inflicted at 80°C for 90 seconds for each division. After the procedure, the patient's pain resolved completely, but one hour later sudden onset of severe headache in the frontal region was appeared. The patient was examined with multislice computed tomography (CT) (Philips Brilliance-6, Netherlands) images using 5 mm of slice thickness with 5 mm interval between slices. CT

scan revealed massive subarachnoidal bleeding in the basal cisterns, bilaterally sylvian fissure and cerebral sulci (Figure 1). CT also confirmed an air bubble (-240 HU) in the left cavernous sinus (Figure 2). An iatrogenic vascular injury resulting in subarachnoid hemorrhage was considered. Cerebral angiography did not show any possible source of active bleeding or vascular abnormality. The patient underwent conservative treatment consisting of administration of corticosteroids and mannitol to control brain edema. His headache relieved, and three days later control CT revealed regression of the signs of bleeding, and on the fifth day the patient was discharged with good pain relief.

Discussion

RF-TR is an effective and commonly performed procedure for control of medically refractory pain due to trigeminal neuralgia. However, RF-TR involves some risks, especially when it is performed by inexperienced clinicians. Complications of RF-TR can be divided into two groups. Firstly, those caused by a thermal lesion occurring within the trigeminal ganglion and the nerve roots and its divisions, and secondly, those caused by misplacement of the needle or mechanical injuries in various anatomic structures. Puncturing of the cavernous sinus (such as in our case), carotid artery, jugular foramen, or foramen magnum and traumatization of the optic, oculomotor, trochlear, or abducens nerves, anesthesia dolorosa, diminished corneal sensations, masseter paresis, transient cranial nerve palsy, CSF leak, carotid cavernous fistula, and isolated injuries to the optic, oculomotor, trochlear, facial and vestibulocochlear nerves have been reported after this procedure (1-4). Entering through the foramen ovale on

İletişim/Correspondence to: Ahmet Mete, University of Gaziantep, Faculty of Medicine, Department of Radiology, Gaziantep, TURKEY.

Tel: +90 342 3606060 / 77339 dr.meteahmet@gmail.com

Received: 06.12.2011 **Accepted:** 01.02.2012

Geliş Tarihi: 06.12.2011 **Kabul Tarihi:** 01.02.2012

DOI: 10.5455/GMJ-30-2012-68

www.gantep.edu.tr/~tipdergi

ISSN 1300-0888

the first attempt is related with more complications, i.e. the tuba auditiva can be punctured easily while penetrating into the foramen ovale, and therefore a

fistula can be seen between Meckel's cave and the auditory tube.

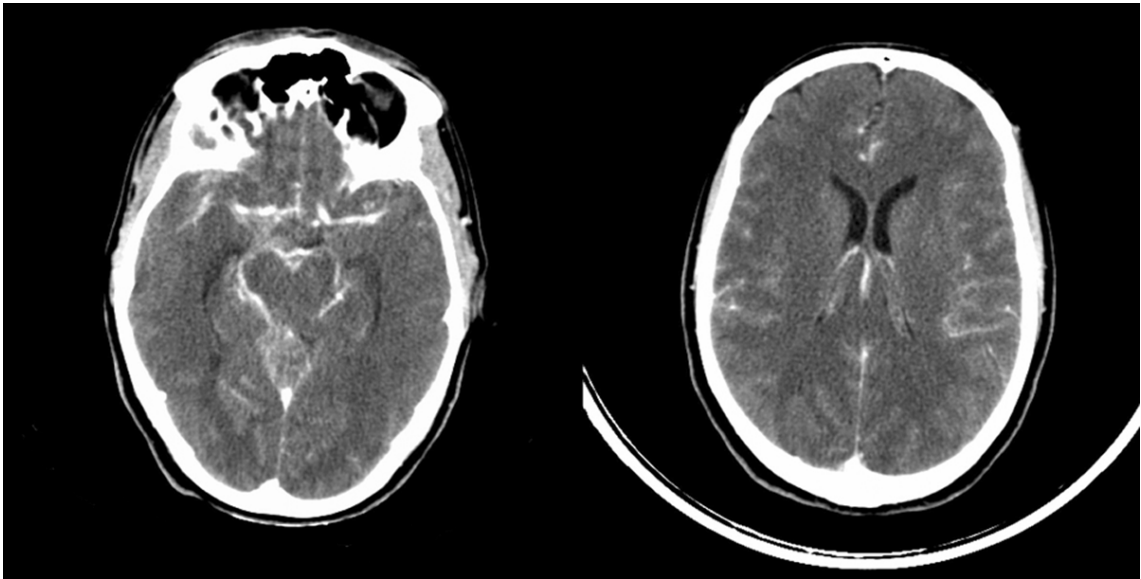


Figure 1. CT scan of the cranium one hour after the attempted RF-TR showing diffuse subarachnoid hemorrhage in the perimesencephalic cisterns and cerebral sulci bilaterally.

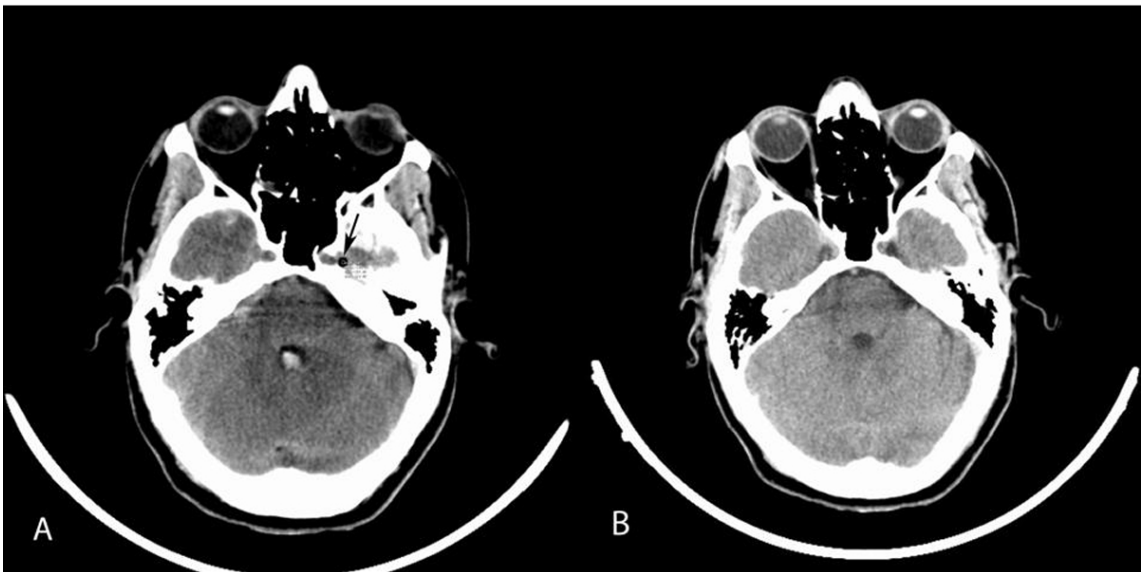


Figure 2. CT scan one hour after the procedure (A) showing an air bubble in the left cavernous sinus (black arrow), and after 3 days on control CT (B) it is gradually absorbed and disappeared.

Our patient had a severe headache one hour after the procedure and the CT scan showed diffuse subarachnoid hemorrhage, and an air bubble in the left cavernous sinus indicating iatrogenic vascular injury. Cavernous sinus puncture seems to be responsible for the subarachnoid hemorrhage. Kanpolat et al. (1) reported 1600 patients subjected to RF ablation for TN, and no vascular injury or subarachnoid hemorrhage was documented. Subarachnoidal bleeding complication was previously defined superior to cerebellopontine cistern, but to our knowledge such a massive subarachnoid

hemorrhage with an air bubble in the left cavernous sinus due to RF-TR procedure was not reported before (5,6).

In conclusion, this case report presents a rare but an iatrogenic complication of RF-TR for the refractory pain due to trigeminal neuralgia. This complication must be kept in mind in cases with severe headache after the procedure, and CT must be performed to rule out or verify subarachnoidal bleeding.

References

1. Kanpolat Y, Savas A, Bekar A, Berk C. Percutaneous controlled radiofrequency trigeminal rhizotomy for the treatment of idiopathic trigeminal neuralgia: 25-year experience with 1600 patients. *Neurosurgery* 2001;48(4):524-32.
2. Kurt E, Atım A. Interventional procedures for the treatment of headache and facial pain. *Turkiye Klinikleri J Ear Nose Throat-Special Topics* 2010;3(3):66-74.
3. Meglio M, Cioni B, Moles A, Visocchi M. Microvascular decompression versus percutaneous procedures for typical trigeminal neuralgia: personal experience. *Stereotact Funct Neurosurg* 1990; 54-55:76-9.
4. Mittal B, Thomas D. Controlled thermocoagulation in trigeminal neuralgia. *J Neurol Neurosurg Psychiatry* 1986;49(8):932-6.
5. Madhusudan Reddy KR, Arivazhagan A, Chandramouli BA, Umamaheswara Rao GS. Multiple cranial nerve palsies following radiofrequency ablation for trigeminal neuralgia. *Br J Neurosurg* 2008;22(6):781-3.
6. Savas A, Sayin M. Subarachnoid bleeding into the superior cerebellopontine cistern after radiofrequency trigeminal rhizotomy: case report. *Acta Neurochir (Wien)* 2010;152(3):561-2.