

# The role of human papillomavirus-16 and matrix metalloproteinase-9 in pathogenesis of uterine cervical neoplasia

Uterus servikal neoplazi patogeneğinde insan papillomavirüs-16 ve matriks metalloproteinaz-9'un rolü

Areej Atiyah Hussein<sup>1</sup>, Hujaz Ismail Abdulrazzaq<sup>2</sup>, Haider Sabah Kadhim<sup>3</sup>

<sup>1</sup>Diyala University, College of Medicine, Diyala

<sup>2</sup>Baghdad University, Al-Kindi College of Medicine, Baghdad

<sup>3</sup>Al-Nahrain University, College of Medicine, Al-Kadhimiya

## Abstract

Uterine cervical neoplasia is a major health problem, and can be a leading cause of death. There is strong evidence that human papillomavirus (HPV) is the principal etiological agent in cervical neoplasia. The objective of this study was to investigate the correlation between HPV-16 and matrix metalloproteinase-9 (MMP-9) and uterine cervical neoplasia. Twenty six formalin fixed, paraffin embedded specimens from patients with uterine cervical neoplasia from teaching laboratories in Baghdad city, were included in this study. In addition fifteen apparently normal cervical tissue blocks have been obtained from patients undergoing hysterectomies for sustained uterine bleeding used as control group. *In situ* hybridization analysis was performed with cDNA probes to HPV-16 and MMP-9. The expression of HPV-16 and MMP-9 in uterine cervical neoplasia cases in the present study was 50% and 61% respectively, but relationship was not found between expression of HPV-16 and MMP-9 and uterine cervical neoplasia. In conclusion, HPV-16 and MMP-9 may have an essential role in progression of uterine cervical neoplasia.

**Keywords:** HPV-16; invasion; matrix metalloproteinases; metastasis; uterine cervical neoplasia

## Özet

Uterus servikal neoplazi bir majör sağlık problemidir ve ölümün başlıca nedeni olabilir. İnsan papilloma virüsünün (HPV) servikal neoplazide başlıca etyolojik ajan olduğuna dair kuvvetli delil vardır. Bu çalışmanın amacı, HPV-16 ve matriks metalloproteinaz-9 (MMP-9) ile uterus servikal neoplazi arasındaki korelasyonu araştırmaktır. Bağdat şehrindeki eğitim laboratuvarlarından uterus servikal neoplazması olan hastalarının formalinde fiske edilen ve parafine gömülü 26 dokusu bu çalışmaya dahil edildi. Buna ek olarak, sürekli uterus kanaması için histerektomi yapılan hastalardan elde edilen 15 adet görünüşte normal servikal doku blokları kontrol grubu olarak kullanıldı. *In situ* hibridizasyon analizi, HPV-16 ve MMP-9 cDNA problemleri ile gerçekleştirildi. Bu çalışmada uterus servikal neoplazma hastalarında HPV-16 ve MMP-9 ekspresyonları sırasıyla %50 ve %61 idi, fakat HPV-16 ve MMP-9 ekspresyonları ile uterus servikal neoplazma arasında ilişki bulunmadı. Sonuç olarak, HPV-16 ve MMP-9 uterus servikal neoplazma gelişiminde önemli role sahip olabilir.

**Anahtar kelimeler:** HPV-16; invazyon; matriks metalloproteinazlar; metastaz; uterus servikal neoplazi

## Introduction

Cervical cancer is the second most common form of malignancy among women worldwide (1). Many agents including radiation, chemicals and viruses, have been found to induce human cancer (2). Viruses are the most important classes for the development of several human cancers including two great worldwide significant, the liver cancer and cervical cancer (3).

Human papilloma viruses (HPVs) are DNA viruses that have specific tropism for squamous epithelial (4). More than 100 types of HPVs have been reported, which are classified as low-risk and high-risk types according to their associations with malignant tumors. High-risk HPVs encode two oncogenes, E6 and E7 which play important roles in carcinogenesis. Early 6 has two zinc finger domains and interacts with tumor suppressor p53 and degrades it to escape from apoptosis and to disrupt cell cycle checkpoint machinery (5).

The invasive behavior of neoplastic cells and their

ability to metastasize to distant sites are multistep processes that include detachment of the cells from the original tumor mass, attachment to extracellular matrix (ECM) binding sites, degradation of ECM and migration into surrounding tissues. One of the rate-limiting steps in the metastasis cascade is the activity of MMPs degrading a variety of ECM protein (6). Particularly MMP-2 and MMP-9 are thought to play a central role in these processes (7). In general, the role of MMPs in carcinogenesis seems to be very complex sometimes even controversial, according to some preclinical findings (8). Several studies have reported that especially MMP-2 and MMP-9 are up-regulated in cervical neoplasias, and suggested a correlation between increased MMP-2 and MMP-9 expression and poor prognosis (9).

So this study aims to detect HPV-16 and MMP-9 using *in situ* hybridization in uterine cervical neoplasia, and study the correlation between HPV-16 and MMP-9 expression with age of patients and differentiation during uterine cervical neoplasia progression.

**İletişim/Correspondence to:** Haider Sabah Kadhim, College of Medicine, Al-Nahrain University, P.O. Box 70056, IRAQ  
Tel: 964 770 5336906 [haider\\_kadhim@yahoo.com](mailto:haider_kadhim@yahoo.com)

**Received:** 29.01.2012 **Accepted:** 26.03.2012  
**Geliş Tarihi:** 29.01.2012 **Kabul Tarihi:** 26.03.2012

DOI: 10.5455/GMJ-30-2012-82  
[www.gantep.edu.tr/~tipdergi](http://www.gantep.edu.tr/~tipdergi)  
ISSN 1300-0888

**Material and Methods**

*Patients and tissue samples*

Twenty six patients with cervical intraepithelial neoplasia with an age ranged from 25 to 70 years, were included in this retrospective study. The patients' samples were collected from the archives of histopathology laboratories of teaching laboratories in Baghdad city from 2003 until 2010. The diagnosis of these tissue blocks were primarily based on the obtained histopathological records of cervix biopsy samples that had accompanied in the hospital laboratory. Confirmatory histopathological re-evaluation of each obtained tissue blocks was done by specialist pathologist. In addition, fifteen apparently normal cervical blocks without any significant pathological changes have been obtained from patients sustained hysterectomies for uterine bleeding used as control group.

Formalin-fixed, paraffin embedded blocks tissue were sectioned (4 µm) thickness, from each tissue block, one section was stained with hematoxylin and eosin, 2 sections were mounted on charged slides to be used for *in situ* hybridization, detecting of HPV-16 and MMP-9.

*In situ hybridization procedure for HPV-16*

The slides were placed in oven at 60°C over night to deparaffinized tissue sections. The slides were dehydrated by graded alcohol concentration (100%, 95%, and 70%) and distilled water then treated with proteinase K solution and dehydrated. One drop of the biotinylated long cDNA probe for HPV-16 (Maxim Biotech Cat. No. IH-60058). Hybridization/detection kit were purchased from Maxim Biotech (USA Cat. No. IH-6001, IHD-0050). Biotinylated probe was placed on the tissue section in oven at 95°C for 8-10 min to denature the double strands of DNA. The slides were then placed in a humid chamber and incubated over night at 37°C to allow hybridization of the probe with the target nucleic acid. The slides were soaked in protein block at 37°C until the cover slips fall, and then treated with streptavidin-alkaline phosphatase-conjugate. One to two drops of bromo-chloro-indolyl phosphate/nitro blue tetrazolium substrate-chromogen solution (BCIP/NBT) were placed on tissue section at room temperature for about 30 minutes, the latter was monitored by viewing the slides under the microscope. A blue colored precipitate will form at the site of the probe in positive cells. Slides were then counterstained using nuclear fast red and sections were mounted with a permanent

mounting medium (DPX). Finally the examination was performed under light microscope by a pathologist at power 400.

*In situ hybridization procedure for MMP-9*

The slides were placed in 60°C hot-air oven over night. The tissue sections were deparaffinized by standard methods. The slides were treated with proteinase K solution and dehydrated. One drop of the biotinylated long cDNA probe for human MMP-9 (Maxim Biotech, Cat. No. IH-60028). Hybridization solution was placed on the tissue section in oven at 70°C for 8-10 min. After that slide were placed in a humid chamber and incubated over night at 37°C to allow hybridization of the probe with the target nucleic acid. The slides were soaked in 1x detergent wash at 37°C until the cover slips fall, and then treated with RNase and conjugate. One to two drops of substrate were placed on tissue section at room temperature for about 30 min, then monitored by viewing the slides under the microscope. A blue colored precipitate will form at the site of the probe in positive cells. Slides were then counterstained using nuclear fast red and sections were mounted with DPX. Finally the examination was done under light microscope by a pathologist at power 400.

Data analysis was performed using Chi-Square test and Fisher's exact test which was used to find out the effect of different patients criteria. Values were considered statistically significant when p<0.05.

**Results**

*Histopathological classification*

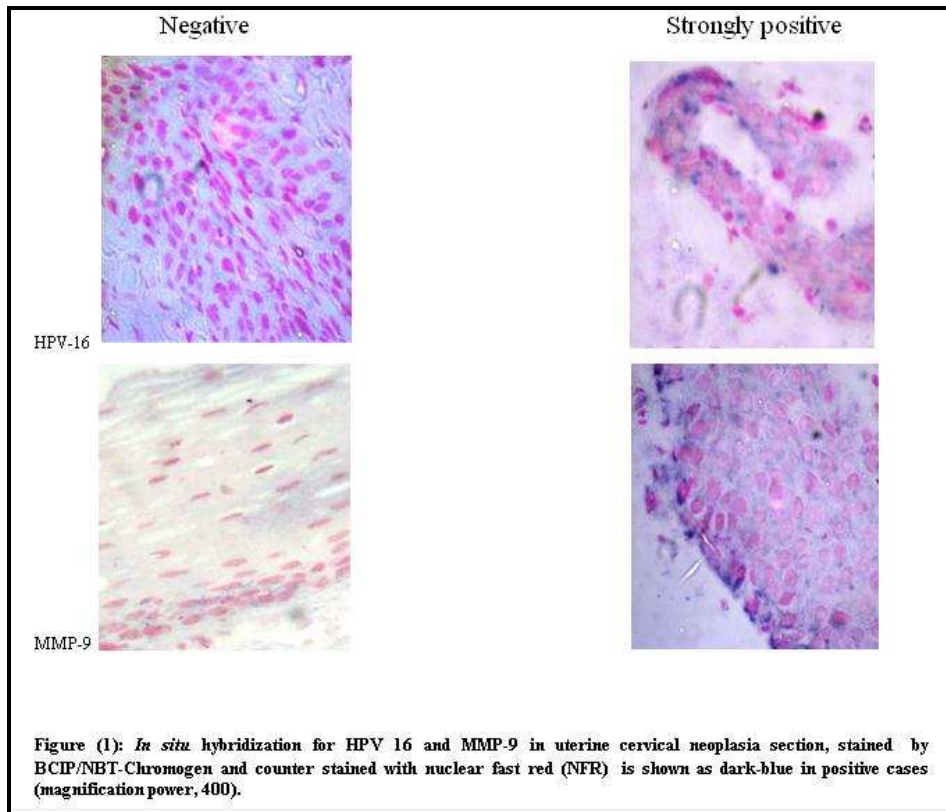
The specimens of uterine cervical neoplasia were graded according to Robbins and Cotran Classification (10) as well as differentiated uterine cervical neoplasia (n=3; 11.53%), moderately differentiated uterine cervical neoplasia (n=21; 80.76%) and poorly differentiated uterine cervical neoplasia (n=3; 11.53%).

*Results of in situ hybridization detection of HPV-16 and MMP-9*

The results showed in Table 1 and Figure 1 which were demonstrated that 13 cases (50%) of uterine cervical neoplasia were positive for HPV-16, while 16 cases (61.5%) were positive for MMP-9. On the other hand statistical analysis were demonstrated highly significant differences in HPV-16 and MMP-9 expression among patients with uterine cervical neoplasia when compared with healthy control group.

**Table 1.** The percentage of HPV-16 and MMP-9 *in situ* hybridization-detection tests in the studied groups.

	<i>In situ</i> hybridization reaction results	Studied groups		Comparison of Significance	
		Uterine cervical neoplasia (n %)	Healthy control (n %)	p value	Significance
HPV-16	Positive	13 (50%)	0	0.001	Highly significant
	Negative	13 (50%)	15		
	Total	26 (100%)	15 (100%)		
MMP-9	Positive	16 (61%)	0	0.001	Highly significant
	Negative	10 (38%)	15		
	Total	26 (100%)	15 (100%)		



Tables 2 and 3 demonstrated the correlation between expression of HPV-16 and MMP-9 with age of patients and differentiation. The results showed that there were no significant differences between in situ hybridization expression of HPV-16 and MMP-9 with age and

differentiation based on Chi-square test of analysis and Fisher's exact test.

**Table 2.** *In situ* hybridization expression of HPV-16 as related to age of patients and differentiation.

	Variables	HPV-16	HPV-16	Comparison of Significance	
		positive	negative	p-value	Significance
Age	25-39	3 (75.0%)	1 (25.0%)	0.13	Not Significant (P>0.05)
	40-54	10 (52.6%)	9 (47.4%)		
	55-70	0	3 (100.0%)		
Differentiation	Well differentiated	2 (66.7%)	1 (33.3%)	0.82	Not Significant (P>0.05)
	Moderately differentiated	10 (47.6%)	11 (52.4%)		
	Poorly differentiated	1 (50.0%)	1 (50.0%)		

**Table 3.** *In situ* hybridization expression of MMP-9 as related to age of patients and differentiation.

	Variables	MMP-9	MMP-9	Comparison of Significance	
		positive	negative	p-value	Significance
Age	25-39	2 (50.0%)	2 (50.0%)	0.44	Not Significant (P>0.05)
	40-54	13 (68.4%)	6 (31.6%)		
	55-70	1 (33.3%)	2 (66.7%)		
Differentiation	Well differentiated	1 (33.3%)	2 (60.7%)	0.32	Not Significant (P>0.05)
	Moderately differentiated	13 (61.9%)	8 (38.1%)		
	Poorly differentiated	2 (100.0%)	0		

**Discussion**

HPV-16 is the predominant virus type identified in cervical cancer and codes three transforming oncogenes E5, E6, and E7. Cervical cancer cells expressing the HPV-16 genome are able to contribute to the

proangiogenic response that might support tumor growth and invasion into the surrounding tissues (11). It is found up to 90% of HPV-positive cases (12).

The results demonstrated that HPV-16 was observed in 50% of patients with uterine cervical neoplasia as shown in (Table 1 and Figure 1). This result was in agreement with the finding of Bhattarakosol et al. (13) which detected the HPV-16 genome in 42.68% of tissue samples using PCR and dot hybridization technique (13,14).

In this study higher percentage of the HPV-16 positive tumors occurred in age group 40-54 years and there were no significant differences between HPV-16 and age of patients. Previous researcher has found intraepithelial lesions that frequently occur in the younger women often under 40 years of age and cervical cancer that tends to affect women, usually in the fifth or sixth decade at a mean age of 54 years (15,16).

Regarding comparison of HPV-16 DNA expression results according to grade of patient with uterine cervical neoplasia revealed that there was no significant correlation among them. These results were comparable to these of Khashman (17) who reported that moderately differentiated were the most common type of grade in patients with positive HPV.

The current study had demonstrated that MMP-9 was over expressed in as shown in uterine cervical neoplasia (Table 1 and Figure 1). These results might possibly reflect the association between cellular expression of MMP-9 and cervical tumorigenesis.

Concerning MMP-9 expression, positivity did not correlate to the age of the patients and grade of the tumor (Table 3). This result was in agreement with the findings of Ozdemir et al. (18) who pointed out that there was no correlation between MMP-9 over expression age and tumor grade was recorded.

Regarding expression of MMP-9 in relation with HPV-16, the current study did not found relationship between MMP-9 expression and HPV-16 genome. This result was in agreement with findings of Behren et al. (9) who reported that papillomavirus E2 protein induces expression of the MMP-9 via the extracellular signal-regulated kinase/activator protein-1 signaling pathway (9). MMP-9 could be involved in the cervical neoplasias (19,20). Indeed, previous experiments with mice transgenic for HPV-16 and additionally devoid of MMP-9 showed only a reduction of 50% in squamous cell carcinoma incidence in comparison with HPV-16/MMP-9-proficient mice (21).

The transcription of the MMP-9 and MMP-2 genes are, however, differently controlled. Whereas the promoter of MMP-9 contains cis-elements (activator protein-1 and nuclear factor- $\kappa$ B) that can be regulated through mitogen-activated protein kinases (MAPK) (22). The MAPKs are a family of enzymes that transduce signals via several phosphorylation steps into the nucleus (23). The three best characterized members of the MAPK are the stress-activated c-Jun NH<sub>2</sub>-terminal kinase, the p38 kinase, and the extracellular signal-regulated kinase (ERK). Growth factors lead to an activation of ERK by

upstream regulator proteins, such as Raf, which itself can be activated by Ras, a key mediator of cell proliferation (24). Therefore, activation of ERK and entry into the nucleus can often be found in cancer and has been linked to cervical and other epithelial neoplasia (25). Katori et al. (7) reported that on patients with inverted papilloma found significant increase of MMP-2 and MMP-9 with HPV, HPV-16/18 positive inverted papilloma compared to HPV16/18 negative inverted papilloma (7). According to the results of Iraqi cancer registration of period 1999-2004, the incidence was 1.04% for cervical cancer (26).

We attempted to identify MMP-9 expression and HPV-16 genome in uterine cervical neoplasia, significant increase of MMP-9 and HPV-16 were observed in patients. However, the HPV genome alone is not sufficient for cancer formation, cervical carcinogenesis is considered as a multistep process accompanied by genetic alteration.

### References

1. Pahler JC, Tazzyman S, Erez N, Chen YY, Murdoch C, Nozawa H, et al. Plasticity in tumor-promoting inflammation: impairment of macrophage recruitment evokes a compensatory neutrophil response. *Neoplasia* 2008;10(4):329-40.
2. De villiers EM. Relationship between steroid hormone contraceptives and HPV, cervical intraepithelial neoplasia and cervical carcinoma. *Int J Cancer* 2003;103(6):705-8.
3. Brooks GF, Carroll KC, Butel JS, Morse SA, Mietzner TA. Jawetz, Melnick, and Adelberg's Medical Microbiology 24nd Ed., The McGraw-Hill Companies, Inc. 2007.
4. Muñoz N, Bosch FX, de Sanjosé S, Herrero R, Castellsagué X, Shah KV, et al. Epidemiologic classification of human papillomavirus types associated with cervical cancer. *N Engl J Med* 2003;348(6):518-27.
5. Yoshida S, Kajitani N, Satsuka A, Nakamura H, Sakai H. Ras modifies proliferation and invasiveness of cells expressing human papillomavirus oncoproteins. *J Virol* 2008;82(17): 8820-7.
6. Elkin M, Reich R, Nagler A, Aingorn E, Pines M, de-Groot N, et al. Inhibition of matrix metalloproteinase-2 expression and bladder carcinoma metastasis by halofuginone. *Clin Cancer Res* 1999;5(8):1982-8.
7. Katori H, Nozawa A, Tsukuda M. Increased expression of matrix metalloproteinase-2 and 9 and human papilloma virus infection are associated with malignant transformation of sinonasal inverted papilloma. *J Surg Oncol* 2006;93(1):80-5.
8. Deryugina EI, Quigley JP. Matrix metalloproteinases and tumor metastasis. *Cancer Metastasis Rev* 2006;25(1):9-34.
9. Behren A, Simon C, Schwab RM, Loetzsch E, Brodbeck S, Huber E. Papillomavirus E2 protein induces expression of the matrix metalloproteinase-9 via the extracellular signal-regulated kinase/activator protein-1 signaling pathway. *Cancer Res* 2005;65(24):11613-21.
10. Kumar V, Abbas AK, Fausto N. Robbins and Cotran Pathologic Basis of Disease, 7th edition, W.B. Saunders Company, 2004.
11. Song SH, Lee JK, Hur JY, Kim I, Saw HS, Park YK. The expression of epidermal growth factor receptor, vascular endothelial growth factor, matrix metalloproteinase-2, and cyclooxygenase-2 in relation to human papilloma viral load and persistence of human papillomavirus after conization with negative margins. *Int J Gynecol Cancer* 2006;16(6):2009-17.
12. Weinberger PM, Yu Z, Haffty BG, Kowalski D, Harigopal M, Brandsma J, et al. Molecular classification identifies a subset of human papillomavirus-associated oropharyngeal cancers with favorable prognosis. *J Clin Oncol* 2006;24(5):736-47.
13. Bhattarakosol P, Poonnaniti A, Niruthisard S. Detection and typing of human papillomavirus in cervical cancer in the Thai. *J Med Assoc Thai* 1996;79(Suppl 1):S56-64.

14. Kjaer SK, van den Brule AJ, Paull G, Svare EI, Sherman ME, Thomsen BL, et al. Type specific persistence of high risk human papillomavirus (HPV) as indicator of high grade cervical squamous intraepithelial lesions in young women: population based prospective follow up study. *BMJ* 2002;325(7364):572.
15. Cannistra AS, Niloff JM. Cancer of the uterine cervix. *N Engl J Med* 1996;334(16):1030-8.
16. Koyama T, Tamai K, Togashi K. Staging of carcinoma of the uterine cervix and endometrium. *Eur Radiol* 2007;17(8):2009-19.
17. Khashman BM. Molecular and virological study on human papilloma virus infection in Iraqi patients with oral squamous cell carcinoma. M.Sc. Thesis, College of Medicine, Baghdad University, Iraq, 2008.
18. Özdemir E, Kakehi Y, Okuno H, Yoshida O. Role of matrix metalloproteinase-9 in the basement membrane destruction of superficial urothelial carcinomas. *J Urol* 1999;161(4):1359-63.
19. Davidson B, Goldberg I, Kopolovic J, Lerner-Geva L, Gotlieb WH, Weis B, et al. Expression of matrix metalloproteinase-9 in squamous cell carcinoma of the uterine cervix-clinicopathologic study using immunohistochemistry and mRNA in situ hybridization. *Gynecol Oncol* 1999;72(3):380-6.
20. Nuovo GJ, MacConnell PB, Sinsir A, Valea F, French DL. Correlation of the in situ detection of polymerase chain reaction-amplified metalloproteinase complementary DNAs and their inhibitors with prognosis in cervical carcinoma. *Cancer Res* 1995;55(2):267-75.
21. Van Kempen LC, Rhee JS, Dehne K, Lee J, Edwards DR, Coussens LM. Epithelial carcinogenesis: dynamic interplay between neoplastic cells and their microenvironment. *Differentiation* 2002;70(9-10):610-23.
22. Simon C, Simon M, Vucelic G, Hicks MJ, Plinkert PK, Koitschev A, et al. The p38 SAPK pathway regulates the expression of the MMP-9 collagenase via AP-1-dependent promoter activation. *Exp Cell Res* 2001;271(2):344-55.
23. Edmunds JW, Mahadevan LC. MAP kinases as structural adaptors and enzymatic activators in transcription complexes. *J Cell Sci* 2004;117(Pt 17):3715-23.
24. Roux PP, Blenis J. ERK and p38 MAPK-activated protein kinases: a family of protein kinases with diverse biological functions. *Microbiol Mol Biol Rev* 2004;68(2):320-44.
25. Branca M, Ciotti M, Santini D, Bonito LD, Benedetto A, Giorgi C, et al. Activation of the ERK/MAP kinase pathway in cervical intraepithelial neoplasia is related to grade of the lesion but not to high-risk human papillomavirus, virus clearance, or prognosis in cervical cancer. *Am J Clin Pathol* 2004;122(6): 902-11.
26. Iraq Cancer Board, Results of Iraqi Cancer Registry (1999-2004), Ministry of Health, Iraq Cancer Registry Centre, Baghdad - Iraq, 2008.