

Famotidine-induced acquired long QT syndrome: a case report

Famotidinin uyardığı uzun QT sendromu: olgu sunumu

Ebru Tekbaş¹, Zuhale Arıtürk¹, Habib Çil¹, Yahya İslamoğlu¹

¹Dicle University, Faculty of Medicine, Department of Cardiology, Diyarbakır

Abstract

It is known that a number of drugs caused acquired long QT syndrome. Although the often use of famotidine, acquired long QT syndrome associated with this drug has rarely been reported. We presented a case of famotidine associated with acquired long QT syndrome.

Keywords: Electrocardiography; famotidine; gastritis; long QT

Özet

Bir çok ilacın uzun QT sendromuna yol açtığı bilinmektedir. Famotidinin sık kullanımına rağmen bu ilacın neden olduğu uzun QT sendromu nadiren bildirilmiştir. Biz famotidinle ilişkili kazanılmış uzun QT sendromlu bir olgu sunduk.

Anahtar kelimeler: Elektrokardiyografi; famotidin; gastritis; uzun QT

Introduction

The upper limit for duration of the normal QT interval corrected for heart rate (QTc) is frequently given as 440 ms in men and as 460 ms in women (1). Prolonged QT interval is important because it may cause to polymorphic ventricular tachycardia known as torsades de pointes. QT interval prolongation may be either congenital or acquired. It is known that a number of drugs caused acquired long QT syndrome (1). Famotidine is a highly selective histamine H₂ receptor antagonist and it is commonly used for the treatment of peptic ulcer and gastro esophageal reflux disease. Herein we report famotidine associated with acquired long QT syndrome.

Case Report

A 59-year-old woman was admitted to our hospital with unstable angina pectoris. Past medical history included hypertension. She had been using silazapril for hypertension. Also she had been using famotidine for gastritis for two months. Her ECG revealed that T-wave inversion at all derivation except aVR and V1 and QTc was slightly longer. It was calculated as 464 ms. Physical examination on admission revealed blood pressure 150/70 mmHg, pulse 80 beat/min. Cardiac and lung auscultation were normal. Cardiac enzymes and other routine laboratory tests were within normal range. Transthoracic echocardiography showed mild left ventricular hypertrophy, diastolic dysfunction and mild mitral regurgitation. The patient was treated with aspirin (300 mg/day), clopidogrel (75 mg/day), subcutaneous enoxaparin (0.6 ml twice a day), intravenous nitroglycerin, metoprolol (100 mg/day), silazapril (2.5 mg/day) and intravenous famotidine (20 mg twice a day). Coronary angiography revealed normal coronary artery. Approximately 12 hours after receiving the first

dose famotidine the QTc became markedly prolonged at 624 ms (Figure 1). Serum potassium, magnesium, and calcium levels were normal. Two days after famotidine was stopped, the QTc returned to baseline at 460 ms (Figure 2).

Discussion

Famotidine is a histamine H₂ receptor antagonist and it is commonly used for the treatment of peptic ulcer and gastroesophageal reflux disease. H₂ receptors are present in the heart and coronary circulation, as shown in animal studies, and cardiovascular complications in human beings have been associated with the use of H₂ blockers (2). Acquired long QT syndrome associated with famotidine has rarely been reported (3,4). To the best of our knowledge the reported patient is the seventh case in the English-language literature.

The mechanism of famotidine-induced long QT is not clearly understood. However, ranitidine - the other H₂ receptor antagonist - has been shown to inhibit cholinesterase, which may lead to an increase in the acetylcholine level at the nerve endings. In the end, decreased chronotropy; increased atrioventricular node conduction times and refractory periods; and possibly increased refractory periods and spectral dispersion in ventricular tissue may be responsible for the long QT interval (5). Ranitidine associated bradycardia has been reported in the English-language literature (6), however to the best of our knowledge, ranitidine associated long QT syndrome had not been reported in the literature.

Sugiyama et al. (7) reported that supratherapeutic doses of famotidine had no effect on the I_{Kr} potassium current in human embryonic kidney cells or on action potential of guinea pig papillary muscles, and neither prolonged QT nor induced torsades de pointes in a canine model. To our knowledge, no published reports have evaluated the effects of famotidine on human myocardial

İletişim/Correspondence to: Ebru Tekbaş, Dicle University, Faculty of Medicine, Department of Cardiology, Diyarbakır, TURKEY
Tel: +90 506 359 31 01 dretekbaz@yahoo.com

Received: 20.10.2011 **Accepted:** 12.12.2011
Geliş Tarihi: 20.10.2011 **Kabul Tarihi:** 12.12.2011

DOI: 10.5455/GMJ-30-2011-53
www.gantep.edu.tr/~tipdergi
ISSN 1300-0888

repolarization. Our patient had also slight QT prolongation when she was admitted to hospital. She had used famotidine tablets for gastritis before admission to hospital and marked prolongation of the QT interval occurred during hospitalization and coincided with administration of intravenously famotidine therapy. QT duration became normal after intravenous famotidine was discontinued. None of the other drugs which used by the patient did not lead to QT prolongation. Ischemia may be another cause of prolonged QT duration (8). Our patient presented with typically angina pectoris and common T wave inversion on her ECG. In contrast to these findings, cardiac enzymes were within normal limits and coronary angiography revealed normal

coronary arteries. Lee et al. (4) reported famotidine induced long QT syndrome in two cases, however in these patients, there was multiple co-morbidities such as ischemic heart disease, congestive heart failure, renal failure, amiodarone administration and elderly patient which are listed in risk factor for the long QT syndrome (1,4). Female gender was the only risk factor for the long QT syndrome in our patient. Also, we scored the famotidine-induced long QT adverse effect according to adverse drug probability scale (9), the result was reliable with probable category.

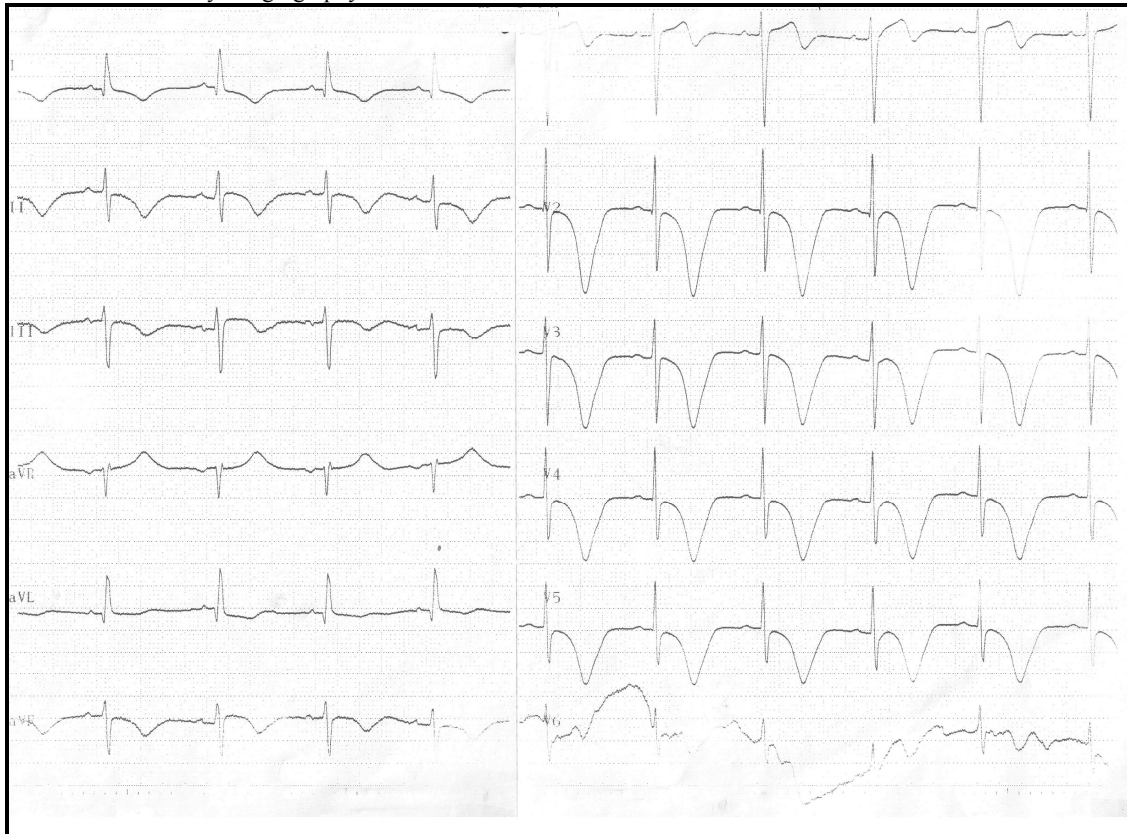

Figure 1. ECG from the patient shows sinus rhythm on i.v. famotidine 20 mg bid, (QTc=624 ms).

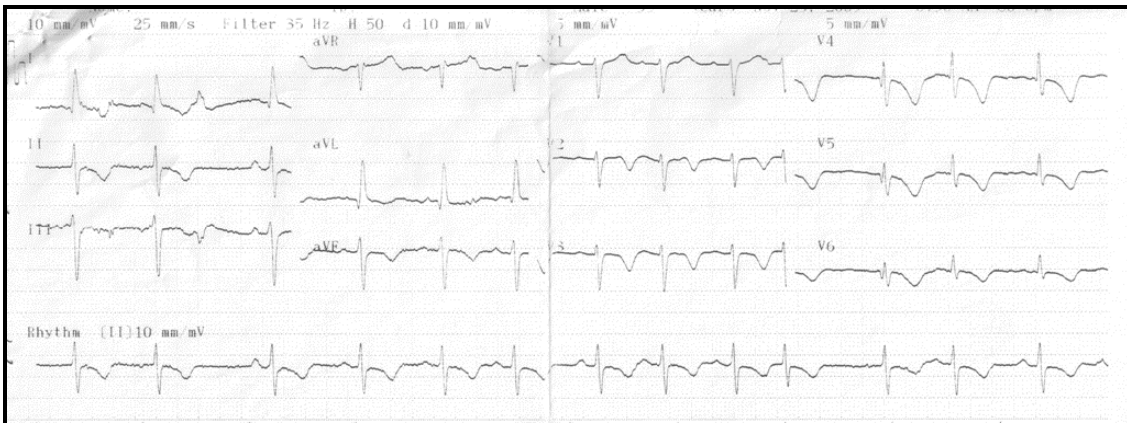


Figure 2. ECG two days after cessation of famotidine (QTc=464 ms).

As a result; if the patients are treated with famotidine, electrocardiogram must routinely be recorded, because of its' potential effect on QT prolongation that may cause serious ventricular arrhythmias known as torsades de pointes.

References

1. Cahoon WD Jr. Acquired QT prolongation. *Prog Cardiovasc Nurs* 2009;24(1):30-3.
2. Hulisz DT, Welko JR, Heiselman DE. Sinus arrest associated with continuous-infusion cimetidine. *Pharmacotherapy* 1993;13(1):64-7.
3. Endo T, Katoh T, Kiuchi K, Katsuta Y, Shimizu S, Takano T. Famotidine and acquired long QT syndrome. *Am J Med* 2000;108(5):438-9.
4. Lee KW, Kayser SR, Hongo RH, Tseng ZH, Scheinman MM. Famotidine and long QT syndrome. *Am J Cardiol* 2004;93(10):1325-7.
5. Gunasekaran TS, DuBrow I. Cisapride-induced long QT interval: what is the role of ranitidine? *J Pediatr* 1997;130(4):679-80.
6. Yang J, Russell DA, Bourdeau JE. Case report: ranitidine-induced bradycardia in a patient with dextrocardia. *Am J Med Sci* 1996;312(3):133-5.
7. Sugiyama A, Satoh Y, Takahara A, Nakamura Y, Shimizu-Sasamata M, Sato S, et al. Famotidine does not induce long QT syndrome: experimental evidence from in vitro and in vivo test systems. *Eur J Pharmacol* 2003;466(1-2):137-46.
8. Kenigsberg DN, Khanal S, Kowalski M, Krishnan SC. Prolongation of the QTc interval is seen uniformly during early transmural ischemia. *J Am Coll Cardiol* 2007;49(12):1299-305.
9. Naranjo CA, Busto U, Sellers EM, Sandor P, Ruiz I, Roberts EA, et al. A method for estimating the probability of adverse drug reactions. *Clin Pharmacol Ther* 1981;30(2):239-45.