

Massive Hepatosplenomegaly due to Uveal Melanoma Metastasis

Uveal Melanom Metastazına Bağlı Masif Hepatosplenomegali

Muhammed Sait Dağ¹, İbrahim Türkbeyler¹, İbrahim Sarı², Seyithan Taycı³,
Abdurrahman Kadayıfçı¹

¹University of Gaziantep, Faculty of Medicine, Department of Gastroenterology, Gaziantep

²University of Gaziantep, Faculty of Medicine, Department of Pathology, Gaziantep

³University of Gaziantep, Faculty of Medicine, Department of Biochemistry, Gaziantep

Abstract

Uveal melanoma is a rare tumor which may cause to liver metastasis. We report a case of uveal melanoma which presents with severe abdominal pain and massive hepatosplenomegaly due to diffuse liver metastasis. The patient had a history of enucleation and ocular prosthesis for left eye more than 1 year. On physical examination the liver was palpable about 10 cm with a smooth and hard surface. The spleen was also palpable. Medical records of patient showed that he had an operation for uveal melanoma previously. Urine melanin was detected at the Thormahlen's test. The liver biopsy confirmed the presence of a metastasis of malignant melanoma. Massive hepatosplenomegaly due to uveal melanoma is a rare clinical entity. The medical history of the patient is very important for suspicion of the underlying pathology.

Keywords: Uveal melanoma; liver metastasis; massive hepatosplenomegaly

Özet

Uveal melanoma karaciğere metastaz yapabilen nadir bir tümördür. Ciddi karın ağrısı ve diffüz karaciğer metastazına bağlı masif hepatosplenomegali ile başvuran bir uveal melanoma olgusunu sunuyoruz. Hastanın öyküsünde bir yılı aşkın süre öncesinde sol gözüne enükleasyon ve göz protezi uygulandığı öğrenildi. Fizik muayenesinde karaciğerin sağ kosta yayını yaklaşık 10 cm aşığı ve yüzeyinin düz ve sert olduğu saptandı. Dalak da sol kosta yayı altında ele gelmekteydi. Önceki tıbbi kayıtları araştırıldığında uveal melanoma için opere olmuş olduğu görüldü. Thormahlen testinde üriner melanin tespit edildi. Karaciğer biyopsisi ile malign melanomun karaciğer metastazı teyit edildi. Uveal melanomaya bağlı masif hepatosplenomegali nadir bir klinik durumdur. Hastanın geçmiş medikal öyküsü bu tip bir patolojiden şüphelenilmesi için çok önemlidir.

Anahtar kelimeler: Uveal melanoma; karaciğer metastazı; masif hepatosplenomegali

Introduction

Uveal melanoma is a rare tumor which arises from the melanocytes that reside within the uvea. It differs from cutaneous melanoma mainly because of its metastasis pattern. Liver metastasis develops in approximately 50 to 70% of patients with recurrent uveal melanoma and patients have a poor prognosis in spite of aggressive treatment modalities (1,2). Clinically proved liver metastasis may occur several years after the detection of primary tumor and patients may admit to internal medicine or surgery clinics with abdominal symptoms and signs. Liver metastasis usually exists as multiple nodular lesions. But diffuse metastasis without any identifiable mass was published as case reports (3). We present a case of uveal melanoma which was presented with severe abdominal pain and massive hepatosplenomegaly due to diffuse liver metastasis.

Case

Thirty-six year old male patient presented with severe and progressive abdominal pain, bloating and significant weight loss in last 4 weeks. Physical examination revealed abdominal tenderness located in hypocondriums without guarding. Liver was 10 cm

palpable with a smooth and hard surface. The spleen was also palpable. The patient had a history of enucleation and ocular prosthesis more than 1 year. But he was aware of the reason for operation. The patient was hospitalized and the medical records were requested from the hospital which enucleation had been done. These records showed he had an operation for uveal melanoma. Laboratory parameters were normal except for AST: 44 U/L (8-38), ALT: 45 U/L (8-40), LDH: 1058 U/L (240-480) and ALP: 270 U/L (60-150). Trans-abdominal ultrasound and CT scans showed diffuse enlargement of liver and spleen without any identifiable mass and lymph node (Figure 1). In portal Doppler ultrasonography and upper endoscopy showed no sign of portal hypertension. Abdominal pain was thought to be related with capsule extension of enlarged liver and spleen. In order to identify recurrent melanoma Thormahlen's test was performed to detect urine melanin. The result of the test was positive and liver biopsy was applied to show a possible liver metastasis (Figure 2). The biopsy sample was totally black at macroscopic examination and histology confirmed the presence of malignant melanoma (Figure 3). After the exact diagnosis of malignant melanoma metastasis patient was referred to medical oncology department and dacarbazine plus cis-platin based chemotherapy was started. On the third month of the treatment patient was died.

Correspondence to/İletişim: Muhammed Sait Dağ, University of Gaziantep, Faculty of Medicine, Department of Gastroenterology, Şahinbey, Gaziantep, TURKEY
Tel: +90 342 3601200/77555 drmsait@windowslive.com

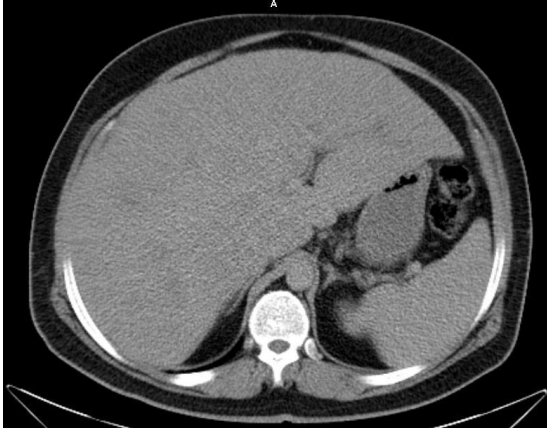


Figure 1. Abdominal computerised tomography scanning showed that diffuse enlarged liver and spleen.



Figure 2. Thormahlen's test determining the abnormal presence of melanin in the urine. It has been seen in the picture that after test urine takes a deep blue color (on left).

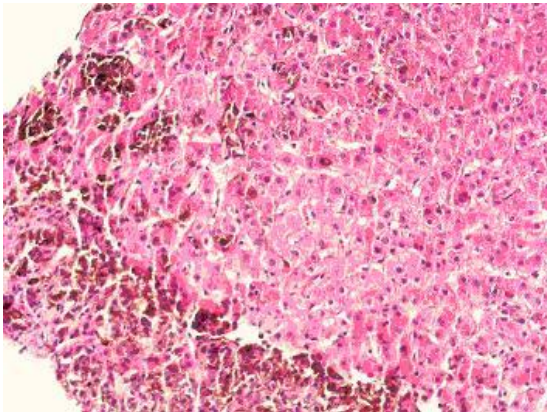


Figure 3. The histopathology of liver showing melanin pigment accumulation.

Discussion

Malignant melanoma is a neoplastic disease of pigment producing cells which are known as melanocytes. It is most commonly located in the skin and accounts for nearly 4% of all skin cancers (4). Melanoma may occur rarely in the eyes, leptomeninges, gastrointestinal tract and oral and genital mucous membranes. Ocular melanoma is approximately 4% of all malignant melanomas and 90% of them are originated from the uvea (2). Uveal melanoma is the most common primary intraocular tumor in adults and metastatic liver disease develops nearly 50% of patients up to 15 years of diagnosis (1). Long time interval between primary disease onset and metastasis may cause problems on recognizing the recurrent disease. The medical history of patient is very important to early diagnosis of such cases.

Our case highlights a well known metastatic potential of a rare tumor. But evaluating the medical records of the patient obtains important data on the diagnosis of the disease and that would be cost effective. Metastatic cancers account for nearly 95% of all liver tumors which are most commonly originated from breast, lung, colorectal, pancreas, gastrointestinal tract and genitourinary system (5,6). Melanoma consists less than 1% of all metastatic liver cancers and most of the cases are associated with skin melanoma (5,6). Metastatic liver cancer due to uveal melanoma is rare in clinical practice. In a study, which included 704 cases of metastatic tumors of the liver, 9 cases (1.28%) were diagnosed as malignant melanoma and only one of them had ocular disease (7). In a large series of metastatic liver cancers including more than 500 cases in our pathology department, only 1 case of uveal melanoma had been diagnosed in last 10 years (unpublished data).

In conclusion metastatic liver cancer due to uveal melanoma is a rare clinical entity. The medical history of the patient is very important for suspicion of the underlying pathology. In occasion of abdominal symptoms and hepatomegaly with a history of orbital surgery, liver metastasis should be kept in mind.

References

1. Singh AD, Bergman L, Seregard S. Uveal melanoma: epidemiologic aspects. *Ophthalmol Clin North Am* 2005;18:75-84.
2. Cather JC, Cather JC, Soparkar CN, Nelson BR. Ocular melanoma. *Cutis* 1999;63:285-92.
3. Danaloğlu A, Akyıldız M, Aksoy N, Demir K, Beşışık F, Çakaloğlu Y, et al. Malign melanom karaciğer metastazi: Olgu sunumu. *Akademik Gastroenteroloji Derg* 2003;2(1):28-30.
4. Lorigan JG, Wallace S, Mavligit GM. The prevalence and location of metastases from ocular melanoma: imaging study in 110 patients. *Am J Roentgenol* 1991;157:1279-81.
5. Paulson EK. Evaluation of the liver for metastatic disease. *Semin Liver Dis* 2001;21:225-36.
6. Oien KA. Pathologic evaluation of unknown primary cancer. *Semin Oncol* 2009;36:8-37.
7. Soylyuer I, Ekinçi C, Kaya M, Bahar K. The value of fine needle aspiration biopsy in the diagnosis of metastatic liver tumours. *Turk J Gastroenterol* 2002;13:78-82.