

## Vestibular neurectomy in resistant Meniere disease which underwent endolymphatic sac surgery: a case report

Endolenfatik kese operasyonu uygulanan dirençli Meniere hastalığında vestibular nörektomi vaka analizi

Cengiz Çevik<sup>1</sup>, Ercan Akbay<sup>1</sup>, Yaşar Çokkeser<sup>1</sup>

<sup>1</sup>Mustafa Kemal University, Faculty of Medicine, Department of Otolaryngology, Hatay

### Abstract

Meniere disease is characterized by recurrent vertigo episodes, a sensation of fullness at ear, tinnitus and fluctuating hearing loss. Clinical findings have an important role in diagnosis of disease. In our study, we aimed to present two cases, a woman (35 years old) and a man (34 years old), underwent to vestibular neurectomy, which previously underwent endolymphatic sac surgery because having no benefit from medical therapy and recurrent complaints 1 and 6 months after endolymphatic surgery, respectively. No post-operative complication was seen. It was found that there was a formation of diffuse granulation surrounding sac, which blocked drainage.

**Keywords:** Endolymphatic sac; Meniere disease; vertigo; vestibular neurectomy.

### Özet

Meniere hastalığı tekrarlayan baş dönmesi atakları, kulakta dolgunluk hissi, kulak çınlaması ve değişken duyma ile karakterizedir. Klinik bulguların hastalığın teşhisinde önemli rolü vardır. Çalışmamızda daha önce ilaç tedavisinden fayda bulmayan ve daha önceden endolenfatik kese operasyonu geçirdikten sonra birinci ve altıncı aylarda tekrarlayan şikayetleri bulunan vestibüler nörektomi uygulanan 35 yaşında bir kadın ve 34 yaşında bir erkek hastanın yer aldığı iki vakayı ele almayı amaçladık. Herhangi bir post operatif komplikasyon gözlenmemiştir. Drenajı bloke eden kese etrafında yayılmış granülasyon gösteren bir oluşum bulundu.

**Anahtar kelimeler:** Endolenfatik kese; Menier hastalığı; vertigo; vestibüler nörektomi

### Introduction

Meniere disease is characterized by recurrent vertigo episodes, sensation of aural fullness, tinnitus and fluctuating hearing loss. The disease is usually seen at third or fourth decade of life; it is generally unilateral and prevalence of the disease is similar in both sexes (1). Severe vertigo may last 30 minutes to 24 hours. Then symptoms gradually relieve, and patient returns to normal within 72 hours. Slightly impaired balance and dizziness may persist several days to week until recovery. Hearing loss and tinnitus display gradual improvement during this recovery period. However, sensorineural hearing loss at low frequency may be permanent (1). Increase in the number and frequency of episodes negatively affect the improvement in hearing loss. Clinical improvement and decrease in the number and frequency of episodes are expected over years. However, clinical course may not always follow this pattern. Clinical findings have important role in diagnosis of the disease. Meniere disease is suggested by unilateral, sensorineural hearing loss at low frequencies and increasing decline in discrimination score in audiometer. Caloric test, electrocochleography and electrocochleogram findings may help in diagnosis. Endolymphatic hydrops is implied in the pathophysiology of Meniere disease. Medical therapy and dietary intervention may be helpful in the control of Meniere episodes. However, surgical therapy is indicated in patients resistant to medical therapy (2). Vestibular neurectomy, decompression of

endolymphatic sac and labyrinthectomy are the surgical methods used in drug resistant Meniere disease (2). In this study, we aimed to present two cases underwent vestibular neurectomy in our clinic who had long-term symptom control by medical therapy; however, underwent endolymphatic sac surgery because of having no benefit from medical therapy and had recurrent complaints after first surgery.

### Case 1

A 35-years old woman, who had vertigo episodes, fluctuating hearing loss, tinnitus and fullness sensation in ear for 5 years and had been followed by medical therapy, underwent endolymphatic sac surgery 3 months ago, as the vertigo episodes became more frequent and her social and psychological life were negatively affected. Audiometric test was 47 dB in left ear and 13 dB in right ear. There was a formation of diffuse granulation in middle ear on temporal MRI (Figure 1); however, no pathological finding was detected at the trace of vestibular nerve (Figure 2). It was observed that T-tube previously placed into endolymphatic sac during surgery was surrounded by granulation at middle ear. Vestibulocochlear nerve was exposed by removing granulation and vestibular neurectomy was performed.

### Case 2

A 34-years old man who had Meniere disease and had been followed by medical therapy for 9-10 years underwent endolymphatic sac surgery 2 years ago, as he had worsening in vertigo episodes rather than improvement in vertigo attacks by medical therapy.

**İletişim/Correspondence to:** Cengiz Çevik, Mustafa Kemal University, Faculty of Medicine, Department of Otolaryngology, Hatay, TURKEY  
Tel: +90 533 727 12 24 [drcecevik@yahoo.com](mailto:drcecevik@yahoo.com)

**Received:** 13.06.2012 **Accepted:** 16.08.2012  
**Geliş Tarihi:** 13.06.2012 **Kabul Tarihi:** 16.08.2012

DOI: 10.5455/GMJ-30-2012-101  
[www.gantep.edu.tr/~tipdergi](http://www.gantep.edu.tr/~tipdergi)  
ISSN 1300-0888

Patient who had vertigo at early post-operative period had no recurrent vertigo attacks for one year. A vestibular neurectomy was scheduled because of recurrent complaints in this patient. Audiometric test was 83 dB in left ear and 7 dB in right ear. During surgery, it was seen that there was a formation of diffuse granulation around endolymphatic sac, which blocked drainage (Figure 3). Vestibulocochlear nerve was exposed by removing granulation and vestibular neurectomy was performed (Figure 4).

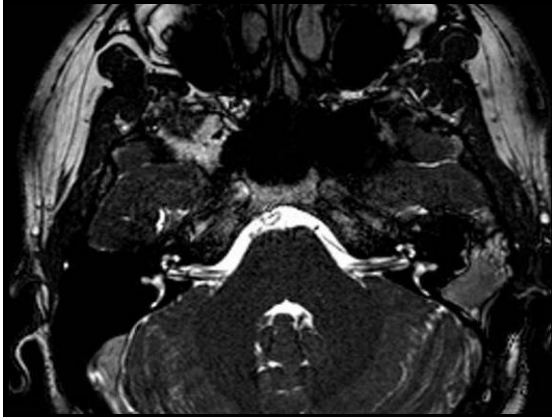

Figure 1. Case 1 diffuse granulation at middle ear on temporal MRI.

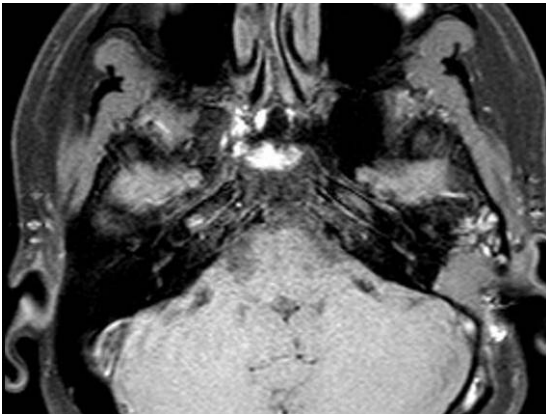


Figure 2. Case 1 trace of vestibular nerve on temporal MRI.

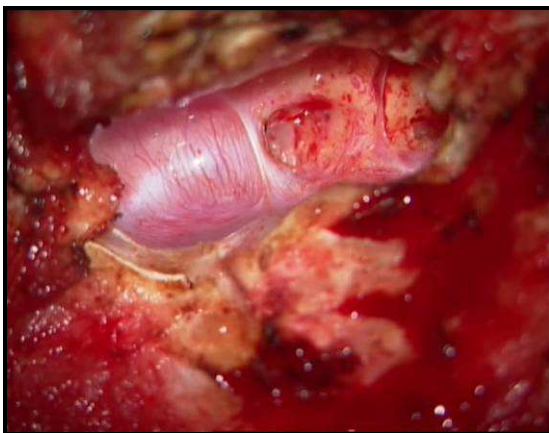


Figure 3. Case 2 Diffuse granulation around endolymphatic sac intraoperatif imaging.

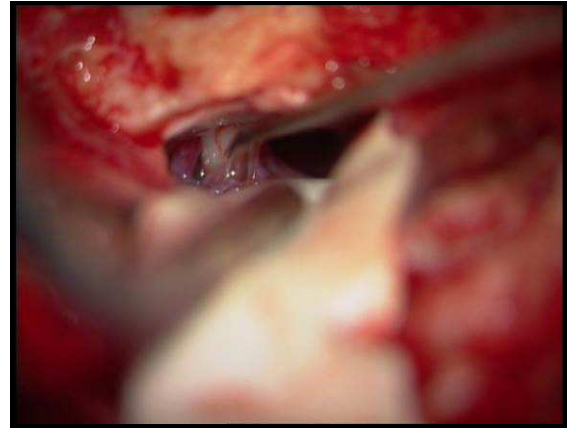


Figure 4. Case 2 Vestibular nerve intraoperatif imaging.

#### Discussion

Several medical agents have been used in the treatment of Meniere disease. These agents provide substantial success in the control of vertigo episodes in conjunction to dietary intervention (2). Several surgical intervention directed to endolymphatic sac and vestibular nerve should be considered in patients resistant to medical therapy and in those having increased number and frequency of episodes.

Vestibular neurectomy, decompression of endolymphatic sac and labyrinthectomy are the surgical methods used in drug resistant Meniere disease. Success rate varies from 50% to 70% in endolymphatic sac procedures (3). For retrosigmoid vestibular neurectomy, there are studies reporting 96.4% of vertigo control and 94.4% of hearing preservation (4). In a study, Wetmore et al. reported that cases which had recurrence as short as 24 months after sac surgery should benefit from revision surgery (5). There was worsening in complaints a month after sac surgery in our first case, whereas 6 months after in the second case. In both cases it was found that there was a diffuse granulation around sac, which blocked drainage. As reported by Wetmore et al., vestibular neurectomy is a good therapeutic alternative in cases having recurrence after endolymphatic sac surgery.

It has been reported that intratympanic gentamicin therapy achieved successful outcomes in patients with recurrence after endolymphatic sac surgery (6). Intratympanic aminoglycoside or steroid administrations are preferred due to technical ease. Silverstein et al. reported that middle ear perfusion is the choice of treatment in cases unresponsive to medical therapy and vestibular neurectomy could be successfully used in cases resistant to minimal invasive interventions and/or preservation of hearing desired (7). Effectiveness on vertigo control varies from 50% to 95%; hearing loss develops in 10-40% of the cases and hearing loss increases as the recovery rate of vertigo increases. There are studies reporting 96.4% of vertigo control and 94.4% of hearing preservation. In our first case hearing level was 47 dB, whereas 83 dB in second case (3).

Signal transduction is interrupted at the level of first neuron; thus, stimulation of vestibular end organ by afferent nerve is permanently and irreversibly blocked in vestibular neurectomy. Vestibular neurectomy is preferred over endolymphatic sac surgery, as it achieves better vertigo control and preservation of hearing. Early recurrence after sac surgery makes it less preferred method (3). During surgery, it was found that blockage of drainage by diffuse granulation surrounding endolymphatic sac resulted in failure of surgery in both cases. As vestibular neurectomy is an intracranial procedure, it has serious complications (8).

#### *Conclusion*

Meniere disease negatively affects psychosocial life of patients, as it has a clinical course characterized by recurrent vertigo episodes. Vestibular neurectomy is more successful than endolymphatic sac surgery and intratympanic aminoglycoside injection in controlling vertigo. Despite relapses in latter treatments, vestibular neurectomy permanently achieves higher control rate in vertigo. When compared to intratympanic aminoglycoside injection, the lower incidence of permanent hearing loss in vestibular neurectomy make

vestibular neurectomy preferred therapy in Meniere disease.

#### *References*

1. Bolluk B, Aydın N. Periferik vertigoya yaklaşım. J Kartal Tr 2004;15(3):191-4.
2. Şengör A, Koç A, Özkarakaş H. Meniere Hastalığı'nda intratimpanik gentamisin uygulaması. KBB-Forum 2004;3(2):66-71.
3. Bayramoğlu İ, Yılmaz M, Göksu N, Ceylan A, Ural A, Kemaloğlu Y. Periferik vertigolu hastalarda vestibuler nörektomi (12 Yıllık sonuçlarımız). KBB-Forum 2004;3(2):42-4
4. Arenberg IK, Silverstein H, Garcia-Ibanez E, Vander Ark G. Primary surgery for Meniere's disease: destructive surgery versus conservative surgery. Am J Otol 1986;7(4):5p preceding 241.
5. Wetmore SJ. Endolymphatic sac surgery for Ménière's disease: long-term results after primary and revision surgery. Arch Otolaryngol Head Neck Surg 2008;134(11):1144-8.
6. Marzo SJ, Leonetti JP. Intratympanic gentamycin therapy for persistent vertigo after endolymphatic sac surgery. Otolaryngol Head Neck Surg 2002;126(1):31-3.
7. Silverstein H, Jackson LE. Vestibular nerve section. Otolaryngol Clin North Am 2002;35(3):655-73.
8. Fisch U. Transtemporal supralayrinthine (middle cranial fossa) vestibular neurectomy: a review of the last 100 cases. Skull Base Surgery 1996;6(4):221-5.