



# Neonatal cortical hyperostosis secondary to prolonged use of prostaglandin E1 in a patient with pulmonary atresia

Pulmoner atrezili bir hastada uzun süreli prostaglandin kullanımına bağlı neonatal kortikal hiperostoz

Nazan Neslihan DOĞAN<sup>1</sup>, Dilek DİLLİ<sup>1</sup>, Melek PALA AKDOĞAN<sup>2</sup>, Utku Arman ÖRÜN<sup>3</sup>, Hakan AYDIN<sup>4</sup>, Ayşegül ZENCİROĞLU<sup>1</sup>

<sup>1</sup> Clinic of Neonatology, Dr. Sami Ulus Maternity and Children Training and Research Hospital, Ankara, Turkey

<sup>2</sup> Clinic of Radiology, Dr. Sami Ulus Maternity and Children Training and Research Hospital, Ankara, Turkey

<sup>3</sup> Clinic of Pediatric Cardiology, Dr. Sami Ulus Maternity and Children Training and Research Hospital, Ankara, Turkey

<sup>4</sup> Clinic of Cardiovascular Surgery, Dr. Sami Ulus Maternity and Children Training and Research Hospital, Ankara, Turkey

## ABSTRACT

Pulmonary atresia is a rare congenital cardiac malformation. The newborns with this anomaly are ductus dependent to maintain a continuous and adequate pulmonary blood flow. As spontaneous closure of the ductus is expected after few hours or days after birth, the patency of ductus should be provided by prostaglandin E1 (PGE1) while the patient is awaiting cardiosurgical intervention. PGE1 infusion is usually applied for a short time period. However, in some circumstances, the infusion duration may extend from weeks to months. Long term PGE1 infusions may produce several adverse effects. In this report, we presented a case of newborn with pulmonary atresia who developed cortical hyperostosis secondary to prolonged use of PGE1.

**Keywords:** Prostaglandin E1, cortical hyperostosis, newborn, cyanotic congenital heart disease

## ÖZ

Pulmoner atrezi nadir görülen bir konjenital kardiyak malformasyondur. Bu anomali ile doğan bebekler, devamlı ve yeterli pulmoner kan akımının sağlanması için duktusa bağımlıdırlar. Doğumdan sonra bir kaç saat veya gün içinde duktusun kendiliğinden kapanması beklendiği için kardiyovasküler girişim yapıncaya kadar duktus açıklığı prostaglandin E1 (PGE1) ile sağlanmalıdır. PGE1 infüzyonu genelde kısa süreli uygulanmaktadır. Bununla birlikte, bazı durumlarda infüzyonun haftalarca veya aylarca verilmesi gerekebilir. Uzun süreli PGE1 infüzyonu bir takım yan etkilere yol açabilir. Bu yazıda, uzun süreli PGE1 infüzyonuna bağlı kortikal hiperostoz gelişen pulmoner atrezili bir yenidoğan olgu sunuldu.

**Anahtar Kelimeler:** Prostaglandin E1, kortikal hiperostoz, yenidoğan, siyanotik konjenital kalp hastalığı

## INTRODUCTION

Pulmonary atresia (PA) is one of the uncommon forms of complex cyanotic cardiac diseases accounting for approximately 1% of them in the neonatal period (1). Complete obstruction of pulmonary valve is followed by a total obstruction of the right ventricular outflow. So, the newborns who suffer from this anomaly are ductus dependent to maintain a continuous and adequate pulmonary blood flow. As spontaneous closure of the

ductus is expected after few hours or days after birth, the patency of ductus should be provided by prostaglandin E1 (PGE1) while the patient is awaiting cardiosurgical intervention (2). Intravenous PGE1 infusions were first used in 1975 in infants with obstructive right heart malformations (3). The recommended initial dose of PGE1 is 0.05-0.1 µg/kg/min, and the dose may be titrated according to the response of the infant. If a constricted ductus has opened the dose can be reduced to 0.002-

**Yazışma Adresi/Correspondence:** Dilek DİLLİ

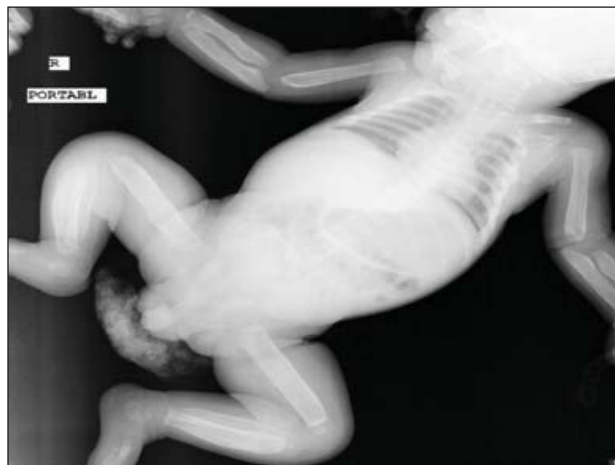Dr. Sami Ulus Çocuk Hastanesi, Babür Caddesi, Altındağ/Ankara, Türkiye  
**Telefon/Tel:** +90 532 6713196 • **E-posta/E-mail:** dilekdilli2@yahoo.com

**Geliş Tarihi/Received:** 29.11.2015 • **Kabul Ediliş Tarihi/Accepted:** 27.03.2016

0.05 µg/kg/min. PGE1 infusion is usually applied for a short time period. However, in some circumstances, such as low birth weight, sepsis or absence of a specialized pediatric cardiology, cardiovascular surgery and/or tertiary neonatal intensive care unit (NICU), the infusion duration may extend from weeks to months. At the onset of the PGE1 treatment, several side-effects may occur that are generally reversible once the therapy is discontinued. Complications of long-term PGE1 infusion have been defined such as cortical hyperostosis, gastric-outlet obstruction, fluid electrolyte imbalance and pseudo-Bartter syndrome (4-7). In this report, we presented a case of newborn with PA who developed cortical hyperostosis secondary to prolonged use of PGE1.

### CASE REPORT

A 24-day-old male baby, who was delivered spontaneously in a regional hospital of Syria, was referred to our hospital. It was noted that the mother was not under routine prenatal care due to the ongoing civil war in Syria. After delivery the family had fled from Damascus for refuge in Turkey. On the second day of life, the baby was admitted to a level II NICU in a South-Eastern Turkish town of Urfa, because of cyanosis and respiratory distress. On physical examination, a murmur accompanying to cyanosis was detected; he was consulted to a pediatric cardiologist. Echocardiography revealed PA and PGE1 infusion was initiated at a dose of 0.05 µg/kg/min. On the 24<sup>th</sup> day of life, he was transferred to our NICU for cardiosurgical intervention. He weighed 3300 g and had no major dysmorphic features except a rough face. Both upper and lower limbs were swollen and painful. A 3/6 systolic murmur was detected on cardiac auscultation. Echocardiography confirmed PA, intact atrial septum, ventricular septal defect (7 mm) and ductal patency. Pediatric cardiologists suggested continuing the PGE1 infusion (0.05 µg/kg/min) until surgery. Cardiovascular surgeons planned to perform a Blalock-Taussig (BT) shunt. However, the surgery was postponed due to clinical sepsis with fever, respiratory distress, leukocytosis, and high C-reactive protein levels. Antibiotic therapy was started after obtaining blood culture. At follow-up, pain and swelling observed in both extremities gradually increased. The X-Rays of the long bones revealed an intense periosteal reaction with bilateral corticoperiosteal thickening of the diaphyses (Figure 1). Laboratory analyses were performed for differential diagnosis of cortical thickening. Electrolyte imbalance or any findings of gastric outlet obstruction were not noted. Serology tests for syphilis were negative. Alkaline phosphates level was 822 U/L with normal calcium, phosphate and 25-OH vitamin D levels. There was no history of vitamin A ingestion. The rest of the liver function tests were normal. Then, considering



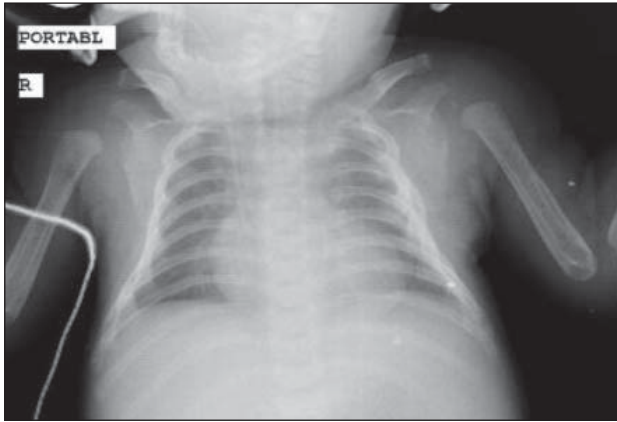
**Figure 1.** Diffuse cortical thickening (hyperostosis) and periosteal reaction involving the long bones (femur, tibia, and humerus) and clavicles.

the duration of PGE1 infusion, our findings suggested prostaglandin osteopathy. It was estimated that cortical hyperostosis developed after the cumulative dose of PGE1 of 5702 µg/kg.

Acetaminophen was given for pain relief. Antibiotic therapy for sepsis was continued for 26 days and stopped after three negative blood cultures. Subsequently, modified BT shunt was performed at 50<sup>th</sup> day of life. The infant had a good recovery from surgery without need of PGE1 infusion. After discontinuing PGE1 infusion the pain and swelling of the limbs in addition to the roughness of the face gradually decreased. Control X ray graphs taken four weeks after surgery showed radiological regression of the corticoperiosteal thickening (Figure 2).

### DISCUSSION

The most common and dose related side effects of PGE1 therapy are apnea (12%), flushing and edema (10%), bradycardia (7%) ± hypotension (4%), hyperthermia (14%). Less common side effects are seizures (4%), sepsis (2%), diarrhea (2%) and tachycardia (3%) (8). Respiratory depression, arrhythmias, congestive heart failure, wheezing, gastric regurgitation, bleeding, anuria, hematuria, thrombocytopenia, peritonitis, hypo/hyperkalemia, hypoglycemia and jitteriness are also reported (9). Recently, it was suggested that the lower initial dose of PGE1 of 20 ng/kg/min and a maintenance dose of 10 ng/kg/min caused much fewer complications, such as apnea, fever, and hypotension<sup>(10)</sup>. PGE1 infusion was needed at high doses for a long time in our patient. Complications of long term (> two weeks) PGE1 infusion are cortical hyperostosis, gastric outlet obstruction and pseudo-Bartter syndrome (4-7,11). In the presented case, the reasons for the delay of surgery and long term (50 days) PGE1 infusions were late admission of the patient and severe sepsis attacks. After the 24<sup>th</sup> day of PGE1



**Figure 2.** Resolution of cortical thickening, four weeks after the Blalock-Taussig shunt operation.

infusion, he developed fever, coarse skin, rough face, and painful swelling in the both upper and lower limbs. X-Ray studies showed cortical hyperostosis in the long bones and also both clavicles.

The cortical hyperostosis of the long bones seems to be related with the duration of PGE1 infusion. In a study, the rate of hyperostosis was reported as 42 percent among infants who received PGE1 infusion more than 30 days. Once the duration of infusion exceeds 60 days, hyperostosis rate increased to 100 percent (4). Talosi et al. reported that cortical hyperostosis developed after different cumulative doses (1584, 3384 and 4320 µg/kg) in their case series (9). In our patient, it was estimated that cortical hyperostosis developed after the cumulative dose of PGE1 of 5702 µg/kg. Most infants with cortical hyperostosis are diagnosed by physical examination with soft tissue swelling, tenderness, limited mobility, and irritability. X-Rays can confirm the presence of bone changes and soft tissue swelling. Histological examination of bones with cortical hyperostosis due to prostaglandin shows rapid formation of primitive bone, extensive resorption of the outer cortical surface and bone formation of the inner surface. These changes of the bones are associated with high alkaline phosphate concentrations<sup>(4)</sup>. Physical and radiological findings of our patient were consistent with PGE1 related cortical hyperostosis.

The differential diagnosis of cortical hyperostosis includes congenital syphilis, Caffey disease (Infantile Cortical Hyperostosis), scurvy and hypervitaminosis A. If the cortical thickening is limited to a single bone; it may be secondary to trauma, tumor, or osteomyelitis (9).

In our case, syphilis was ruled out with the absence of clinical history and compatible serology. In hypervitaminosis A, cortical hyperostosis appears after many months or years of excessive ingestion of vitamin A. The cortical thickening seen in scurvy occurs during the healing process and usually does not affect such

small infants. Infantile cortical hyperostosis also known as Caffey disease is characterized by acute inflammation of the periosteum and the overlying soft tissue. The classic Caffey disease has an onset within the first 6 months of life, and the mandible is the most commonly involved bone (12). In this patient, the history of prolonged PGE1 utilization for maintaining ductal patency and normal mandible bone appearance in X-Ray exams suggested prostaglandin osteopathy rather than Caffey disease.

## CONCLUSION

Since cortical hyperostosis occurs in prolonged utilization of PGE1, this pathology should be kept on mind especially if the infusion is needed more than two weeks. To prevent the potential complications, the goal of PGE1 usage in severe cyanotic cardiac lesions must be to interrupt the therapy as soon as possible.

## REFERENCES

1. Keith JD, Rowe RD, Vlad P. In: Keith JD, Rowe RD, Vlad P (eds). Heart diseases in infancy and childhood, 2<sup>nd</sup> ed. Macmillan New York, 1967;923.
2. Leonhardt A, Glaser A, Wegmann M. Expression of prostanoid receptors in human ductus arteriosus. *Br J Pharmacol* 2003;138:655-9.
3. Elliott RB, Starling MB, Neutze JM. Medical manipulation of the ductus arteriosus. *Lancet* 1975;1:140-2.
4. Velaphi S, Cilliers A, Beckh-Arnold E. Cortical hyperostosis in an infant on prolonged prostaglandin infusion: case report and literature review. *J Perinatol* 2004;24:263-5.
5. Kosiak W, Swieton D, Fryze I, Aleszewicz-Baranowska J, Duklas M, Chojnicki M. Gastric outlet obstruction due to an iatrogenic cause in a neonatal period-report of two cases. *Ultraschall Med* 2009;30:401-3.
6. Vanhaesebrouck S, Allegaert K, Vanhole C. Pseudo-Barter syndrome in a neonate on prostaglandin infusion. *Eur J Pediatr* 2003;162:569-71.
7. Arav-Boger R, Baggett HC, Spevak PJ, Willoughby RE. Leukocytosis caused by prostaglandin E1 in neonates. *J Pediatr* 2001;138:263-5.
8. Lewis AB, Freed MD, Heymann MA, Roehl SL, Kensey RC. Side effects of therapy with prostaglandin E1 in infants with critical congenital heart disease. *Circulation* 1981;64:893-8.
9. Tálósi G, Katona M, Túri S. Side-effects of long-term prostaglandin E1 treatment in neonates. *Pediatr Int* 2007;49:335-40.
10. Huang FK, Lin CC, Huang TC, Weng KP, Liu PY, Chen YY, et al. Reappraisal of the prostaglandin E1 dose for early newborns with patent ductus arteriosus-dependent pulmonary circulation. *Pediatr Neonatol* 2013;54:102-6.
11. Abdelaziz M, John CM. Hyperostosis: an under-recognized complication of prostaglandin infusion. *Acta Pediatr* 2013;102:e192.
12. Shandilya R, Gadre KS, Sharma J, Joshi P. Infantile cortical hyperostosis (Caffey disease): a case report and review of the literature--where are we after 70 years? *J Oral Maxillofac Surg* 2013;71:1195-201.

### How to cite:

Doğan NN, Dilli D, Pala Akdoğan M, Örün UA, Aydın H, Zenciroğlu A. Neonatal cortical hyperostosis secondary to prolonged use of prostaglandin E1 in a patient with pulmonary atresia. *Gaziantep Med J* 2016;22(1):51-53.