

Is External Fixation Valid Option for Pertrochanteric Fractures in High-Risk Patients?

Bilgin Bozgeyik , Ahmet Fevzi Kekeç 

Clinic of Orthopedic and Traumatology, Dörtöyl State Hospital, Hatay, Turkey

ABSTRACT

Objective: The objective of the present study was to evaluate whether surgical treatment of the pertrochanteric fractures of the femur with external fixator could reduce the pre- and postoperative length of hospital stay, with low complications and mortality and with satisfactory functional results to achieve rehabilitation and incorporation into the daily life in high-risk patients.

Methods: Twenty-six patients who had pertrochanteric fractures were treated using the Orthofix Pertrochanteric Fixator (Bussolengo Verona, Italy). There were 14 male and 12 female patients. The mean age of the patients was 73 (37–93) years. The fractures were classified according to the modified Evans classification. Of the fractures, 19 were unstable, and 7 were stable. Patients were evaluated on the day the fixators were removed according to the Foster criteria.

Results: The mean operative time was 24 (20–65) min. The average hospitalization was 12.7 (3–43) days. The average union time of the 16 patients who were alive and whose fixators could be removed was 5.2 (3–11) months. Stable fractures healed at approximately 4.1 months, whereas unstable fractures healed at 5.9 months. Six patients developed pin tract infection and five of them were superficial. During the 12-month follow-up period, 10 patients died from causes unrelated to the operation. The mortality rates of the 26 patients who had intertrochanteric fractures treated with pertrochanteric fixator in our retrospective study were 23.07% within the first 30 days and 42.3% within 1 year.

Conclusion: In conclusion the use of external fixation for the management of pertrochanteric fractures in elderly patients of poor health is a valuable and valid alternative surgical method.

Keywords: Pertrochanteric fracture, external fixation, elderly

INTRODUCTION

In the 20th century, there has been a significant increase in the average life span with the parallel improvement of the scientific development of living conditions. The elderly population develop osteoporosis in proportion to malnutrition and inactivity. As a result, pertrochanteric femur fractures can occur with a simple trauma. Several treatments have been tested in the treatment of fractures of this region, and the advantages and disadvantages of each method have been reported over time.

Most hip fractures are seen in elderly patients with osteoporosis who have prior problems and functional limitations. Owing to the good blood supply in intertrochanteric femur fractures, conservative treatment is possible because of the low incidence of non-union and avascular necrosis, but the complications of immobilization in elderly patients lead to increased mortality and morbidity up to 60% with conservative treatment (1, 2).

This elderly patient population often has cardiac, pulmonary, and genitourinary system disorders and metabolic and neurological problems, and the timing and planning of treatment are difficult (3). The purpose of surgical treatment is to improve the quality of life by providing early mobilization and to restore the prefracture status as soon as possible (4). The quality of surgery

depends on the selected osteosynthesis method, surgical technique, bone quality, and reduction quality.

Treatment options include internal fixation, hemiarthroplasty, and external fixation. These methods have advantages and disadvantages. Plates and intramedullary nails are used in the internal fixation method. The disadvantage of the internal fixation method is the necessity to open the fracture area for fixation with plates. If close reduction could not be made during fixation with an intramedullary nail, open surgery must be performed. However, in both methods, the operation time is long, and it is a hemorrhagic surgical method that may require blood transfusion during the operation. In both methods, there is a risk of failure in the screws inserted into the femoral neck, but they provide a rigid fixation. Reduction loss and non-union are rarely seen in the postoperative period, especially in patients with unstable fractures. The disadvantages of hemiarthroplasty include a more bleeding method, serious complications due to cement, long operation time, dislocation of the postoperative hip, and revisions due to cement. The advantage is that the patient can be allowed full weight bearing postoperatively. The disadvantages of hemiarthroplasty are intraoperative blood loss, serious complications due to cement, long operation time, dislocation of the hip, and revision difficulties due to cement. However, hemiarthroplasty patients can be allowed full

ORCID IDs of the authors: B.B. 0000-0001-9459-6535; A.F.K. 000-0003-2045-4686.

Corresponding Author: Bilgin Bozgeyik E-mail: bilginbozgeyik@hotmail.com

Received: 06.12.2017 • Accepted: 23.01.2018

weight bearing significantly earlier than internal fixation patients. External fixation has several advantages, such as short operation time, minimal bleeding, and short residence time, but also disadvantages, such as loss of reduction especially in unstable fractures, pin tract infection, and pin loosening.

The objective of the present study was to evaluate whether surgical treatment of the pertrochanteric fractures of the femur with external fixator could reduce the pre- and postoperative length of hospital stay, with low complications and mortality and with satisfactory functional results to achieve rehabilitation and incorporation into the daily life in high-risk patients.

METHODS

Between 2007 and 2013, 26 (10%) of the 270 patients with pertrochanteric fractures who were admitted to our department were classified by the anesthetist as American Society of Anesthesiologists (ASA) grade 3 or 4 and considered not suitable for conventional fracture fixation. Table 1 shows the medical conditions causing the patients to be considered as high risk.

Written informed consent was obtained from all the patients who participated in the study. Ethics committee approval was obtained from Gaziantep University (date: 2013/decision no: 328).

Twenty-six patients who had pertrochanteric fractures were treated using the Orthofix Pertrochanteric Fixator (Bussolengo Verona, Italy). There were 14 male and 12 female patients. The mean age of the patients was 73 (37–93) years. The right hip was involved in 12 cases, and fracture occurred in the left hip in the remaining 14. Two of the fractures occurred in traffic accidents, and the remaining 24 were caused by simple in-house fall. The fractures were classified according to the modified Evans classification (5). Of the fractures, 19 were unstable, and 7 were stable (Table 2).

Of the patient’s operations, 10 were performed under general anesthesia, 13 were under regional spinal anesthesia, and 3 were under sedoanalgesia. The patient was placed on a fracture table, and a closed reduction of the fracture was performed under image intensification in all cases. A guide wire was inserted percutaneously at a 125°–130° angle approximately into the center of the femoral neck and head. Two long, 6.5 mm, self-drilling and self-tapping pins were inserted manually on each side of the guide wire within the confines of the femoral neck. The pins were advanced to approximately 10 mm from the subchondral bone of the head. The device attached to the proximal pins acted as a guide for the insertion of the two distal pins. When the implantation of the two proximal pins is complete, the posterior clamp-locking screws are tightened, leaving a distance of 1 to 2 cm between the skin and the posterior clamp. The mean operative time was 24 (20–65) min. Parenteral cephalosporin was given for 2 days after the operation, and low-molecular-weight heparin was administered until discharge.

On postoperative day 1, full weight bearing with a walker is allowed as tolerated. Only four very senile patients who were non-ambulatory before the occurrence of the fracture were not able to walk

Table 1. Medical conditions of high-risk patients

Medical conditions increasing surgical risk	Patients (n)
Chronic renal failure	4
Chronic renal failure and insulin-dependent diabetes mellitus	5
Cardiovascular disease	2
Cardiovascular and pulmonary diseases	3
Total	14

Table 2. Classification of our cases according to the fracture types

Type of fractures according to the modified Evans classification	Patients operated (n)	Patients can be evaluated (n)
Stable Type 1	7	6
Unstable Type 2	10	5
	Type 3	9
Total	26	16

Table 3. Foster’s criteria

	Functional grading	Anatomical grading
Excellent	Walks as well as before the operation. No limp or pain	Union in perfect position
Good	Walks well, uses stick to go out	<10° varus and minimal shortening
Fair	Requires stick, considerable limp or pain	10°–25° of varus and 0.5 to 1 in of shortening
Poor	Bedridden or confined to chair	Severe malunion, varus deformity of ≥25° or >1 in of shortening

postoperatively. Pin site care was performed every day, and the patients’ families were given instructions on continuing the pin site care after discharge from the clinic. The average hospitalization was 12.7 (3–43) days. Outpatient visits were arranged every month until the fracture was united, and the fixator was removed. Only 16 patients were evaluated according to fracture union and function because 10 patients died within the first 1 to 120 days after surgery before fracture healing was completed. Patients were evaluated on the day the fixators were removed according to the Foster criteria (6). Table 3 shows the Foster criteria.

Statistical Analysis

Statistical analyses were performed using the Statistical Package for the Social Sciences (SPSS) version 16.0 statistical package for Windows (SPSS Inc.; Chicago, IL, USA). Continuous data were expressed as mean, whereas categorical data were presented as percentage (%).

Table 4. Postoperative complications

Postoperative complications	Patients (n)	Treatment
Superficial pin tract infection	5	Oral antibiotic therapy and dressing
Deep pin tract infection	1	Parenteral antibiotic therapy
Refracture	1	Hemiarthroplasty
Anemia	2	Blood transfusion

Table 5. Functional and anatomical grading of cases according to their fracture types

	Functional grading		Anatomical grading	
	Stable fractures	Unstable fractures	Stable fractures	Unstable fractures
Excellent	4	6	3	4
Good	1	3	3	4
Fair	–	1	–	1
Poor	1	–	–	1
Total	6	10	6	10

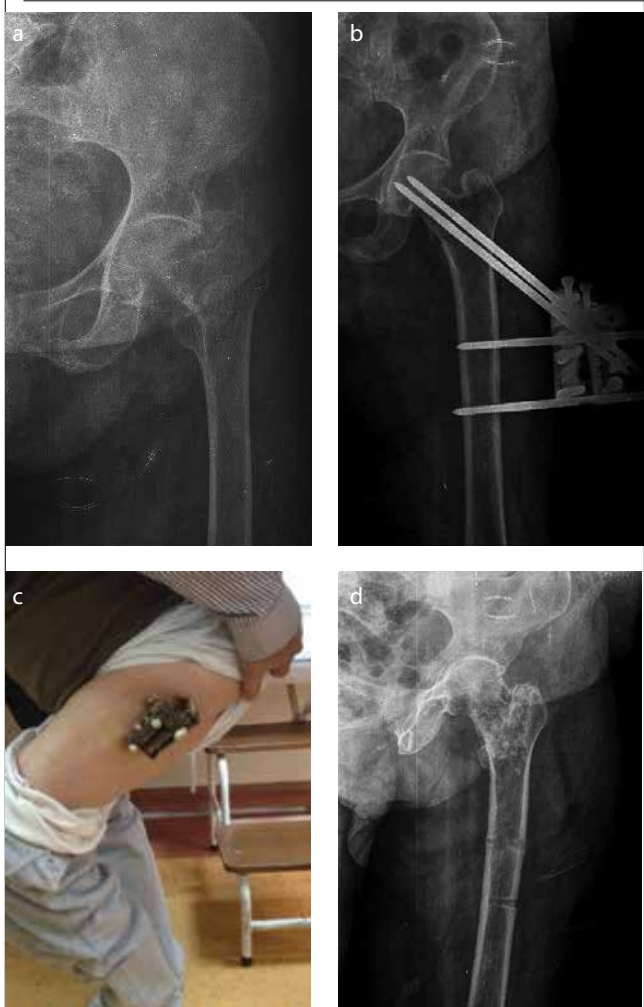
RESULTS

The analysis of the results showed that in relation to the most affected gender, there were 14 men and 12 women. The average age of the patients was 73 (37–93) years. Two patients required blood transfusion postoperatively. The fixator did not interfere with sitting or lying, and there was no restriction of knee movements. The predominant etiology was by fall during walking at home with 92% (24/26). The mean operative time was 24 (20–65) min. The average hospitalization was 12.7 (3–43) days. The average union time of the 16 patients who were alive and whose fixators could be removed was 5.2 (3–11) months. Stable fractures (Evans–Jensen type 1) healed at approximately 4.1 months, whereas unstable fractures (Evans–Jensen types 2 and 3) healed at 5.9 months. Figure 1 shows an 82-year-old patient who had unstable pertrochanteric fracture treated with external fixation and healed with satisfactory functional result.

There were no cases of pin loosening, breakage, or penetration of the femoral head. Twelve patients had an average limb shortening of 18 mm. With respect to the femoral varus compared with the contralateral side, an average of 126.7° (118°–139°) collodiaphyseal angle in the fractured side was calculated (non-fractured side collodiaphyseal angle was 135.5°).

Several complications were seen in eight cases (Table 4). Five patients developed superficial pin tract infection. This involved the proximal pins in all cases. The infections were successfully treated with oral antibiotics and daily cleansing with antiseptic solutions. One developed deep pin tract infection, and intravenous antibiotics were administered for 1 week. There was no

Figure 1. a-d. (a). Preoperative X-ray of left intertrochanteric Evans–Jensen type 2 fracture of an 82-year-old m an. (b) Postoperative X-ray of the patient with external fixator. (c) Full weight bearing and knee flexed position of the patient at postoperative week 1. (d) After removal of external fixator and excellent healing anatomically at 4 months



osteomyelitis, and none of the pins have to be removed before completion of the treatment in any patient. The patient who developed refracture and treated with hemiarthroplasty was not excluded from the evaluation because he had fracture 3 months after removal of the fixator. There were no cases of pin loosening, breakage, or penetration of the femoral head.

During the 12-month follow-up period, 10 patients died from causes unrelated to the operation. The mortality rates of the 26 patients who had intertrochanteric fractures treated with pertrochanteric fixator in our retrospective study were 23.07% within the first 30 days and 42.3% within 1 year. When the alive patients were evaluated according to the Foster criteria, anatomically, 7 patients were excellent (3 stable and 4 unstable), 7 were good (3 stable and 4 unstable), 1 was fair (unstable), and 1 was poor (unstable). Functionally, 10 patients were excellent (4 stable and 6 unstable), 4 were good (1 stable and 3 unstable), 1 was fair (unstable), and 1 was poor (stable) (Table 5).

DISCUSSION

Improvements in health services have resulted in a significant increase in survival and pertrochanteric fracture incidence, which mainly occur in the elderly population. Intertrochanteric femur fractures constitute approximately 8%–10% of all fractures in the body. They usually occur as a result of low-energy traumas in older ages and high-energy trauma in young people. Age and other factors increase the tendency to fall. These are visual loss, loss of muscle strength, blood pressure variability, vascular diseases, and musculoskeletal system pathologies. These fractures are seen at the third frequency after distal radius fracture and femur neck fracture in the elderly (7). More than 200,000 patients with intertrochanteric femur fractures are seen annually in the United States. The overall mortality has been reported as high as 10% at 30 days and 30% at 1 year post-injury (8, 9). The mortality risk increases along with the presence of several factors, including increasing age, male gender, number of comorbidities, low mini-mental test score on admission, low hemoglobin concentration on admission, residence in an institution, and the presence of malignant disease (10, 11). When the mortality rates of the 26 patients who had intertrochanteric fractures treated with pertrochanteric fixator in our retrospective study were analyzed, the mortality rates were 23.07% within the first 30 days and 42.3% within 1 year. These results support the study by Moran et al. (12).

Conservative treatment is an unacceptable alternative since it has been associated with mortality of up to 60% (1, 2). The purpose of surgical treatment is to improve the quality of life by providing early mobilization and to restore the prefracture status as soon as possible (4). The quality of surgery depends on the selected osteosynthesis method, surgical technique, bone quality, and reduction quality.

Over the years, several surgical fixation techniques have been proposed. The most widely used implants are the sliding hip screw and the intramedullary hip screw. Internal fixation has several potential disadvantages: patient preparation is difficult and is related to a higher surgical risk intraoperatively and postoperatively, such as potential blood loss, soft tissue manipulation, difficulties of patient positioning, and fracture reduction and obligation of traction table (13).

The biomechanical advantages of the intramedullary hip screw over the sliding hip screw include increased stability and better loading of the proximal part of the femur (14). Furthermore, with intramedullary fixation, a buttress is created that minimizes the amount of translation, helping to control fracture impaction. Another advantage of the intramedullary device is that insertion requires a less invasive surgical approach. However, even with intramedullary fixation, the lateral cortex may be damaged during implantation. Both techniques are associated with high rates of implant failure (ranging from 5% to 20%), including lag screw cut-out and cortical screw pull-out, particularly when the devices are used to treat unstable fractures (15, 16).

Several complications are also described related to intramedullary implants, including malalignment, cut-out, infection, false

drilling, wrong lag screw length and drill bit breakage during the interlocking procedure, external or internal malrotation ($\geq 20^\circ$) of the femoral diaphysis, elongation of the femur (up to 2 cm), impaired bone healing, periprosthetic fracture distal to the tip of the nail, fracture collapse, implant failure, lag screw intrapelvic migration, neurovascular injury, secondary varus deviation, complications after implant removal, trochanteric pain, and re-fracture (17).

Vossinakis and Badras compared sliding nail with external fixators in a prospective randomized study of 100 patients with pertrochanteric fractures (18). After 6 months of follow-up, patients with external fixator were found to have less blood loss, shorter operation time, less postoperative pain, shorter hospital stay, earlier mobilization, and less mechanical complication rate.

Cochrane reviewed three published studies and found a shorter operative time, less surgical trauma, less postoperative pain, earlier mobilization, and shorter in-hospital duration for a pertrochanteric external fixation compared with a sliding hip screw (19).

Shortening because of collapse and varisation of the femoral neck is a well-recognized complication of both internal and external fixation in unstable fractures or in the presence of severe osteoporosis (20–22). In our study, 12 (46%) patients had an average limb shortening of 18 mm. With respect to the femoral varus compared with the contralateral side, an average of 126.7° (118° – 139°) collodiaphyseal angle in the fractured side was calculated (non-fractured side collodiaphyseal angle was 135.5°), but these varus and shortening complications were not associated with implant failure or cut-out. The Orthofix Pertrochanteric Fixator device used in our study offers enough stability to allow full weight bearing without compromising fracture healing. Lack of mechanical complication has been attributed to the large contact surface between the pins and the bone and to a degree of controlled sliding (23). Although the proximal pins are not free, smooth shafts of pins could slide in the lateral cortex, allowing minimal impaction at the fracture. It has also been suggested that the elasticity of the fixation due to the increased distance of the fixation device from the femur promotes early, florid callus formation that allows the early participation of the bone in load bearing, thus reducing the stresses on the fixation (24). However, these theories require documentation by appropriate biomechanical studies.

The main disadvantage of external fixation is the tendency to superficial pin tract infection. In the treatment of hip fractures with external fixators, the risk of pin tract infection varies 0%–30% (24–26). In our study, superficial pin tract infection was observed in 5 (19%) patients and deep pin tract infection in 1 (4%). In the literature, deep infection that required pin removal or repositioning has been reported (1, 20, 27). However, superficial and deep pin tract infections did not require reoperation and did not affect the functional results of our patients.

Another well-described disadvantage of external fixation in the pertrochanteric fractures is postoperative knee stiffness caused by fixation of the fascia lata and vastus lateralis by the distal pins (20). This problem was not seen in our study due to the use of

short pertrochanteric fixator, which did not allow the placement of the distal pins distally in the femur.

Petsatodis et al. compared the stable intertrochanteric fractures and unstable intertrochanteric fractures with other valid surgical options and revealed that external fixation reduces operative time and minimizes blood loss (28). Their study also suggested that when external fixation is used in unstable pertrochanteric fractures, a high incidence of technique-related complications (pin migration, pin loosening, non-union, varus malunion, and infection) is found (28). External fixation in unstable fractures resulted in prolonged union time, increased incidence of the varus position of the fracture site, and worse functional outcome compared with stable fractures also reported in this study, and Petsatodis et al. (28) suggested that external fixators should be used with caution in the geriatric population in unstable pertrochanteric fractures. However, in our study, there were no cases of pin loosening, breakage, or penetration of the femoral head, and there was no any significant difference between the stable and unstable fractures according to the complications and functional–anatomical criteria of Foster. Only union time criteria was bad in the unstable cases compared with stable ones. Stable fractures (Evans–Jensen type 1) healed at approximately 4.1 months, whereas unstable fractures (Evans–Jensen types 2 and 3) healed at 5.9 months. Andruszkow et al. suggested the external fixation as an alternative to commonly applied implants in patients with multimorbid geriatric trauma (29).

The external fixation method is minimally invasive and fast. In elderly patients of high-risk (ASA 3 or 4) who have often comorbidities, stable fixation without surgical trauma could be vital for a faster recovery and mobilization and reduced morbidity and mortality (30).

CONCLUSION

In conclusion, the use of external fixation for the management of pertrochanteric fractures in elderly patients of poor health is a valuable and valid alternative surgical method.

Ethics Committee Approval: Ethics committee approval was received for this study from the ethics committee of Gaziantep University (Date: 2013/Decision no: 328).

Informed Consent: Written informed consent was obtained from all the patients who participated in the study.

Peer-review: Externally peer-reviewed.

Author Contributions: Concept – B.B.; Design – B.B., A.F.K.; Supervision – B.B.; Resources – A.F.K.; Materials – B.B.; Data Collection and/or Processing – B.B.; Analysis and/or Interpretation – A.F.K.; Literature Search – A.F.K.; Writing Manuscript – A.F.K.; Critical Review – B.B., A.F.K.

Conflict of Interest: The authors have no conflicts of interest to declare.

Financial Disclosure: The authors declared that this study has received no financial support.

REFERENCES

1. Gotfried Y, Frish E, Mendes DG, Roffman M. Intertrochanteric fractures in high risk geriatric patients treated by external fixation. *Orthopedics* 1985; 6: 769-74.
2. Kenzora JE, McCarthy RE, Lowell JD, Sledge CB. Hip fracture mortality: relation to age, treatment, preoperative illness, time of surgery and complications. *Clin Orthop Relat Res* 1984; 186: 45-56.
3. Akçali O, Kiter E, Kabaklıoğlu T, Araç Ş. The Leinbach hip prosthesis performed for hip fractures with impairment of femoral calcar. *Acta Orthop Traumatol Turc* 1998; 32: 116-9.
4. Baumgaertner MR. The pertrochanteric external fixator reduced pain, hospital stay, and mechanical complications in comparison with the sliding hip screw. *J Bone Joint Surg Am* 2002; 84: 1488.
5. Jensen JS, Michaelsen M. Trochanteric femoral fractures treated with McLaughlin osteosynthesis. *Acta Orthop Scand* 1975; 46: 795-9.
6. Foster JC. Trochanteric fractures of the femur treated by the Vitallium McLaughlin nail and plate. *J Bone Joint Surg* 1958; 40: 684-93.
7. Koval K, Zuckerman J. Intertrochanteric Fractures. Court-Brown C, Heckman JD, McKee M, McQueen MM, Ricci W, Tornetta 3rd P, editors. *Rockwood and Green's Fractures in Adults*. Philadelphia: Lippincott Williams & Wilkins; 2001.p.1635-63.
8. Wiles MD, Moran CG, Sahota O, Moppett IK. Nottingham Hip Fracture Score as a predictor of one year mortality in patients undergoing surgical repair of fractured neck of femur. *Br J Anaesth* 2011; 106: 501-4.
9. Parker M, Johansen A. Hip fracture. *BMJ* 2006; 333: 27-30.
10. Maxwell MJ, Moran CG, Moppett IK. Development and validation of a preoperative scoring system to predict 30 day mortality in patients undergoing hip fracture surgery. *Br J Anaesth* 2008; 101: 511-7.
11. Hu F, Jiang C, Shen J, Tang P, Wang Y. Preoperative predictors for mortality following hip fracture surgery: a systematic review and meta-analysis. *Injury* 2012; 43: 676-85.
12. Moran CG, Wenn RT, Sikand M, Taylor AM. Early mortality after hip fracture: Is delay before surgery important? *J Bone Joint Surg* 2005; 87: 483-9.
13. Orench M, Martín C, Pablo M. Patient care to prevent traction table complications. The case of proximal femur fracture. A pilot study. *Int J Adv Joint Reconstr* 2014; 1: 13-6.
14. Kummer FJ, Olsson O, Pearlman CA, Ceder L, Larsson S, Koval KJ. Intramedullary versus extramedullary fixation of subtrochanteric fractures. A biomechanical study. *Acta Orthop Scand* 1998; 69: 580-4.
15. Wolfgang GL, Bryant MH, O'Neill JP. Treatment of intertrochanteric fracture of the femur using sliding screw plate fixation. *Clin Orthop Relat Res* 1982; 163: 148-58.
16. Simpson AH, Varty K, Dodd CA. Sliding hip screws: modes of failure. *Injury* 1989; 20: 227-31.
17. Mavrogenis AF, Panagopoulos GN, Megaloikonomos PD, Igoumenou VG, Galanopoulos I, Vottis CT, et al. Complications After Hip Nailing for Fractures. *Orthopedics* 2016; 39:e108-16.
18. Alegre-López J, Cordero-Guevara J, Alonso-Valdivielso JL, Fernández-Melón J. Factors associated with mortality and functional disability after hip fracture: an inception cohort study. *Osteoporos Int* 2005; 16: 729-36.
19. Parker MJ, Das A. Extramedullary fixation implants and external fixators for extracapsular hip fractures in adults. *Cochrane Database Syst Rev* 2013; 2: CD000339.
20. Dhal A, Varghese M, Bhasin VB. External fixation of intertrochanteric fractures of the femur. *J Bone Joint Surg Br* 1991; 73: 955-8.
21. Davis TR, Sher JL, Horsman A, Simpson M, Porter BB, Checketts RG. Intertrochanteric femoral fractures. Mechanical failure after internal fixation. *J Bone Joint Surg Br* 1990; 72: 26-31.
22. Leung KS, So WS, Shen WY, Hui PW. Gamma nails and dynamic hip screws for pertrochanteric fractures. A randomised prospective study in elderly patients. *J Bone Joint Surg Br* 1992; 74: 345-51.

23. Scarante S, Ranelluci M, Lavini F. The Dynamic Axial Fixator in the treatment of pertrochanteric fractures of the femur. *Int J Orthop Traum* 1993; 3: 58-60.
24. Dhal A, Singh SS. Biological fixation of subtrochanteric fractures by external fixation. *Injury* 1996; 27: 723-31.
25. Vossinakis IC, Badras LS. The external fixator compared with the sliding hip screw for pertrochanteric fractures of the femur. *J Bone Joint Surg Br* 2002; 84: 23-9.
26. Moroni A, Faldini C, Pegreff F, Hoang-Kim A, Vannini F, Giannini S. Dynamic hip screw compared with external fixation for treatment of osteoporotic pertrochanteric fractures. A prospective, randomized study. *J Bone Joint Surg Am* 2005; 87: 753-9.
27. Diaz Jimenez M, Martin Galera R. Complex fractures of the upper third of the femur treated with external fixation, Ender nailing, blade plate and locked intramedullary nailing: a retrospective comparative study. *Int J Orthop Traum* 1993; 3: 69-71.
28. Petsatodis G, Maliogas G, Karikis J, Christodoulou AG, Venetsanakis G, Sachinis N, et al. External fixation for stable and unstable intertrochanteric fractures in patients older than 75 years of age: a prospective comparative study. *J Orthop Trauma* 2011; 25: 218-23.
29. Andruszkow H, Pfeifer R, Horst K, Hildebrand F, Pape H-C. External fixation in the elderly, *Injury* 2015; 46(Suppl 3): S7–S12.
30. Vossinakis IC, Badras LS. Management of pertrochanteric fractures in high-risk patients with an external fixation. *Int Orthop* 2001; 25: 219-22.

How to cite:

Bozgeyik B, Kekeç AF. Is External Fixation Valid Option for Pertrochanteric Fractures in High-Risk Patients? *Eur J Ther* 2018; 24(4): 204–9.