






# Effects of IVIG and Pulse Steroid Therapy in a Case of Allopurinol Induced DRESS Syndrome

Selma Korkmaz<sup>1</sup> , Elif Günay<sup>2</sup> , Nuray Can<sup>3</sup> , Sezin Fıçıcıoğlu<sup>4</sup> , Süleyman Pişkin<sup>4</sup> 

<sup>1</sup>Department of Dermatology, Süleyman Demirel University, School of Medicine, Isparta, Turkey

<sup>2</sup>Clinic of Dermatology, Kaçkar State Hospital, Rize, Turkey

<sup>3</sup>Department of Pathology, Trakya University, School of Medicine, Edirne, Turkey

<sup>4</sup>Department of Dermatology, Trakya University, School of Medicine, Edirne, Turkey

## ABSTRACT

Drug Reaction with Eosinophilia and Systemic Symptoms (DRESS) is a drug reaction that causes peripheral eosinophilia and primarily renal and hepatic insufficiency and dysfunction of other visceral organs with skin rash as noticeable symptom. Early diagnosis and discontinuation of the culprit drug along with rapid treatment are required to reduce mortality rate. Herein, a case of allopurinol-induced DRESS syndrome is presented in which the patient was resistant to medium dose systemic steroid therapy and was treated with pulse steroid and IVIG treatment successfully. Pulse steroid therapy may be an alternative treatment option in refractory DRESS syndrome.

**Keywords:** DRESS syndrome, allopurinol, pulse steroid

## INTRODUCTION

“Drug Reaction with Eosinophilia and Systemic Symptoms” (DRESS) is a drug reaction that causes peripheral eosinophilia and primarily renal and hepatic insufficiency and dysfunction of other visceral organs with skin rash as noticeable symptom. Miscellaneous drugs such as anticonvulsants, sulphonamids, dapson, allopurinol, minocycline, fluoroquinolone, and gold salts may cause this reaction. The symptoms are initial fever manifestation, skin rash, lymphadenomegaly, lymphocytosis, and eosinophilia, which emerge within in 2–8 weeks after the therapy (1-3). The other symptoms include primarily hepatic, renal, cardiac, and pulmonary failure. The mortality rate of the disease is higher than 10%, which is usually caused due to hepatic failure. Skin findings vary from maculopapular rash to erythroderma.

Rash, fever, and visceral organ failure are the major manifestations of the disease, which can also be seen primarily in infections and many other diseases. The early and accurate differential diagnosis of DRESS syndrome is important because of organ failures and skin symptoms (4). Although allopurinol-induced DRESS syndrome generally responds to corticosteroid therapy, there could be some cases resistant to steroid. Herein, a case of allopurinol-induced DRESS syndrome is presented in which the patient was resistant to steroid therapy but responded to IVIG and pulse steroid treatment, as given in the literature.

## CASE PRESENTATION

A 45-year-old woman with extended skin rashes on the body surface and fever was admitted to our clinic. Her body temperature and blood pressure were 39°C and 120/80 mmHg, respectively. She had edema and maculopapular rash on face, erythematous maculopapular and locally targetoid rash on neck and trunk, membranous secretion on conjunctiva, superficial ulcerations on oral mucosal surfaces, and fissures and hemorrhagic crusts on lips (Figure 1). There were locally targetoid and consolidated erythematous macular rash on forearms, legs, and back. There was no lesion on palmoplantar regions. Her medical history included bipolar affective disorder for 28 years, type 2 diabetes mellitus for 15 years, and chronic renal insufficiency for 6 months; she had been consuming lithium and oral antidiabetic drugs for these diseases. Additionally, she started allopurinol dosage of 300 mg/day 15 days ago.

Eosinophilia, thrombocytopenia, increase in hepatic transaminases and renal function parameters, and inflammatory markers (erythrocyte sedimentation rate and C-reactive protein) were also observed. No infectious focus relating to fever could be determined. Viral markers such as anti-HCV, HBSAg, anti-Hep B IgM, anti-CMV IgM, and anti EBV IgM were negative. The blood and urine cultures were also negative. Superficial ultrasound examination revealed 2 cm size lymph nodes in both axillary and inguinal regions. Her echocardiography and electrocardiogram were normal. The histological view of punch

**ORCID IDs of the authors:** S.K. 0000-0003-3877-3976; E.G. 0000-0002-9943-0355; N.C. 0000-0003-2554-6432; S.F. 0000-0002-7934-3633; S.P. 0000-0002-0999-2267.

This case was presented as a poster at the congress of Aegean Dermatology Days in 2015 (5–10 May 2015, Fethiye, Turkey).

**Corresponding Author:** Selma Korkmaz **E-mail:** selmakorkmaz35@gmail.com

**Received:** 15.10.2017 • **Accepted:** 11.05.2018

©Copyright by 2018 Gaziantep University School of Medicine – Available online at [www.eurjther.com](http://www.eurjther.com)

biopsy revealed patterns of interphase reaction, including lymphocyte egzocytosis, basal liquefactive changes, epidermal necrosis indicating Steven–Johnsons syndrome/toxic epidermal necrosis, and dermal perivascular inflammation composed of lymphocytes, histiocytes, and eosinophil leukocytes (Figure 2a, b).

The patient was diagnosed with allopurinol-induced DRESS syndrome in accordance with these clinical and histopathological findings, so the use of allopurinol was stopped immediately. 1 mg/kg/day methylprednisolone therapy was started. She responded for the first 5 days but then her general state deteriorated leading to increased fever, tachycardia, tachypnea, and hypotension. No infectious symptoms were found to explain this

condition. It was assumed to be due to steroid resistance, and we gave intravenous immunoglobulin 0.5 mg/kg/day for 3 days together with 500 mg pulse methylprednisolone twice a day. On the second day of treatment, her general state was stabilized, the fever reduced, respiration became normal, and urine excretion was increased in addition to amelioration in hepatic and renal function parameters. On the third day of therapy, steroid dose was decreased to 1 mg/kg/day. After skin lesions dissolved, methylprednisolone dose was reduced and then stopped within 3 weeks. Her skin rash totally disappeared with fine desquamation on follow-up visits (Figure 3). Written informed consent was taken from the patient. No relapse was observed on follow-ups.

**DISCUSSION**

Drug Reaction with Eosinophilia and Systemic Symptoms syndrome is an acute and severe drug reaction presented with fever, systemic symptoms, marked eosinophilia, and commonly maculopapular skin rashes with a wide range of clinical presentation varying from toxic epidermal necrolysis, erytyma multiforme, exfoliative dermatitis to erythroderma (1, 2). This condition develops within 2–6 weeks after starting the drug. It has 8–10% mortality ratio. The most initial finding is persistent fever. Facial edema and maculopapular skin rashes start from trunk and expand to face, and extremities are seen in 90% of the cases. In this case, there was fever resistant to antibiotics along with widely erytematous maculopapular polymorphous skin rash similar to the cases in other literature. DRESS syndrome affects many visceral organs, primarily liver and kidney. Mild increase in transaminases and haematological abnormalities such as eosinophilia and atypical lymphocytes are shown in half of the cases (4, 5). In our case, increase in transaminases and eosinophilia is observed too but no atypical lymphocytes were seen in peripheral blood.

The most frequently responsible agents in DRESS syndrome are aromatic anticonvulsants (e.g., carbamazepine), allopurinol, sulfonamides, minocycline, other antibiotics, antiretroviral agents, and dapsone (1, 2, 4). Allopurinol-induced DRESS syndrome occurs more frequently in older patients with renal dysfunction. It is

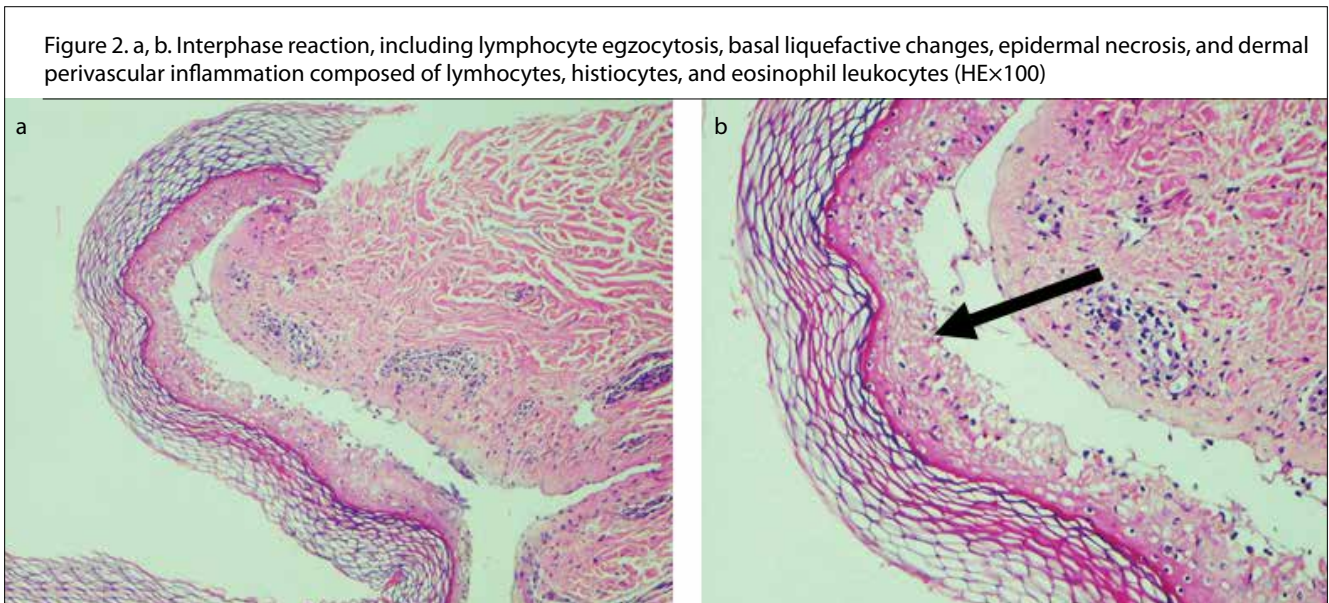
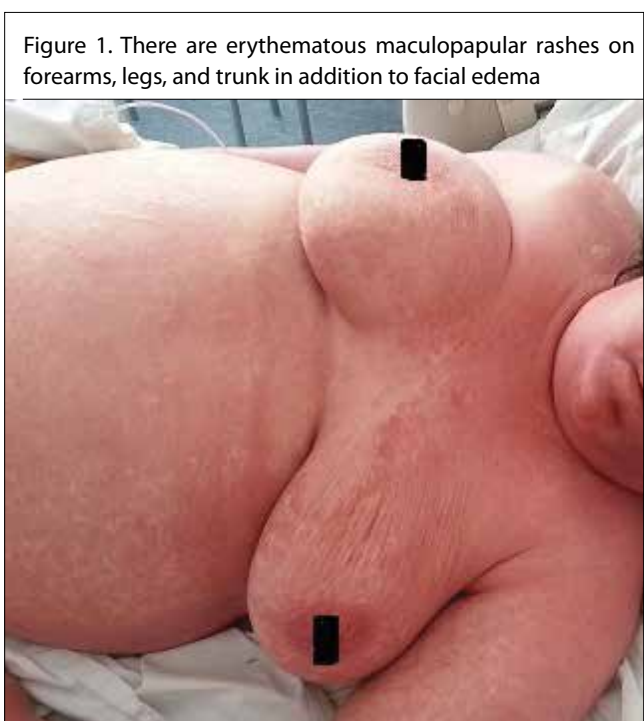
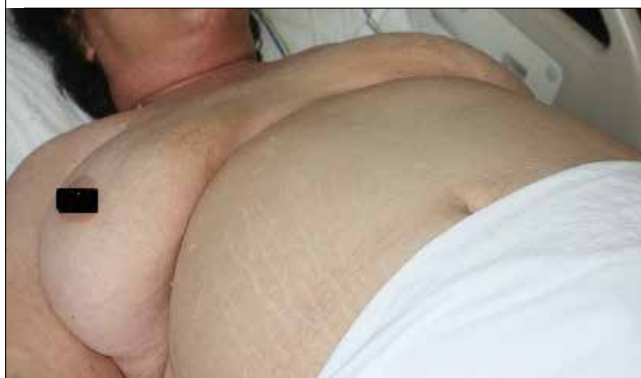

Figure 3. Skin rash disappeared totally after therapy



suggested that in allopurinol-induced DRESS syndrome oxypurinol, a metabolite of allopurinol, is less excreted so it accumulates, then stimulates CD4 (+) and CD8 (+) T lymphocytes, and then increases interleukin 5 which triggers the inflammatory cascade stimulating eosinophils and therefore initiating tissue damage (6, 7). In this case, chronic renal insufficiency might have facilitated the development of allopurinol toxicity. Singer and Wallace had established Allopurinol Hypersensitivity Syndrome criteria for evaluating allopurinol-related reactions (8). In this case, in addition to the first two criteria, all of last criteria were positive.

Drug Reaction with Eosinophilia and Systemic Symptoms syndrome could mimic several disorders because of the involvement of various organs; therefore, it could be diagnosed solely by excluding many clinical entities. A standard scoring system was assessed with the study RegiSCAR, which was a polycentral study, to build a consensus on diagnosis. With this scoring system, cases can be classified as “definite DRESS, highly probable, probable DRESS, and no DRESS” (1).

In DRESS syndrome, liver and lymph node involvements are reported more frequently than cardiac and pulmonary involvements (2). In this case, hepatic, renal, and haematological involvements were determined.

It is reported that reactivation of Epstein-Barr Virus, HHV-6, HHV-8, and CMV might frequently worsen this condition, and the syndrome could be intensified with viral replication (1, 2, 4, 5, 8). However, the viral markers were negative in our case.

The initial approach on DRESS syndrome should be to stop the use of the culprit drug. It is suggested to continue systemic corticotherapy for 6–8 weeks to treat skin and visceral infections and to prevent the relapses. IVIG, plasmapheresis, rituximab, and valgancyclovir are recommended in the cases resistant to corticosteroid therapy (8-10). It is shown that IVIG therapy could be useful in DRESS syndrome triggered by anticonvulsants (11, 12). To the best of our knowledge, usage of IVIG therapy in allopurinol-induced DRESS syndrome has not been reported in the literature yet. In this case, because of the resistance to steroid therapy, 0.5 mg/kg/day IVIG therapy was given for 3 days and 500 mg/day pulse methylprednisolone for 2 days. From the second day of this regimen, clinical and laboratory findings were ameliorated rapidly.

## CONCLUSION

As the result, the first step of the therapy for allopurinol-induced DRESS syndrome is discontinuing the use of allopurinol and starting systemic corticosteroid therapy. Nevertheless in cases resistant to these implications, we suggest that pulse steroid and IVIG could be an alternative treatment option.

**Informed Consent:** Written informed consent for photography and publishing was obtained from patient.

**Peer-review:** Externally peer-reviewed.

**Author Contributions:** Concept – S.K.; Design – S.K., N.C.; Data Collection and/or Processing – E.G.; Analysis and/or Interpretation – S.K., E.G., S.F., S.P.; Writing Manuscript – S.K.; Critical Review – S.F.

**Conflict of Interest:** The authors have no conflicts of interest to declare.

**Financial Disclosure:** The authors declared that this study has received no financial support.

## REFERENCES

1. Kardaun SH, Sekula P, Valeyrie -Allanore L, Liss Y, Chu CY, Creamer D, et al. RegiSCAR study group. Drug reaction with eosinophilia and systemic symptoms (DRESS): an original multisystem adverse drug reaction. Results from the prospective RegiSCAR study. *Br J Dermatol* 2013; 169: 1071-80.
2. Bakkal SU, Tufan ZK, Bulut C, Boyraz S, Vahaboğlu G. A case of DRESS Syndrome mimicking Sepsis. *Klimik Derg* 2011; 24: 132-4.
3. Alkhateeb H, Said S, Cooper CJ, Gaur S, Porres-Aguilar M. DRESS syndrome following ciprofloxacin exposure: An unusual association. *Am J Case Rep* 2013; 4: 526-8.
4. Emre S, Akoğlu G, Metin A, Demirseren DD, Kurtoğlu G. Evaluation of clinical features of 11 cases with DRESS syndrome. *Turkderm* 2013; 47: 218-22.
5. Cacoub P, Musette P, Descamps V, Meyer O, Speirs C, Finzi L, Roujeau JC. The DRESS syndrome: a literature review. *Am J Med* 2011; 124: 588-97.
6. Erturan I, Başak PY. A case of Allopurinol Induced Dress Syndrome. *Turk J Dermatol* 2013; 7: 100-2.
7. Guleria VS, Dhillon M, Gill S, Naithani NJ. Res Pharm Pract. Ceftriaxone induced drug rash with eosinophilia and systemic symptoms. 2014; 3: 72-4.
8. Singer JZ, Wallace SL. The allopurinol hypersensitivity syndrome. Unnecessary morbidity and mortality. *Arthritis Rheum* 1986;29:82-7.
9. Fernando SL. Drug-reaction eosinophilia and systemic symptoms and drug-induced hypersensitivity syndrome. *Australas J Dermatol* 2014; 55: 15-23.
10. Kito Y, Ito T, Tokura Y, Hashizume H. High-dose intravenous immunoglobulin monotherapy for drug-induced hypersensitivity syndrome. *Acta Derm Venereol* 2012; 92: 100-1.
11. Santhamoorthy P, Alexander KJ, Alshubaili A. Intravenous immunoglobulin in the treatment of drug rash eosinophilia and systemic symptoms caused by phenytoin. *Ann Indian Acad Neurol* 2012; 15: 320-2.
12. Dredge DC, Parsons EC, Carter LP, Staley KJ. Anticonvulsant hypersensitivity syndrome treated with intravenous immunoglobulin. *Pediatr Neurol* 2010; 43: 65-9.
13. Comfere NI, Sartori-Valinotti JC, Bruce AJ, Drage LA. Successful treatment of lamotrigine-associated drug hypersensitivity syndrome with intravenous IgG. *J Am Acad Dermatol* 2012; 66: 249-50

### How to cite:

Korkmaz S, Günay E, Can N, Fıçıcıoğlu S, Pişkin S. Effects of IVIG and pulse steroid therapy in a case of allopurinol induced DRESS syndrome. *Eur J Ther* 2018; 24(3): 182–4.