

Hypo-Hyperdontia Associated with Mandibular Mesiodens and Double Mandibular Mesiodens: Two Rare Cases

Sema Kaya¹ , Yasemin Tunca² , Murat Tunca³ 

¹ Department of Oral and Maxillofacial Radiology, Faculty of Dentistry, Van Yuzuncu Yıl University, Van, Türkiye

² Department of Orthodontics, Faculty of Dentistry, Kütahya Health Sciences University, Kütahya, Türkiye

³ Department of Orthodontics, Faculty of Dentistry, Kütahya Health Sciences University, Kütahya, Türkiye

Received: 2024-05-08

Accepted: 2024-06-09

Published Online: 2024-06-28

Corresponding Author

Murat Tunca, MD.

Address: Discipline of Orthodontics,
Faculty of Dentistry, Kütahya Health
Sciences University, Kütahya, Türkiye

E-mail(s): dtmurattunca@gmail.com

Dear Editor,

I am writing this article with two cases to provide information about a rare dental anomaly. Hyperdontia refers to the presence of additional teeth in the mandible or maxilla. Hyperdontia can be found in deciduous or permanent dentition and may be unilateral or bilateral. In a recent study conducted in the Turkish population, the prevalence of hyperdontia was 7.8% [1]. Although the etiology of hyperdontia is not clear, increased dental lamina activity is thought to cause this condition [1]. Hyperdontia is twice as common in males as in females [2].

In terms of morphology, supernumerary teeth may be conical, tuberculate, or molar shaped. Supernumerary teeth are named according to the region where they are located, with those found between the central teeth called mesiodens and those found in the wisdom tooth region called paramolars or distomolars [3]. The most common tooth types in hyperdontia are mesiodens, maxillary lateral incisors, maxillary distomolars or paramolars, and supplemental premolars in the mandibular premolar region [4]. In approximately 90–98% of cases, hyperdontia affects the maxilla, mostly in the anterior region [5]. In the anterior region of the mandible, the incidence of supernumerary teeth is just 0.01% [6]. In addition to causing crowding in the dental arch [6], hyperdontia can interfere with tooth eruption and cause malpositions [7].

Hypodontia, also known as selective tooth agenesis or congenital tooth absence, is the developmental absence of at least one permanent tooth and is a common dental anomaly in man [8].

Concomitant hypo-hyperdontia (CHH) refers to hyperdontia and hypodontia [9]. The reported incidence of CHH in orthodontic patients is 0.7% [10].



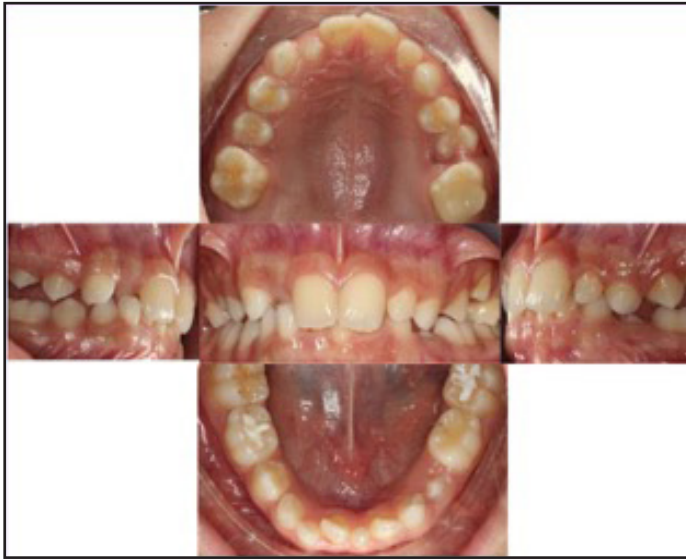

Figure 1. Intraoral photos of case 1

Patient 1

A male patient presented to our clinic with orthodontic problems. The chronological age of the patient was 12 years and 3 months, and the patient's bone age was 13 years and 6 months. Routine extraoral and intraoral examinations were performed, in addition to radiological examinations. Extraorally, the patient was observed to have a flat profile. The intraoral examination of the patient, who was in the late opposition period, revealed an overjet of 3 mm, an overbite of 5 mm, and a crossbite of tooth number 12. Tooth 26 had deep dentin caries with large loss of material and a conical-shaped tooth between the mandibular permanent central teeth compatible with mesiodens, which is very rare in the mandible (Figure 1). The radiological examinations revealed that tooth numbers 25 and 43 were ectopically positioned, the tooth between the mandibular central teeth was a mesiodens with complete root development, and the mandibular lateral teeth were congenitally missing. Cephalometric radiography analysis revealed a skeletal class III (SNA: 73°, SNB: 74°, ANB: -1°) malocclusion (Figure 2).

Congenitally deficiency of mandibular lateral teeth and an additional tooth in the mandibular central tooth area is a very rare presentation. Our patient provides an example of both a very rare case of mandibular mesiodens and a case of hypo-hyperdontia (Figure 2). A follow-up visit to the orthodontic clinic 3 months later was scheduled to evaluate the direction of eruption of the ectopic teeth and the crossbite of tooth number 12 with mesiodens and bilateral tooth deficiency.

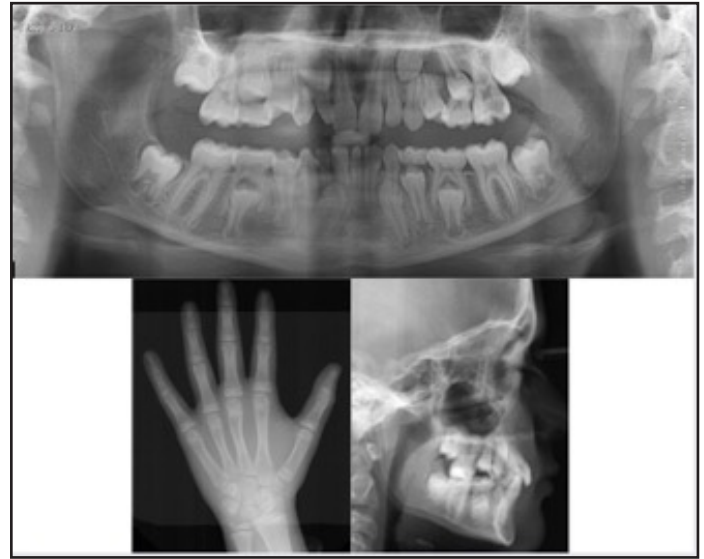

Figure 2. Panoramic radiograph , cephalometric radiograph and hand-wrist radiograph of case 1

Patient 2

An 18-year-old female patient who presented to our clinic with severe toothache in her mandible was examined extraorally, intraorally, and radiologically. The extraoral examination revealed a convex profile. The intraoral examination revealed deep dentin caries in the region of tooth number 37, which caused excessive loss of material on the occlusal surface. This tooth was the source of the patient's severe pain. Overjet was -1 mm, and overbite was -1 mm. Tooth numbers 46 and 36 were missing, and there were two extra teeth in the mandibular anterior region, one of which was more conical in shape than the other (Figure 3). The radiological examination revealed that tooth number 46 had been recently extracted and that tooth number 36 had been extracted a long time ago (Figure 4). The two extra teeth in the mandibular anterior region were double mesiodens that had completed their development. Mandibular mesiodens are very rare, and double mandibular mesiodens are even rarer. Cephalometric radiography analysis revealed a skeletal class I (SNA: 83°, SNB 82°, ANB: 1°) malocclusion (Figure 4). The patient was referred to an orthodontic clinic because of a bite problem due to the excess teeth in the anterior region.

Additional informed consent was obtained from all patients for which identifying information is included in this article. Considering the etiology of tooth number and size anomalies, it has been suggested that developmental dental anomalies such as hypodontia result from a complex set of interactions involving genetic, epigenetic and environmental factors [11] A family

study on hypodontia in Sayada, Tunisia showed that congenitally deficient teeth are probably inherited as an autosomal dominant trait [12]. In the first case, the patient's mother was also found to have a similar deficiency of teeth.

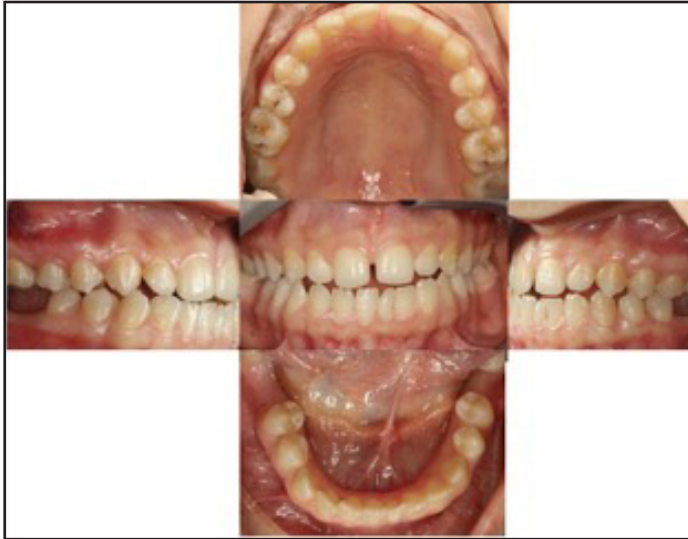

Figure 3. Intraoral photos of case 2

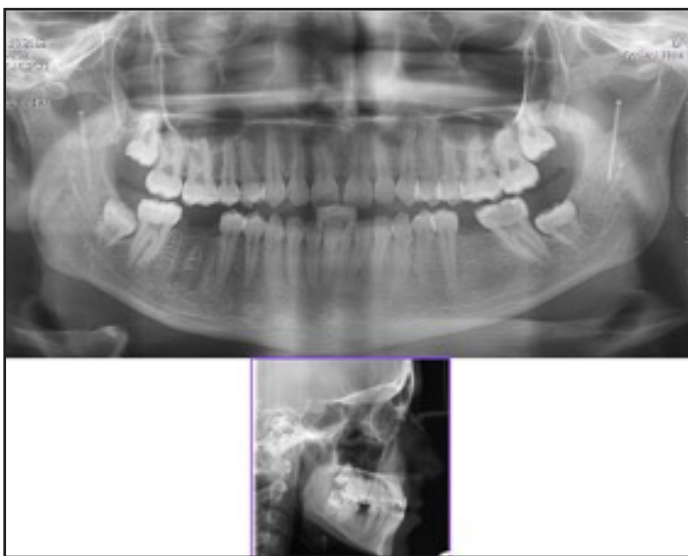


Figure 4. Panoramic radiograph and cephalometric radiograph of case 2

Previous research reported that the incidence of supernumerary teeth during permanent dentition is twice as high in males as in females. These permanent teeth are mostly mesiodens in the maxillary region [2]. In the literature, reports of mesiodens in the anterior region of the mandible are rare. There are cases of hypo-hyperdontia with mandibular mesiodens associated with the absence of permanent mandibular central teeth [13]. The finding

of hypo-hyperdontia with congenitally missing mandibular lateral teeth and mandibular mesiodens in the present case report (Patient 1) is similar to that reported in the literature [13]. In accordance with the literature [13], the patient in our case was male. Tooth number anomalies, such as hyperdontia-hypodontia, not only affect the aesthetic appearance but also cause problems in arch length and occlusion in the jaw [14].

Tanaka et al. described the case of a female patient with erupted double mandibular mesiodens similar to that seen in our patient (Patient 2) [15]. In other cases of mandibular mesiodens, fusion of some teeth with the surrounding teeth has been found [16]. Fusion was not encountered in either of our cases. Mesiodens can cause displacement of adjacent permanent teeth [17].

Panoramic radiographs are very useful in the radiological diagnosis of the eruptive teeth such as mesiodens, but in some cases the superposition of the cervical vertebrae in the anterior region does not allow a clear evaluation of this region. In these cases, periapical radiographs will be very effective in making the diagnosis [18]. It should not be forgotten that there may be similar rare conditions in tooth deficiencies. In addition, diagnosed individuals should be consulted between disciplines for preventive or therapeutic treatments.

Yours sincerely,

REFERENCES

1. Anegundi RT, Tegginmani VS, Battepati P, et al (2014) Prevalence and characteristics of supernumerary teeth in a non-syndromic South Indian pediatric population. *J Indian Soc Pedod Prev Dent* 32:9–12. <https://doi.org/10.4103/0970-4388.12704>
2. Brook AH (1984) A unifying aetiological explanation for anomalies of human tooth number and size. *Arch Oral Biol* 29:373–378. [https://doi.org/10.1016/0003-9969\(84\)90163-8](https://doi.org/10.1016/0003-9969(84)90163-8)
3. Hattab FN, Yassin OM, Rawashdeh MA (1994) Supernumerary teeth: report of three cases and review of the literature. *ASDC J Dent Child* 61:382–393.
4. Stafne, E.C (1932) Supernumerary teeth. *Dent. Cosmos* 74:653-659.

6. Garvey MT, Barry HJ, Blake M (1999) Supernumerary teeth--an overview of classification, diagnosis and management. *J Can Dent Assoc* 65:612–616.
7. Mitchell L, Bennett TG (1992) Supernumerary teeth causing delayed eruption--a retrospective study. *Br J Orthod* 19:41–46. <https://doi.org/10.1179/bjo.19.1.41>
8. Khalaf K, Miskelly J, Voge E, Macfarlane TV (2014) Prevalence of hypodontia and associated factors: a systematic review and meta-analysis. *J Orthod* 41:299–316. <https://doi.org/10.1179/1465313314Y.0000000116>
9. Camilleri GE (1967) Concomitant hypodontia and hyperodontia. Case report. *Br Dent J* 123:338–339.
10. Gokkaya B, Kargul B (2016) Prevalence of concomitant hypo-hyperdontia in a group of Turkish orthodontic patients. *Eur Arch Paediatr Dent* 17:53–57. <https://doi.org/10.1007/s40368-015-0201-0>
11. Brook AH, Griffin RC, Smith RN, et al (2009) Tooth size patterns in patients with hypodontia and supernumerary teeth. *Arch Oral Biol* 54 Suppl 1:S63-70. <https://doi.org/10.1016/j.archoralbio.2008.05.016>
12. Maatouk F, Baaziz A, Ghnima S, et al (2008) Survey on hypodontia in Sayada, Tunisia. *Quintessence Int* 39:e115-120.
13. Nirmala SVSG, Sandeep C, Nuvvula S, Mallineni SK (2013) Mandibular hypo-hyperdontia: A report of three cases. *J Int Soc Prev Community Dent* 3:92–96. <https://doi.org/10.4103/2231-0762.122451>
14. Aglarci C, Nur BG, Aglarci OS, et al (2016) Prevalence and distribution of dental anomalies in a subpopulation of the west region of Turkey. 9:39–44.
15. Tanaka S, Murakami Y, Fukami M, et al (1998) A rare case of bilateral supernumerary teeth in the mandibular incisors. *Br Dent J* 185:386–388. <https://doi.org/10.1038/sj.bdj.4809822>
16. Rossi AC, Prado F, Henrique P, Caria F (2010) Anatomical variation in a Brazilian human mandible: case report of a supernumerary permanent lower incisor. *Int J Anat Var* 2010;3:151–2.
17. Karadas M, Celikoglu M, Akdag MS (2014) Evaluation of tooth number anomalies in a subpopulation of the North-East of Turkey. *Eur J Dent* 8:337–341. <https://doi.org/10.4103/1305-7456.137641>
18. Palanisamy V, Rao A, Ongole R, Chacko V (2017) Mandibular mesiodens—A rare case report. *Journal of Oral and Maxillofacial Surgery, Medicine, and Pathology* 29:163–165. <https://doi.org/10.1016/j.ajoms.2016.08.002>

How to Cite;

Kaya S, Tunca Y, Tunca M (2024) Hypo-Hyperdontia Associated with Mandibular Mesiodens and Double Mandibular Mesiodens: Two Rare Cases. *Eur J Ther.* 30(4):555-5559. <https://doi.org/10.58600/eurjther2183>