

Original Research

Variation of Wormian and Inca Bones in Adult Skulls

Hatice Güler^{1,*} , Hilal Kübra Güçlü Ekinci¹ , Burcu Kamaşak Arpaçay² 

¹Department of Anatomy, Erciyes University School of Medicine, Kayseri, Turkey

²Department of Anatomy, Kırşehir Ahi Evran University School of Medicine, Kırşehir, Turkey

Received: 2023-11-21 / Accepted: 2024-01-22 / Published Online: 2024-01-29

Correspondence

Hatice Güler, PhD

Address: Department of Anatomy,
Faculty of Medicine, Erciyes University,
Kayseri, Turkey

E-mail: hsusar@erciyes.edu.tr

ABSTRACT

Objective: Irregular and abnormal small additional bones called Wormian bones can be encountered between the skull bones. This study aimed to investigate the incidence, topographical distribution, morphology, and interrelationship of the Wormian and Inca bones in Central Anatolia Region dry adult skulls.

Methods: In the study, 119 adult skulls were examined. The location and frequency of additional bones (Wormian) in the sutures in the cranium were determined. Skulls with Inca bones were identified. The Inca bones were typified in accordance with the literature and their dimensions in the transverse and sagittal axis were measured with a digital caliper.

Results: Wormian bone was present in 33 of 119 adult skulls (27.7%). Of the 33 bones, 22 were detected in the male (66.66%) and 11 female (33.34%) skulls. The locations of the Wormian bones in the order of decreasing incidence were the lambdoid suture (16.0%, 19/119), pterion (16.0%, 19/119), lambda (7.6%, 9/119), asterion (2.5%, 3/119), and bregma (1.7%, 2/119). Nine Inca bones were found in the lambdoid region (27.3%, 9/33). Six of these bones (66.7%) were in the male skull. We found that two of these bones were incomplete lateral asymmetric, two were complete symmetric bipartite, two were incomplete asymmetric bipartite and three were incomplete median type. We found that 13 (10.9%) of the skulls in the study had metopic sutures and 0.8% had craniosynostosis. When the craniums with metopic suture were evaluated, it was found that 8 of them (61.5%) had additional bone. 50% of the Wormian bones were found in the lambdoid suture.

Conclusion: It has been found that the incidence of Wormian bone increases with suture variations. It was determined that the frequency of Inca bone variation may vary depending on regional differences.

Keywords: Morphometry, Inca Bone, Variation, Wormian Bone.



This work is licensed under a Creative
Commons Attribution-NonCommercial 4.0
International License.

INTRODUCTION

The skull consists of a total of 22 bones, eight in neurocranium and fourteen in viscerocranium. These bones join via cranial sutures [1, 2]. Wormian bones are a large number of irregular, accessory, and abnormal small suture bones located between the skull bones. It differs from person to person in size, shape, number, and thickness. These bones are named according to the fontanelles, the ossification center or the sutures they are in. Human anatomy, neurosurgery, physical anthropology, forensic medicine, craniofacial surgery and radiology are interested in Wormian bone [2, 3]. Anatomical knowledge of suture bones is clinically important because their presence is often used as a descriptive marker of some congenital disorders, particularly bony dysplasia [2].

Inca bone is one of the accessory bones in the cranium and is considered variant of normal [4, 5]. Inca bone is one of the developmental cranial variations with a striking feature; one or occasionally more isolated bones in the upper squama of the occipital bone. Inca bones can be divided by longitudinal sutures and can be bipartite, tripartite, or multipart [6-8].

The variability in Inca bone frequency has been studied in major human populations around the world. Inca bone has a definite anthropological value as an epigenetic trait in racial differentiation [9]. In contrast, the results of Tøgersen's genealogical research showed that the Inca bone is inherited in an autosomal dominant way, with 50% invasiveness [10]. The Deol and Truslove study found that the appearance of Inca bones in mice is subject to intense genetic control [11].

Morphometric and morphological features of Inca and Wormian bones are important to neurosurgeons, clinicians investigating child abuse, anthropologists, anatomists and forensic experts [12, 13]. Variations of the sutures and sutural bones can be

easily misdiagnosed with fractures of related bony regions in unconscious patients with multiple traumas. In case of trauma to the cranium, Wormian bones may be confused with skull fracture on X-rays, causing misdiagnosis and incorrect intervention [7, 14]. Inca bones can be used for personal identification in forensic medicine by comparing pre-mortem and post-mortem radiographs [8].

Although Wormian and Inca bones are quite common, they are poorly reported. In this study, it was aimed to investigate the Wormian and Inca bones variations in adult skulls living in Central Anatolia and to contribute them to the literature.

MATERIALS AND METHODS

In the research, 119 adult skulls were examined. Skulls were obtained from the bone collection at Erciyes University Faculty of Medicine in the Anatomy Laboratory. Skulls with damaged or deformed integrity were not included in the research. Detection of Wormian bones in the cranium and all other findings was done by a two-person team to avoid individual bias and two measurements were taken to reduce the error rate, and the average of these measurements was considered. As a result of the discussions, the bones were noted according to where they were found. The averages of the results were taken into account. Additionally, the lambdoid region was examined for Inca bones. The sex determination of the skulls with Wormian bone was performed using the method suggested by Buikstra and Ubelaker [15]. In addition, the distribution of these bones by sex was determined.

The detected Inca bones were classified and measured in two axes (sagittal-transverse). A digital caliper (Mitutoyo 200 mm Digital Caliper, Mitutoyo Co., Kanagawa, Japan) with 0.01 millimeter (mm) precision was used for measurements. The width and length of the Wormian bones detected at bregma and asterion points were also measured. The types of Inca bones were determined according to the work of Hanihara et al. [9]. In addition, all skulls were evaluated for metopic suture development.

Statistical Analysis

The data were tabulated in a Microsoft Excel worksheet and the analysis of the data was performed using SPSS 22.0 (IBM Corp., Armonk, NY) package program. The results of measurements are given as mean, standard deviation (SD), percentage of presence, and minimum and maximum values.

Main Points:

- Wormian bones were more common in skulls with metopic sutures.
- An increased incidence of Wormian bone has been found in suture variations. Half of the Wormian bones were located in the lambdoid suture.
- Inca bone variation was more common in male skulls.

RESULTS

Findings showing the localization of Wormian and Inca bones are included in Table 1. Morphometric measurements of Wormian bones in bregma and asterion are given in Table 2.

Data about the dimensions of the Inca bone (n=9) were obtained by measuring in transverse and sagittal axes found to be 27.46 ± 13.26 and 43.05 ± 25.72 mm, respectively. The detected Inca bones were typed in accordance with the literature. The findings are in Table 3 and **Figure 1**.

In addition to these, metopic sutures and craniosynostosis findings in the skulls were also evaluated. Thirteen (10.9%) metopic suture and one (0.8%) craniosynostosis were detected

in 119 skulls (Figure 2). When the craniums with metopic suture were evaluated, it was found that 8 of them (61.5%) had additional bone. It was observed that one of these bones (12.5%) was in the bregma, 1 (12.5%) was in the asterion, four of them were in the lambdoid suture, and two of them were in the lambdoid region (Figure 3).

Both Inca bones and other Wormian bones were more common in males than females (except the Bregma area). It was determined that the incidence of metopic suture was not related to sex. Inca bone was most common in the central region, and Wormian bones in the lambdoid suture were most common on the left. The distribution and localization of Wormian bones, Inca bones, and metopic suture by sex are shown in Table 4.

Table 1. Wormian bone and Inca bone distribution ratio in all bones examined

Wormian Bone Presence	Location	Number (n)	%
Present	Lambdoid suture	19	16.0
	Lambda (Inca bone)	9	7.6
	Bregma	2	1.7
	Asterion	3	2.5
	Total	33	27.7
Not	-	86	72.3
All examined bones		119	100.0

Table 2. Morphometric measurements of Wormian bones in bregma and asterion (mm)

Measurements	Bregma diameters		Asterion diameters			
	Transverse (n=2)	Sagittal (n=2)	Transverse (right) (n=3)	Sagittal (right) (n=3)	Transverse (left) (n=3)	Sagittal (left) (n=3)
	11.88 (4.69-19.08)	27.98±0.13	13.19±0.95	23.20 (9.64- 31.49)	13.42±0.57	22.90 (12.01-27.41)

Values are expressed as mean ± SD and the median (first-third quartiles).

Table 3. Distribution of variations of Inca bones

Type of Inca bone	Number (n)	%
Incomplete lateral asymmetric (Inca bone laterale dextrum)	2	22.22
Complete symmetric bipartite (Inca bone bipartitum)	2	22.22
Incomplete asymmetric bipartite (Inca bone duplex asymmetricum)	2	22.22
Incomplete median (Inca bone centrale (medianum))	3	33.34
Total	9	100




Figure 1. A. Incomplete lateral asymmetric, B. Complete symmetric bipartite, C. Incomplete asymmetric bipartite, D. Incomplete median

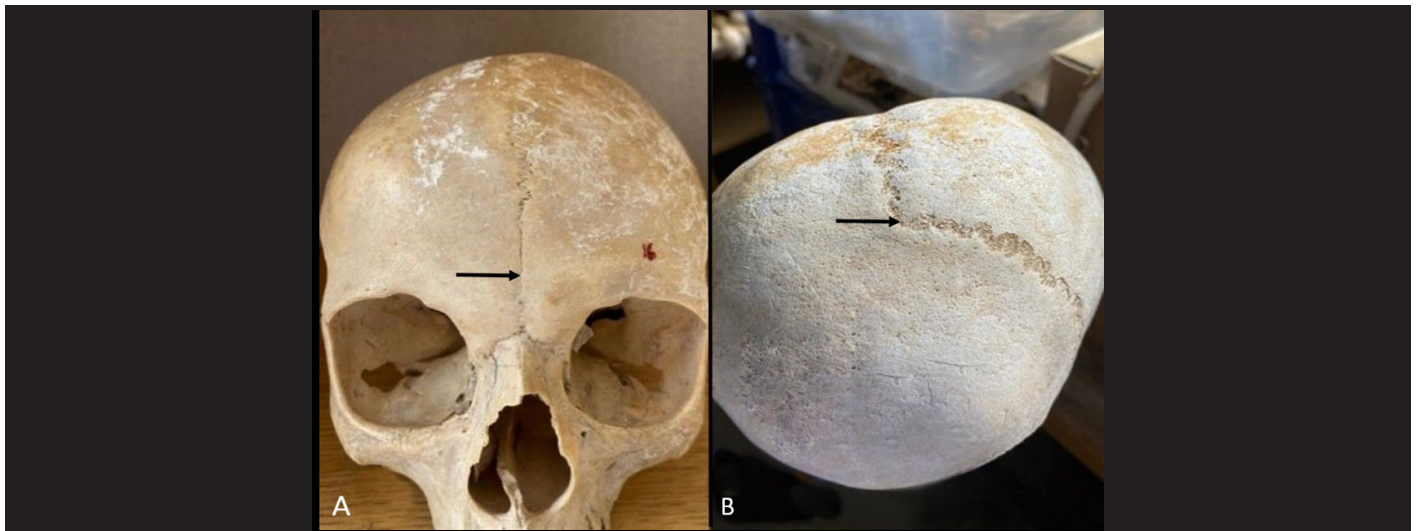


Figure 2. A. Metopic suture, B. Craniosynostosis

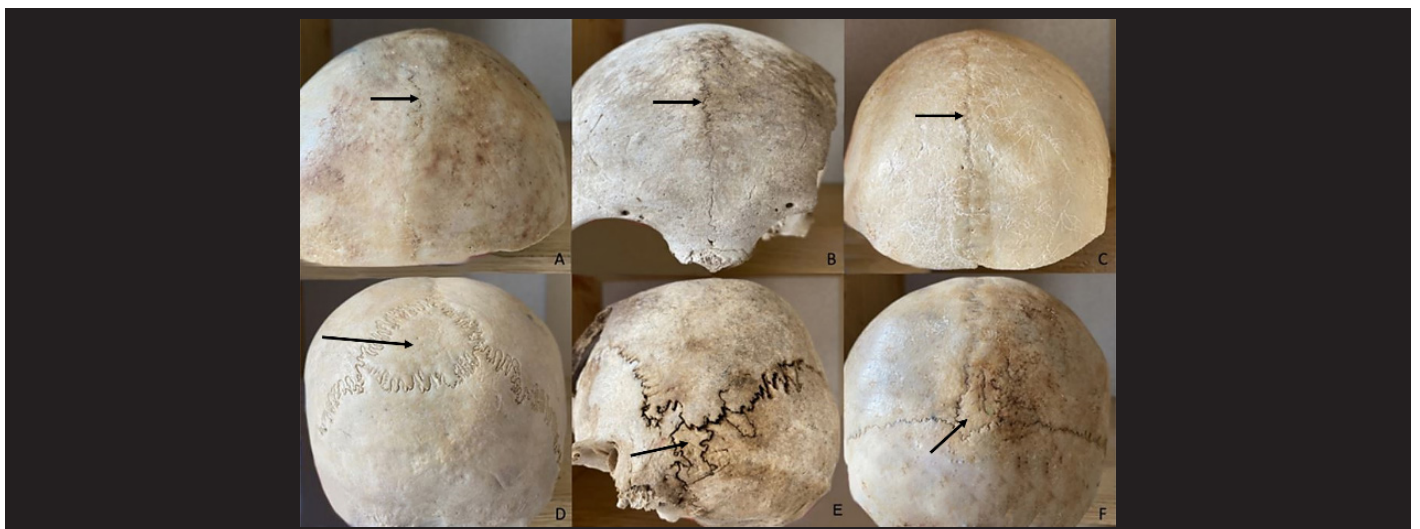

Figure 3. Wormian bones and Inca bones accompany the metopic suture skull. A, B, C: Front view of the cranium, D (Inca bone), E (Asterion), F (Bregma).

Table 4. Distribution of Wormian bones, Inca Bone and metopic suture by sex

		Metopic suture	Lambdoid suture	Inca Bone	Bregma	Asterion
Gender						
	Female	7 (53.8%)	7 (36.8%)	3 (33.3%)	1 (50%)	0 (0%)
	Male	6 (46.2%)	12 (63.2%)	6 (66.7%)	1 (50%)	3 (100%)
	Total	13 (100%)	19 (100%)	9 (100%)	2 (100%)	3 (100%)
Location						
	Centre		3 (15.8%)	4 (44.4%)	2 (100%)	0 (0%)
	Right and Left		5 (26.3%)	1 (11.1%)	0 (0%)	3 (100%)
	Right		4 (21.1%)	1 (11.1%)	0 (0%)	0 (0%)
	Left		7 (36.8%)	3 (33.3%)	0 (0%)	0 (0%)
	Total		19 (100%)	9 (100%)	0 (0%)	0 (0%)

DISCUSSION

In our study, we encountered both Wormian and Inca bones variations more frequently in males. We observed Wormian bone most frequently in the lambdoid suture, similar to the results of different studies in the literature.

Wormian bones can be used to identify bone diseases such as cleidocranial dysostosis, pycnodysostosis, congenital hypothyroidism, and Ricket's or may serve as a marker in the identification of central nervous system anomaly diseases [16-20]. Wormian bone variation varies in different ethnic groups [18]. The Inca bone is one of the developmental skull variations. The incidence of Inca bones varies geographically. In a recent worldwide study, it was higher than 10% in Northwest coastal and West African people, while the Australian samples were outliers by Pacific standards with frequencies of 1% or less [9]. The prevalence studies of Wormian and Inca bones in different ethnic groups are given in Table 5 [21-26].

Table 5. Prevalence of Wormian bone and “Inca bone” in different populations

Studies	Population	Wormian bone prevalence (%)	Inca bone prevalence (%)	Maximum Incidence of Wormian bones with respect to sutures in skull
Cirpan et al. 2015 [21]	Western Anatolian	59.3%	6.7%	40.7% (*)
Sreekanth et al. 2016 [26]	Indian	53.15% (59/111)	8.10%	53.15% (*)
Ghosh et al. 2017 [22]	Eastern Indian	45% (54/120)	21.21%	53.33% (*)
Vijay et al. 2017 [24]	South Indian	61.5% (123/200)	23.57%	91.05% (*)
Natsis et al. 2019 [23]	Greek	74.7% (124/166)	-	44.6% (*)
Şafak et al. 2020 [25]	Turkish	42.86% (12/28)	9.37%	62.5% (*)
Present study	Central Anatolian	27.7% (33/119)	7.6%	57.6 (*)

*Lambdoid suture

In the studies in the Table 5, it is seen that the prevalence of Wormian bone varies in different geographical regions. In addition, we have seen that the incidence of Wormian bones may vary among people living in different parts of Anatolia (Table 5). We can interpret this situation as regional differences changing the frequency of Wormian bone variation. Despite the differences in the prevalence of Wormian bones, we saw that the region where these bones were most dense did not change (lambdoid suture). The second and next most common localization of Wormian bones varies according to studies [21-24].

Studies in which morphometric measurements were made for Inca and Wormian bones have been rarely encountered. One of these studies was conducted by Ogut and Yildirim, and Wormian bones were detected in 58 of 110 bones [27]. The sagittal diameter of these bones was 18.24 ± 4.14 mm in females and 14.84 ± 9.41 mm in male, the transverse diameter was 13.24 ± 6.67 mm in females and 16.90 ± 16.33 mm in males. In our study, morphometric measurements of Wormian bones localized in bregma and asterion were made. While the transverse diameter of these bones located in bregma was lower, the transverse diameter of the Wormian bones located in the asterion was similar to Ogut and Yildirim's [27]. Additionally, sagittal diameter measurements were found to be higher in the bones in our study.

In our study, it is detected Inca bones in 9 (7.6%) of 119 cranium. Table 5 shows the prevalence of Inca bone at different rates in different studies. Changes in the number of samples, genetic structure and geographical factors may have caused the differences in study results.

Studies looking at the sexual dimorphism of Wormian and Inca bones have found different results in different populations. In the study by Donapudi and Vijayanirmala, it was revealed that the incidence of both Wormian and Inca bone in male skulls was higher than that of females (male, 3.4%; female, 1.2%) [7]. In the study of Carolineberry and Berry, one of the epigenetic studies in the human cranium, it was reported that the Inca bone was detected at a rate of 4.6% in men and 2.9% in women [28]. These studies are also consistent with our results.

There are studies of metopic sutures and the incidence of Wormian bone accompanying this suture. Guerram et al. [29] 4.1%, Aksu et al. [30] 7.5%, Çalışkan et al. [31] 8.1% reported that they detected the rate of metopic suture in their study. In our study, we found metopic sutures in 13 of all bones (10.9%). We think that regional differences may cause this result. In one study, metopic sutures were detected in 29 of 285 Chinese heads. 26 of the skulls with metopic sutures are also reported to have Wormian bone [32]. We found that 8 of the 13 skulls we detected metopic suture had Wormian bones. Both studies support an increased likelihood of Wormian bone in craniums with metopic sutures.

Wu et al. [33] found with craniosynostosis in the presence of an Inca bone in 11 of 245 patients in total. They reported that

the difference between the groups may be due to demographic or genetic differences. In our study, we did not detect cranial anomalies and Inca bone together. One of the 119 bones in our study had craniosynostosis. However, no additional bone was found in this bone.

O'Loughlin [34] showed that the incidence of Wormian bone increased in skulls with cranial deformation. In our study, no results compatible with these data were found.

During diagnostic or forensic identification, information on metopism, and craniosynostosis provides process-facilitating data. In addition, neurosurgeons should know Wormian bone in order not to harm during their interventions.

Limitations

The number of skulls used in the study was limited due to the removal of deformed ones.

CONCLUSIONS

We confirmed that the frequency of change in the skull of Wormian bones and Inca bones varies greatly. We concluded that Inca bones and Wormian bones are more common in males than females. In our study, we found Wormian bones (61.5%) in most of the 13 (10.9%) skulls with metopic suture. We found that the incidence of Wormian bone was increased in suture variations. In particular, clinicians need to be knowledgeable in order not to misinterpret suture bones as fractures. Therefore, we think that our study provides additional information to the literature on Wormian and Inca bones and will guide researchers dealing with sciences such as neurosurgery, radiology and anatomy in their practices.

Acknowledgments: The authors sincerely thank those who donated their bodies to science so that anatomical research could be performed.

Conflict of interest: The authors declare that they have no conflict of interest.

Funding: The authors declared that this study has received no financial support.

Ethical Approval: This study was conducted on cadaver, it is among the studies that do not require ethics committee approval.

Informed Consent: The skulls used as educational materials

were obtained from Erciyes University Faculty of Medicine Anatomy Laboratory.

Author Contributions: Conception: H.G.- Design: H.G., H.K.G.E., B.K.A.- Supervision: H.G. -Materials: H.G., H.K.G.E. - Data Collection and/or Processing: H.K.G.E., B.K.A. - Analysis and/or Interpretation: H.G., H.K.G.E., B.K.A. - Literature Review: H.G., H.K.G.E. - Writing: H.G., H.K.G.E., B.K.A. - Critical Review: B.K.A.

REFERENCES

- [1] Hauser G, De Stefano (1989) Epigenetic variants of the human skull. Stuttgart, Schweizerbart, Actas del XVII Congreso Internacional de Americanistas, Buenos Aires.
- [2] Reveron RR (2017) Anatomical classification of sutural bones. *MOJ Anat Physiol.* 3(4): 130-133. <https://doi.org/10.15406/mojap.2017.03.00101>.
- [3] Murlimanju BV, Prabhu LV, Ashraf CM, Kumar CG, Rai R, Maheshwari C (2011) Morphological and topographical study of Wormian bones in cadaver dry skulls. *J Morphol Sci.* 28 (3):176-179.
- [4] Jos Hemalatha GA, Arumugam K (2016) Study on the Occurrence of Wormian Bones in Human Adult Dry Skulls. *IJCMAAS.* 9 (3):126-128.
- [5] Marathe RR, Yogesh AS, Pandit SV, Joshi M, Trivedi GN (2010) Inca - interparietal bones in neurocranium of human skulls in central India. *J Neurosci Rural Pract.* 1(1):14-16. <https://doi.org/10.4103/0976-3147.63094>
- [6] Cirpan S, Aksu F, Mas N (2014) Inca Bone in Human Skulls of the West Anatolian Population. *Int J Morphol.* 32(1):275-278.
- [7] Donapudi A, Vijayanirmala B (2020) Incidence of Inca Bones among Dry Human Skull Bones: A Study in the Medical Colleges of a District in Southern India. *Int J Anat Radiol Surg.* 9 (3): AO01-AO03. <https://doi.org/10.7860/IJARS/2020/44196:2547>
- [8] Fujita MQ, Taniguchi M, Zhu BL, Quan L, Ishida K, Oritani S, Kano T, Kamikodai Y, Maeda H (2002) Inca bone in forensic autopsy: a report of two cases with a review of the literature. *Legal Medicine.* 4:197-201. [https://doi.org/10.1016/s1344-6223\(02\)00029-9](https://doi.org/10.1016/s1344-6223(02)00029-9)
- [9] Hanihara T, Ishida H (2001) Os incae: variation in frequency in major human population groups. *J Anat.* 198:137-152. <https://doi.org/10.1046/j.1469-7580.2001.19820137.x>.
- [10] Torgersen JH (1951) Hereditary factors in the sutural pattern of the skull. *Acta Radiol.* 36:374-382.
- [11] Deol MS, Truslove GM (1957) Genetical studies on the skeleton of the mouse XX. Maternal physiology and variation in the skeleton of C57 BL mice. *Journal of Genetics.* 55:288-312.
- [12] Christian WC, Committee on Child Abuse and Neglect (2015) The Evaluation of Suspected Child Physical Abuse. *Pediatrics.* 135 (5):e1337-e1354. <https://doi.org/10.1542/peds.2015-0356>.
- [13] Johal J, Iwanaga J, Loukas M, Tubbs RS (2017) Anterior Fontanelle Wormian Bone/ Fontanellar Bone: A Review of this Rare Anomaly with Case Illustration. *Cureus* 9 (7):e1443. <https://doi.org/10.7759/cureus.1443>.
- [14] Albay S, Sakallı B, Yonguç GN, Kastomoni Y, Edizer M (2013) Incidence and Morphometry of Sutural Bones [Ossa suturalia bulunma sıklığı ve morfometrisi]. *SDÜ Tıp Fak Derg* 20(1):1-7 ([In Turkish]).
- [15] Buikstra JE, Ubelaker DH (1994) Standards for Data Collection From Human Skeletal Remains. Fayetteville, Arkansas, Archeological Survey Research. 44.
- [16] Bellary SS, Steinberg A, Mirzayan N, Shirak M, Tubbs RS, Cohen-Gadol AA, Loukas M (2013) Wormian Bones: A Review. *Clin Anat.* 26: 922-927. <https://doi.org/10.1002/ca.22262>
- [17] Himabindu A, Narasinga R (2015) An Insight Into Wormian Bones. *IJSRES.* 2 (6):26-28.
- [18] Jeanty P, Silva SR, Turner C (2000) Prenatal diagnosis of wormian bones. *J Ultrasound Med.* 19(12):863-869.
- [19] Kaplan SB, Kemp SS, Oh KS (1991) Radiographic manifestations of congenital anomalies of the skull. *Radiol Clin North Am.* 29(2):195-218.
- [20] Marti B, Sirinelli D, Maurin L (2013) Wormian bones in a general paediatric population. *Diagn Interv Imaging.* 94:428-432. <https://doi.org/10.1016/j.diii.2013.01.001>.

- [21] Cirpan S, Aksu F, Mas N (2015) The incidence and topographic distribution of sutures including wormian bones in human skulls. *J Craniofac Surg.* 26(5):1687-1690. <https://doi.org/10.1097/SCS.0000000000001933>.
- [22] Ghosh SK, Biswas S, Sharma S, Chakraborty S (2017) An anatomical study of wormian bones from the eastern part of India: is genetic influence a primary determinant of their morphogenesis?. *Anat Sci Int.* 92(3):373-382. <https://doi.org/10.1007/s12565-016-0342-1>.
- [23] Natsis K, Piagkou M, Lazaridis N (2019) Incidence, number and topography of Wormian bones in Greek adult dry skulls. *Folia Morphol.* 78(2):359-370. <https://doi.org/10.5603/FM.a2018.0078>.
- [24] Vijay LVG, Ramakrishna A, Jacob M (2017) Incidence of wormian bones in dry human skulls in South Indian Population. *Int J Anat Res.* 5(3):4349-4355. <https://doi.org/10.16965/ijar.2017.331>.
- [25] Safak NK, Taskin RG, Yücel AH (2020) Morphologic and Morphometric Evaluation of the Wormian Bones. *Int J Morphol.* 38(1):69-73. <http://dx.doi.org/10.4067/S0717-95022020000100069>.
- [26] Sreekanth T, Samala N (2016) Morphological study of wormian bones in dried adult human skulls in Telangana. *Int J Anat Res.* 4(3):3257-3262. <https://doi.org/10.16965/ijar.2016.454>.
- [27] Ogut E, Yildirim FB (2023) Wormian bone types: investigating their appearance, correlation to sex, population affinity, and clinical syndromes. *Egypt J Forensic Sci.* 13:19. <https://doi.org/10.1186/s41935-023-00337-2>.
- [28] Carolineberry A, Berry RJ (1967) Epigenetic variation in the human cranium. *J Anat.* 101:361-379.
- [29] Guerram A, Le Minor JM, Renger S, Bierry G (2014) Brief communication: The size of the human frontal sinuses in adults presenting complete persistence of the metopic suture. *Am J Phys Anthropol.* 154(4):621-627. <https://doi.org/10.1002/ajpa.22532>
- [30] Aksu F, Cirpan S, Mas NG, Karabekir S, Magden AO (2014) Anatomic features of metopic suture in adult dry skulls. *J Craniofac Surg.* 25(3):1044-1046. <https://doi.org/10.1097/SCS.0000000000000564>
- [31] Çalışkan S, Oğuz KK, Tunalı S, Aldur MM, Erçakmak B, Sargon MF (2018) Morphology of cranial sutures and radiologic evaluation of the variations of intersutural bones. *Folia Morphol.* 77(4):730-735. <https://doi.org/10.5603/FM.a2018.0030>
- [32] Li JH, Chen ZJ, Zhong WX, Yang H, Liu D, Li YK (2022) Anatomical characteristics and significance of the metopism and Wormian bones in dry adult-Chinese skulls. *Folia Morphol.* <https://doi.org/10.5603/FM.a2022.0006>
- [33] Wu JK, Goodrich JT, Amadi CC, Miller T, Mulliken JB, Shanske AL (2011) Interparietal Bone (Os Incae) in Craniosynostosis. *Am J Med Genet Part A.* 155:287-294. <https://doi.org/10.1002/ajmg.a.33800>.
- [34] O'Loughlin VD (2004) Effects of Different Kinds of Cranial Deformation on the Incidence of Wormian Bones. *Am J Phys Anthropol.* 123:146-155. <https://doi.org/10.1002/ajpa.10304>

How to Cite;

Güler H, Güçlü Ekinci HK, Kamaşak Arpaçay B (2024) Variation of Wormian and Inca Bones in Adult Skulls. *Eur J Ther.* <https://doi.org/10.58600/eurjther1935>