








Aggressive Treatment of Refractory Coronary Artery Vasospasm in a Patient with Malignant Ventricular Tachyarrhythmia and Cardiac Arrest

Mert Doğan¹, Ergün Barış Kaya¹, Çiğdem Deniz¹, Uğur Canpolat¹, Mehmet Levent Şahiner¹, Ahmet Hakan Ateş¹, Kudret Aytemir¹

1 Hacettepe University Faculty of Medicine, Department of Cardiology, Ankara, Turkey

ABSTRACT

Coronary artery vasospasm (CAVS) is a clinical entity that can cause angina, but also unstable angina pectoris, acute myocardial infarction, fatal arrhythmias, and sudden death. Although it is a condition that is usually controlled with medical treatment, more aggressive treatments may rarely be required. In this case, the patient with a known diagnosis of CAVS had multiple arrests despite optimal medical treatment. We observed that fatal arrhythmias persisted in the Implantable Cardioverter Defibrillator (ICD) records, even though we implanted a stent and gave the patient maximal medical treatment. We performed sympathectomy as a last resort and we did not detect any recurrence in the 6-month follow-up of the patient. ICD implantation and sympathectomy should always be considered in resistant CAVS cases.

Keywords: Vasospastic coronary angina, Sudden cardiac arrest, Sympathectomy

INTRODUCTION

Coronary artery vasospasm (CAVS) is a well-known clinical scenario for development of angina or its equivalents, ischemic electrocardiographic changes, and associated complications (1). Among several proposed mechanisms of CAVS, vascular smooth muscle hyperactivity is considered as the most important factor (2). Clinical presentation varies between asymptomatic status to wide range of conditions including chronic coronary syndrome, acute coronary syndrome [unstable angina, non-ST-segment elevation myocardial infarction (NSTEMI) and ST-segment elevation myocardial infarction (STEMI)], and sudden cardiac death (3). Drug-refractory CAVS requiring percutaneous coronary intervention (PCI), implantable cardioverter defibrillator (ICD) implantation, and/or surgical sympathectomy is rarely reported in separate patients (4). Herein, we presented an interesting patient with a drug-refractory CAVS and multiple admissions to our emergency room due to angina pectoris and subsequent sudden cardiac arrest or ventricular tachyarrhythmia in whom PCI, ICD implantation, and surgical sympathectomy has been performed during follow-up.

Case

A 55-year-old male with hypertension, chronic hepatitis B infection, and smoking history admitted to our emergency room with acute onset chest pain at rest and developed sudden cardiac arrest just after admission. He has undergone coronary angiography and CAVS was demonstrated 3 years ago in our center. His medications included optimal doses of peroral calcium channel antagonist and long-acting nitrate. Spontaneous circulation was achieved after 8 cycles of cardiopulmonary resuscitation (CPR). Post-CPR electrocardiography (ECG) revealed sinus rhythm (heart rate of 72 bpm) and ST-segment elevation at inferior and anterior leads (Figure-1). Bedside echocardiography showed normal left and right ventricular functions, no pericardial effusion and flap appearance at the ascending aorta. He has been immediately transferred to cath lab for coronary angiography which demonstrated diffuse coronary vasospasm in the left anterior descending (LAD), circumflex (Cx), and intermediate arteries (Video 1). CAVS was disappeared after 1000 mcg of intracoronary nitrate (Video 2). There was a non-critical hazy atherosclerotic plaque at the mid LAD region. The ST-segment

How to cite: Dogan M, Kaya EB, Deniz C, Canpolat U, Şahine ML, Ates AH, Aytemir K. Aggressive Treatment of Refractory Coronary Artery Vasospasm in a Patient with Malignant Ventricular Tachyarrhythmia and Cardiac Arrest. Eur J Ther 2023;29(1):94-96. <https://doi.org/10.58600/eurjther-186>

Corresponding Author: Mert Dogan E-mail: drmertd@gmail.com

Received: 07.03.2023 • **Accepted:** 15.02.2023



Figure 1. In the 12-lead ECG of the patient taken after CPR in the emergency room, ST Elevation is seen in all leads.

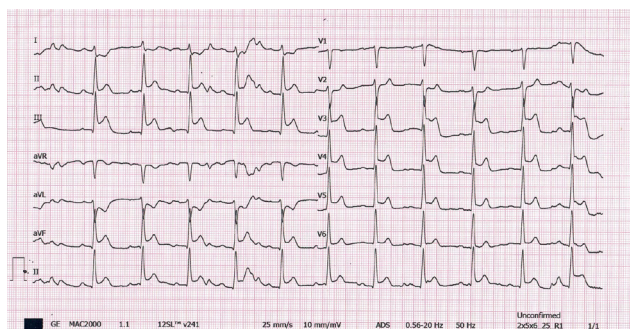
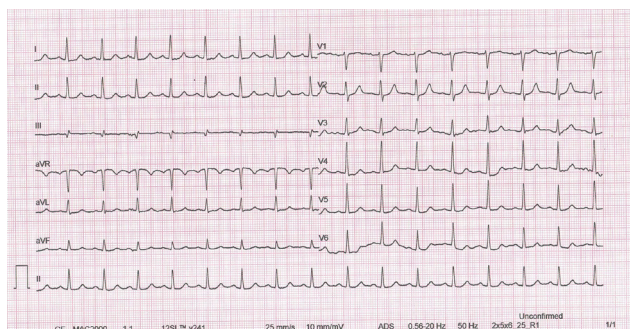


Figure 2. Follow-up ECG of the patient in the coronary intensive care unit after intracoronary nitrate administration during CA, normal sinus rhythm

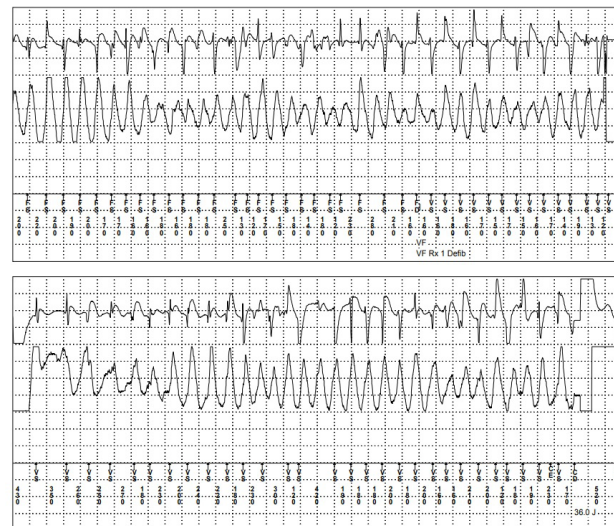

changes in control ECG were also disappeared after coronary angiography (Figure 2). The CAVS was thought as the etiology of chest pain and sudden cardiac arrest. As the patient developed sudden cardiac arrest despite optimal tolerated doses of vasodilators, ICD implantation has been performed as a secondary prophylaxis therapy. He has been discharged with the medications of isosorbide mononitrate, nifedipine, statin and clopidogrel. Two weeks later, the patient re-admitted to the emergency room with chest pain, appropriate ICD shocks, and subsequent cardiac arrest. After 30 minutes of effective CPR, spontaneous circulation was achieved. Intravenous nitrate was initiated immediately. He has been transferred to the cath lab for coronary angiography again. A non-critical hazy lesion at the mid LAD region became critical after cold-pressor test. Thus, a drug-eluting stent (DES)

Main Points:

- CAVS is not common in clinical practice and is well managed, especially when resistant.
- Malignant ventricular arrhythmias are the most likely cause of refractory CAVS, especially in cardiac arrest. For this reason, ICD implantation is not considered as a priority for patients.
- Sympathectomy should be considered in refractory CAVS cases that persist despite optimal medical therapy.

Figure 3. Documentation of the shock therapy received by the patient for the VF episode upon admission to the emergency department



was implanted to the mid LAD lesion (Video-3). ICD interrogation revealed the development of ventricular fibrillation (VF) which has been converted to sinus rhythm at first 2 attempts and no response to ICD shocks thereafter (Figure-3). 10 days later, he admitted with angina pectoris again and ECG revealed diffuse ST segment depression. During control coronary angiography, there was a diffuse CAVS at the circumflex artery and LAD except stented segment which has been improved with intracoronary nitrate. Thus, sympathetic denervation was planned for the patient. Bilateral thoracic sympathetic chain resection was performed with video-assisted thoracoscopic surgery (VATS) method. The patient was discharged uneventfully. He was clinically stable in the last 6-months follow-up and no episode was detected in the ICD control.

DISCUSSION

The prevalence of CAVS is highest between the ages of 40-70 and tends to decrease after the age of 70, and it has been shown to be more common especially in Japan than in Western countries (5). Although the pathogenesis of CAVS has not been fully elucidated, different pathogenic mechanisms such as vascular smooth muscle cell hyperactivity, endothelial dysfunction, magnesium deficiency, inflammation, abnormal autonomic nervous system response, genetic factors and oxidative stress are among the suggested causes (4). On the other hand, when we examine the risk factors, smoking, migraine and history of hypertension are known risk factors (6). Calcium channel blockers (CCB), long-acting nitrates (in combination with CCB in resistant angina), statins, Rho-kinase inhibitors and nicorandil are among the recommended treatments for CAVS treatment (4). Apart from this, the use of aspirin is not a recommended treatment in these patients, as it may cause vasospasm by inhibiting the release of vasodilator-acting prostacyclins (7). In our country, nicorandil and Rho-kinase inhibitors can not be prescribed to the patients due to lack of availability.

Our patient had a history of hypertension and smoking, which are risk factors for CAVS. In addition, it may be interesting to think that inflammation also affects CAVS in our patient with chronic hepatitis B infection. The cardiac arrest was probably developed as a result of ventricular malignant arrhythmia despite use of CCB+long-acting nitrate at the maximally tolerated dose. In patients resuscitated due to CAVS for whom medical therapy is ineffective or not tolerated, implantation of an ICD is a recommended approach in the guideline if significant survival beyond 1 year is expected (8). At the same time, when we look at the literature, it has been shown that a substantial number of patients with ICD implanted in patients with resistant CAVS received appropriate treatment for fatal arrhythmias (9). Therefore, we implanted an ICD for secondary protection in our patient. Our patient was also re-admitted to the emergency room after receiving ICD shocks for ventricular tachyarrhythmias during his follow-up. Coronary stent implantation may be considered when a lesion causing organic stenosis is present in CAVS patients (10). Thus, we decided to implant a DES to the mid LAD stenosis which became critical after the cold-pressure test.

Our patient presented to the emergency department again 10 days later with persistent chest pain and ST segment depression on ECG. Control coronary angiography showed extensive CAVS in the circumflex artery and LAD, except for the stented segment, which was resolved with intracoronary nitrate. Thoracic chain resection was performed with VATS method in our patient because of the recurrence of CAVS despite all other therapies. Since 1980s, the sympathectomy has been shown to be successful in cases of resistant vasospastic angina (11). In a study, sympathectomy led to the resolution of all symptoms including pulseless electrical activity and cardiac arrest, and it was shown to prevent recurrence of angina and arrhythmia (12). We discharged the patient uneventfully after all those medical procedures and when the patient came to the follow-up after 6 months, he had no complaints. There was no episode in the ICD interrogation. In conclusion, if CAVS persists despite maximally tolerated medical treatment, interventional procedures including PCI, ICD implantation in case of cardiac arrest, and sympathectomy should be considered accordingly.

Funding: No funding

Competing interest for all authors: The authors declare that they have no relevant conflict of interest.

Author's contributions: BAT: researched the literature, wrote the article, IN: critised and edited the paper

REFERENCES

- 1- Prinzmetal M, Kennamer R, Merliss R, et al. Angina pectoris. I. A variant form of angina pectoris; preliminary report. *Am J Med.* 1959;27:375–388.
- 2- Picard F, Sayah N, Spagnoli V, et al. Vasospastic angina: a literature review of current evidence. *Arch Cardiovasc Dis.* 2019;112(1):44–55.
- 3- Anthony Matta, Frederic Bouisset, Thibault Lhermusier, Fran Campelo-Parada, Meyer Elbaz, et al. Review Article Coronary Artery Spasm: New Insights. *Journal of Interventional Cardiology.* Volume 2020, Article ID 5894586, 10 pages.
- 4- Giovanni P. Talaricoa, Maria L. Crostab, Maria B. Giannicoa, Francesco Summariaa, Leonardo Calo, et al. Cocaine and coronary artery diseases: a systematic review of the literature. *J Cardiovasc Med* 2017, 18:291–294
- 5- Swarup S, Patibandla S, Grossman SA. Coronary Artery Vaso-spasm. NCBI Bookshelf. A service of the National Library of Medicine, National Institutes of Health. StatPearls [Internet]. Treasure Island (FL): StatPearls Publishing; 2021 Jan-.
- 6- Takaoka K, Yoshimura M, Ogawa H, et al. Comparison of the risk factors for coronary artery spasm with those for organic stenosis in a Japanese population: role of cigarette smoking. *Int J Cardiol.* 2000;72(2):121–126.
- 7- Min Chul Kim, Youngkeun Ahn, Keun Ho Park, Doo Sun Sim, Nam Sik Yoon, et al. Clinical outcomes of low-dose aspirin administration in patients with variant angina pectoris. *International Journal of Cardiology.* Volume 167, Issue 5, 1 September 2013, Pages 2333-2334.
- 8- Al-Khatib et al. 2017 AHA/ACC/HRS Guideline for Management of Patients With Ventricular Arrhythmias and the Prevention of Sudden Cardiac Death. *JACC VOL. 72, NO. 14,* 2018.
- 9- Matsue et al. Clinical Implications of an Implantable Cardioverter-Defibrillator in Patients With Vasospastic Angina and Lethal Ventricular Arrhythmia. *Journal of the American College of Cardiology.* Vol. 60, No. 10, 2012. NO. 4, 510-515 <https://doi.org/10.1080/20009666.2021.1915534>
- 10- JCS Joint Working Group. Guidelines for diagnosis and treatment of patients with vasospastic angina (Coronary Spastic Angina) (JCS 2013). *Circ J* 2014;78:2779–801.
- 11- Yaowang Lina, Huadong Liua, Danqing Yub, Meishan Wua, Qiyun Liua, et al. Sympathectomy versus conventional treatment for refractory coronary artery spasm. *Coronary Artery Disease* 2019, 30:418–424
- 12- Cardona-Guarache R, Pozen J, Jahangiri A, Koneru J, Shepard R, RobertsC, et al. Thoracic sympathectomy for severe refractory multivessel coronary artery spasm. *Am J Cardiol* 2016; 117:159–161.