

Comparison of the Effectiveness of Pulse Radiofrequency in the Treatment of Suprascapular Nerve in Chronic Shoulder Pain

Çağatay Küçükbingöz¹ , Ayşe Bahşi² , Tamer Bayram² , Fidan Marufoğlu² , Hayri T. Özbek² 

¹ Department of Anesthesiology&Reanimation, Ministry of Health Adana City Training & Research Hospital, Discipline of Pain Medicine, Adana, Turkey

² Department of Anesthesiology&Reanimation, Çukurova University Faculty of Medicine, Division of Pain Medicine, Adana, Turkey

Received: 2023-07-14 / Accepted: 2023-08-04 / Published Online: 2023-08-07

Correspondence

Çağatay Küçükbingöz

Address: Ministry of Health Adana City Training & Research Hospital, Department of Anesthesiology and Reanimation- Algology Clinic, Dr. Mithat Özsan Bulvarı Kışla Mah. 4522 Sok. No:1 Yüreğir, Adana / Turkey
E-mail: ckbingoz.md@gmail.com



This work is licensed under a Creative Commons Attribution-NonCommercial 4.0 International License.

ABSTRACT

Objectives: To investigate the effects of various durations of pulsed radiofrequency (PRF) application on pain and functional limitation in the short term in patients suffering from chronic shoulder pain.

Methods: Eighty three patients, 50 women (60.2%) and 33 men (39.8%) were included in the study. Ultrasound-guided PRF treatment of the suprascapular nerve was performed for 8 min in 44 (53.1%) and 10 min in 39 (46.9%) patients. The pain intensity of the patients was evaluated using the visual analog scale (VAS). The Shoulder Pain and Disability Index (SPADI) was utilized to define shoulder function and pain. VAS and SPADI measurements before and four weeks after treatment were recorded.

Results: The VAS and SPADI scores showed a significant improvement in both treatment groups ($P < 0.05$); however, no significant difference was observed between the groups.

Conclusion: Therefore, PRF of the suprascapular nerve is a beneficial treatment method in patients suffering from chronic shoulder pain; furthermore, the duration of PRF treatment of 8 or 10 minutes does not affect the effectiveness of the treatment.

Keywords: chronic shoulder pain, suprascapular nerve, pulsed radiofrequency

INTRODUCTION

Shoulder pain is a widespread source of pain after back and knee pain in musculoskeletal diseases [1]. The prevalence of shoulder pain in the general population is approximately 16%, and it occurs more often in women [2]. Its prevalence increases with age and is more common after the age of 65 years [2, 3]. Considering the high prevalence rate, functional limitation, and high chronicity, shoulder pain is not only substantial for patients' life quality but also for resource management in health [4]. Chronic shoulder pain has many different causes including rotator cuff disease, impingement syndrome, acromioclavicular osteoarthritis, adhesive capsulitis and glenohumeral osteoarthritis [5, 6].

In patients suffering from shoulder pain, activity modification and analgesic drugs are often administered in the first stage. If no improvement is observed despite these treatments, physical therapy applications can be attempted. However, in the absence of any improvement, clinicians may utilize the administration of ultrasound (US) or fluoroscopy-guided injection of local anesthetics and steroids into the symptomatic joint or tissue, including glenohumeral, acromioclavicular joint, and subacromial space. Surgical approaches may be considered in cases that do not benefit from conservative treatment [6, 7].

The suprascapular nerve (SSN) contributes to the sensory innervation of the glenohumeral and acromioclavicular joints and the motor innervation of the supraspinatus and infraspinatus muscles [8]. SSN block can subsequently increase the range of motion and decrease shoulder pain in different chronic shoulder pain syndromes [9-12]. If the duration of action of local anesthetics in the peripheral nerve block is insufficient, pulsed radiofrequency (PRF) lesioning can be exploited for long-dated pain palliation accompanied by positive results [13]. PRF of the SSN was reported to be as well as, if not better than, steroid and local anesthetic applications [14].

PRF is believed to have a neuromodulator effect rather than neurodestructive effect which is particularly advantageous during treatment [15]. PRF is a non-neurolytic lesioning technique for pain palliation, and no proof of neural damage has been reported after PRF administration [13, 16]. Erdine et al. [17] reported that PRF treatment caused microscopic detriment to the internal ultrastructural components of axons, which leads to the deterioration and disorganization of membrane and mitochondrial morphology and microfilaments and microtubules.

There is no consensus in the literature concerning the duration and parameters of PRF treatment [18, 19]. In clinical practice, the optimal exposure time of PRF remains obscure and the duration of exposure is selected based on the experience of the clinician [19, 20]. The number of studies examining the effect of various duration of PRF application on the recovery and functionality of patients is limited. Therefore, performing a study on this subject may provide valuable insights.

The aim of this study was to investigate the effects of various duration of PRF application on pain and functional limitation in the short term in patients suffering from chronic shoulder pain.

Main Points;

- Chronic shoulder pain is a common cause of musculoskeletal pain.
- Suprascapular nerve Pulsed Radiofrequency treatment helps alleviate pain and improve function.
- The duration of PRF treatment of suprascapular nerve of 8 or 10 minutes does not affect the effectiveness of the treatment.

MATERIALS AND METHODS

Patients

Patients who presented with shoulder pain due to adhesive capsulitis, supraspinatus tendinitis, shoulder impingement syndrome, and/or subacromial bursitis diagnosed at the Algology Department of Çukurova University between 2019 and 2021, and who have had shoulder pain complaints for at least three months, were included in the study, and pulsed radiofrequency treatment of the suprascapular nerve was performed under ultrasound guidance. Prior to the study, approval was obtained from Çukurova University Clinical Research Ethics Committee (06.01.2023-no: 129). After ethics committee approval, patients' medical record was retrospectively analyzed. Written informed consent was obtained from all patients before the procedure. Data were procured from patient files and follow-up forms. Cases with incomplete data in the files, individuals who did not undergo shoulder magnetic resonance imaging before treatment, patients with visual analog scale (VAS) and Shoulder Pain and Disability Index (SPADI) data deficient, and individuals with complications leading to premature termination of the procedure were excluded from the study.

The pain intensity of the patients was assessed using the VAS. The SPADI, a 13-item scale, was utilized to evaluate shoulder function and pain. VAS and SPADI measurements before and four weeks after treatment were recorded.

Procedure

All injections were administered in the operating room by experienced physicians using US-guided technique. The patient was positioned in a sitting position, intravenous access was established, and standard monitors (pulse oximetry, electrocardiogram, and noninvasive arterial pressure) were appropriately attached. The patient was premedicated with 2 mg intravenous midazolam bolus without affecting the patient's consciousness. The skin site was prepared and draped in a standard, sterile fashion, using a povidone iodine-based skin prep. The suprascapular notch and the insertion of the needle into the SSN monitored using US (Edge, Sonosite, Bothell, WA, USA) using a high-frequency linear probe (HFL50xp, 15-6 MHz) (Video 1, Figure 1). Skin anesthesia was accomplished by administering 1%, 1 cc lidocaine with a 25 G needle. Through an in-plane approach, a 22 G, a 10-cm long echogenic radiofrequency (RF) cannula having a 5-mm long active tip (EchoRF, St Jude Medical, Plymouth, MN, USA) was inserted into the suprascapular notch (Fig. 1 and Video 1). Appropriate

localization of the needle tip was confirmed under US. Sensory stimulation was subsequently implemented at 50 Hz at 0.5 V. Patients described paresthesia, tingling, and pain in the deltoid and upper arm region. The motor stimulation was then performed at 2 Hz at 1 V and twitches were observed in the shoulder girdle. After negative blood aspiration, 1 mL of 2% lidocaine was injected. Afterwards, 1 minute following the local anesthetic injection, the first group received a total of 480 seconds (8 minutes) of PRF with 4 cycles of 120 seconds each at 42°C, 45 V, 2 Hz frequency, and 20 ms wavelength. The second group was subjected to a total of 600 seconds (10 minutes) of PRF with 5 cycles of 120 seconds each at 42°C, 45 V, 2 Hz frequency, and 20 ms wavelength. After the PRF procedure, 8 mg dexamethasone (2 ml), 2 ml 0.5% bupivacaine, and 2 ml 1% lidocaine were mixed with 2 ml normal saline and administered to the patient at a total volume of 8 ml (Video 2). The treatment spreading through the tissues was visualized by US imaging. Patients were followed up for 1 hour in the postoperative care unit owing to possible complications.

Statistical Analysis

SPSS 25.0 (Version 25.0, SPSS Inc., Chicago, IL, USA) package program was used for statistical analyses. Categorical measurements were summarized as numbers and percentages and continuous measurements as mean and standard deviation (median and range, where applicable). Student's t-test was used for intergroup comparison of normally distributed data. Paired samples t-test was used for comparing pre- and post-procedure measurements. $P < 0.05$ indicated statistical significance in all analyses.

RESULTS

In this study, 147 patients who had shoulder pain for at least three months and underwent US-guided SSN PRF treatment between 2019 and 2021 were included. According to the specified criteria, 64 cases were excluded. Of the remaining 83 patients, 50 were female (60.2%) and 33 were male (39.8%). The mean age was 58.57 ± 11.47 years (mean age for men and women, 60.45 ± 10.80 and 57.32 ± 11.83 years respectively). No significant intergroup difference was observed in terms of age and sex ($p = 0.225$) (Table 1).

Of the 83 patients included in the study, 44 (53.1%) underwent PRF to SSN for 8 min and 39 (46.9%) for 10 min. The 8- and 10-min treatment groups showed no differences in terms of pre-treatment VAS, pre-treatment SPADI, and symptom durations

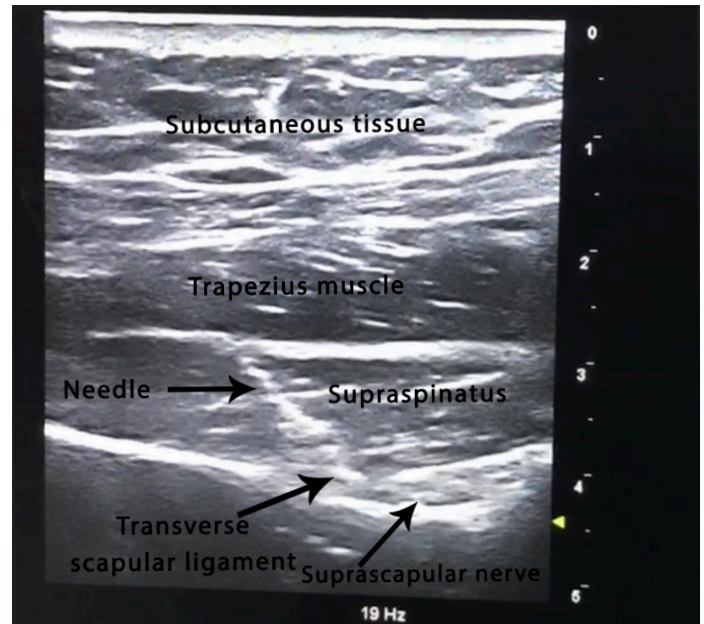
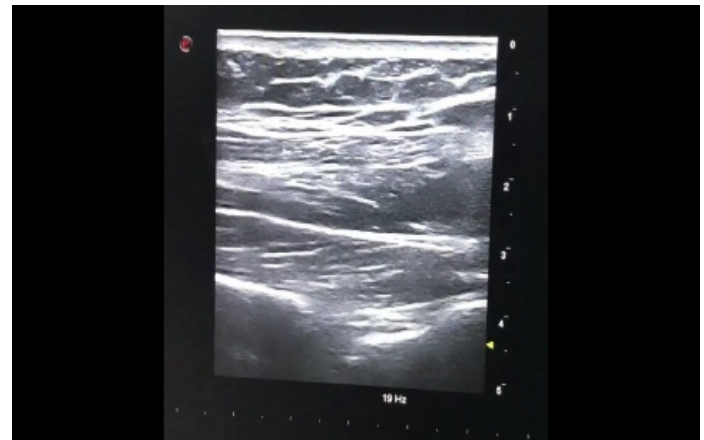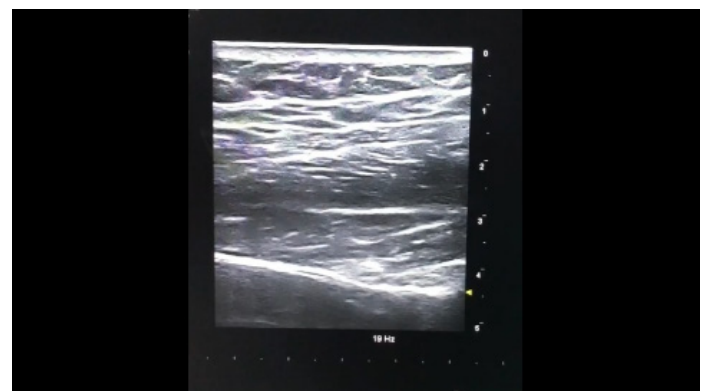


Figure 1. Anatomical structures observed in the intervention of the suprascapular nerve in ultrasound imaging.



Video 1. Demonstration of real-time pulse radiofrequency needle insertion into the suprascapular nerve under ultrasound guidance



Video 2. After the PRF procedure, administration of injection therapy and its spread under the transverse scapular ligament under ultrasound-guided

($p = 0.898, 0.064, \text{ and } 0.157$, respectively) (Table 1). Comparison of the pre- and post-procedure VAS and SPADI values revealed significant differences. Changes in VAS and SPADI values before and after the procedure showed no significant intergroup differences ($p = 0.387 \text{ and } 0.831$ for VAS and SPADI, respectively) (Table 2).

Table 1. Pre-procedure measurements

Parameter	8 min	10 min	p
Age	60.59 ± 9.68	56.28 ± 12.95	0.088
VAS	6.39 ± 0.87	6.36 ± 1.06	0.898
SPADI	59.54 ± 8.11	63.19 ± 9.62	0.064
Symptom Duration	7.14 ± 2.21	7.85 ± 2.32	0.157

Table 2. Comparison of pre- and post-procedure measurements

	n	Pre-Procedure	Post-Procedure	p
8 min VAS	44	6.39 ± 0.868	2.61 ± 1.19	0.001*
8 min SPADI	44	59.64 ± 8.10	23.09 ± 11.18	0.001*
10 min VAS	39	6.36 ± 1.06	2.85 ± 1.50	0.001*
10 min SPADI	39	63.19 ± 9.62	27.38 ± 13.85	0.001*
Total VAS	83	6.37 ± 0.96	2.72 ± 1.33	0.001*
Total SPADI	83	61.25 ± 9.98	25.11 ± 12.61	0.001*

*Significant difference

DISCUSSION

The SSN arises from the upper body of the brachial plexus at the junction of the ventral branches of the 5th and 6th cervical nerves and occasionally from the 4th cervical nerve; furthermore, the SSN comprises motor and sensory fibres [12, 21]. SSN has the greatest contribution in terms of overall shoulder innervation through its upper and lower articular branches [22]. Additionally, it provides motor innervation of the supraspinatus and infraspinatus muscles [8]. Therefore, when planning treatment, the motor fibres in the SSN that innervates the supraspinatus and infraspinatus should not be affected to preserve the existing motor function [23].

SSN blockade is known to be effective in the management of acute and chronic pain that may develop after trauma or surgery, independent of many etiologies. Although the efficacy of blockades with local anesthetics can be prolonged by adding steroids to the treatment, the duration of efficacy has not been sufficient in cases of chronic pain [24, 25]. Thus, several studies have emphasized that the use of the radiofrequency method in treatment is superior to the injection method in managing chronic shoulder pain [13, 14].

Radiofrequency therapy offers a cost-effective treatment modality for individuals suffering chronic and postoperative pain [26]. It is also a convenient alternative treatment for patients who cannot undergo surgical intervention [23, 26]. This therapeutic modality can be applied frequently in shoulder-related pain and has been reported to greatly contribute to recovery [11, 23, 26]. SSN PRF treatment helps alleviate pain and improve movement and function [10-12, 27]. This procedure is generally performed using US, among other guidance techniques [11, 12, 23, 27, 28]. US can provide an accurate visualization of the SSN [11].

Although the exact mechanism of radiofrequency treatment for chronic pain relief remains uncertain, the radiofrequency application was reported to diminish long-term pain by altering the expression of the c-fos gene in pain sensory neurons and producing a neuromodulator effect [29, 30]. Radiofrequency applications can be categorized into the following two treatment modalities: pulsed and conventional thermocoagulation. Since PRF provides neuromodulation without causing neural damage and without damaging the surrounding tissues, usage of PRF is recommended in nerves with both sensory and motor functions [11, 15, 19, 23, 31]. We preferred PRF application because the SSN has both sensory and motor branches. No consensus exists regarding the duration and parameters of PRF treatment [18, 19]. The optimal application time for PRF is uncertain and the application time is arbitrarily preferred in clinical procedures [19, 20]. PRF is predominantly executed for 2–8 min [19, 20, 30-34].

In the present study, PRF application on SSN for 8 or 10 min in patients suffering from chronic shoulder pain (rotator cuff, impingement syndrome, adhesive capsulitis) was found to be an efficient method in alleviating shoulder pain in a short period of 4 weeks. Jang et al. [35] noted that 4 min PRF treatment of SSN resulted in at least nine months of improvement in 11 patients with chronic intractable shoulder pain. Lüleci et al. [31] reported that PRF treatment of SSN applied for 8 min provided 6-month pain control in 45 of 57 patients (78.9%). Gurbet et al. [33] reported that the application of PRF for 2 min to the SSN in two cycles improved pain control and shoulder range of motion for three months in 8 patients with shoulder pain unresponsive to medical treatment or physiotherapy. Although there is not sufficient data in the literature that PRF treatment of SSN for 6 min can provide longer-term pain control than 4 min, it has been shown that antiallodynic activity increases when PRF time is increased from 2 minutes to 6 minutes [20]. This indicated that

PRF has a long-acting effect on nociceptive pain [27].

To investigate the effect of prolonged PRF exposure, Arakawa et al. [36] compared 6 and 12 min of PRF in rats with sciatic nerve lesions and found that the effects of PRF currents applied for 12 min were not significantly different from PRF applied for 6 min. Similarly, no significant intergroup difference was noted in the present study.

Similar to the studies conducted by Ergönerç et al. [27], Wu et al. [11], and Liliang et al. [13], a decrease in mean VAS and SPADI values was observed at follow-up. In the present study, mean VAS and SPADI values measured four weeks after the procedure were significantly lower than baseline measurements in both 8-and 10-min PRF groups. The decrease in the mean VAS and SPADI values of the patients was reported to be similar with 8 and 10 min of PRF application. Reportedly, neither duration of PRF administration was superior to the other on pain and functionality.

In patients suffering from shoulder pain, PRF therapy resulted in favorable clinical efficacy for at least 12 weeks [37]. US-guided PRF treatment of SSN is an effective treatment modality for managing chronic shoulder pain. In the present study, we performed US-guided PRF combined with steroid treatment on SSN in all our patients. The effects of the combination of PRF and a short-acting corticosteroid were shown to last up to 24 weeks [38].

PRF is a simple, minimally invasive treatment procedure that is predominantly well tolerated among older adults; however, it continues to have the potential risk of complications including bleeding, infection, nerve injury, and neuroma. The most important complication is the development of pneumothorax [35, 39]. This risk can be significantly minimized using US as observed in the present study. In addition, no complications or side effects were observed in our patients during the follow-up period.

Further randomized controlled trials with longer follow-up periods comparing the efficacy of PRF application duration on the SSN are required to fully clarify its role in the treatment of chronic shoulder pain.

Limitations

The retrospective study design, the absence of a control group,

the relatively short follow-up period, and the small sample size were the limiting factors of our study.

CONCLUSION

Several studies in the literature have examined PRF treatment of the SSN; however, to the best of our knowledge, no definitive guideline exists on the algorithm of PRF treatment duration. However, despite its limitations, the results obtained in the present study were significant as they supported the small number of comparable articles in the literature and show that the duration of treatment does not have a visible effect on efficacy.

Funding: None

Conflicts of interest: None

Ethical Approval: This study was obtained from approval by Çukurova University Clinical Research Ethics Committee (06.01.2023-no: 129).

Author Contributions: Conception: K,Ç; B,T- Design: K,Ç;B,T;B,A- Supervision:K,Ç;O,HT -Materials: B,T;M,F- Data Collection and/or Processing: K,Ç;B,T;B,A;M;F- Analysis and/or Interpretation: K,Ç;B,T;B,A;M;F;O,HT- Literature: K,Ç;B,T;B,A;M;F;O,HT- Review: K,Ç;B,T;B,A - Writing: K,Ç;B,T;B,A- Critical Review: K,Ç;B,A;B,T;M;F;O,HT

REFERENCES

- [1] Urwin M, Symmons D, Allison T, Brammah T, Busby H, Roxby M, Simmons A, Williams G (1998) Estimating the burden of musculoskeletal disorders in the community: the comparative prevalence of symptoms at different anatomical sites, and the relation to social deprivation. *Ann Rheum Dis* 57:649-655. <https://doi.org/10.1136/ard.57.11.649>
- [2] Lucas J, van Doorn P, Hegedus E, Lewis J, van der Windt D (2022) A systematic review of the global prevalence and incidence of shoulder pain. *BMC Musculoskelet Disord* 23:1073. <https://doi.org/10.1186/s12891-022-05973-8>
- [3] Hodgetts CJ, Leboeuf-Yde C, Beynon A, Walker BF (2021) Shoulder pain prevalence by age and within occupational groups: a systematic review. *Arch Physiother* 11:24. <https://doi.org/10.1186/s40945-021-00119-w>
- [4] Prato G, Terranova G, Grossi P (2022) SP27 Pulsed

- radiofrequency in chronic shoulder pain: a state of the art review. *Regional Anesthesia & Pain Medicine* 47:A29-A31
- [5] Burbank KM, Stevenson JH, Czarnecki GR, Dorfman J (2008) Chronic Shoulder pain part I: evaluation and diagnosis. *American family physician* 77:453-460
- [6] Andrews JR (2005) Diagnosis and treatment of chronic painful shoulder: review of nonsurgical interventions. *Arthroscopy* 21:333-347. <https://doi.org/10.1016/j.arthro.2004.11.003>
- [7] Burbank KM, Stevenson JH, Czarnecki GR, Dorfman J (2008) Chronic shoulder pain: part II. Treatment. *Am Fam Physician* 77:493-497
- [8] Miniato MA, Anand P, Varacallo M (2021) Anatomy, shoulder and upper limb, shoulder. StatPearls [Internet]. StatPearls Publishing
- [9] Vecchio PC, Adebajo AO, Hazleman BL (1993) Suprascapular nerve block for persistent rotator cuff lesions. *J Rheumatol* 20:453-455
- [10] Jump CM, Waghmare A, Mati W, Malik RA, Charalambous CP (2021) The Impact of Suprascapular Nerve Interventions in Patients with Frozen Shoulder: A Systematic Review and Meta-Analysis. *JBJS Rev* 9:e21. <https://doi.org/10.2106/JBJS.RVW.21.00042>
- [11] Wu YT, Ho CW, Chen YL, Li TY, Lee KC, Chen LC (2014) Ultrasound-guided pulsed radiofrequency stimulation of the suprascapular nerve for adhesive capsulitis: a prospective, randomized, controlled trial. *Anesth Analg* 119:686-692. <https://doi.org/10.1213/ANE.0000000000000354>
- [12] Schoenherr JW, Flynn DN, Doyal A (2023) Suprascapular Nerve Block. StatPearls. StatPearls Publishing Copyright © 2023, StatPearls Publishing LLC., Treasure Island (FL)
- [13] Liliang PC, Lu K, Liang CL, Tsai YD, Hsieh CH, Chen HJ (2009) Pulsed radiofrequency lesioning of the suprascapular nerve for chronic shoulder pain: a preliminary report. *Pain Med* 10:70-75. <https://doi.org/10.1111/j.1526-4637.2008.00543.x>
- [14] Abdelrahman AS, Bassiouny AM (2019) Ultrasound Guided Radiofrequency Ablation of the Suprascapular Nerve Versus Injection Block Technique: A Comparative Study in Patients with Chronic Shoulder Pain. *The Medical Journal of Cairo University* 87:3859-3864. <https://doi.org/10.21608/mjcu.2019.70137>
- [15] Byrd D, Mackey S (2008) Pulsed radiofrequency for chronic pain. *Curr Pain Headache Rep* 12:37-41. <https://doi.org/10.1007/s11916-008-0008-3>
- [16] Erdine S, Yucel A, Cimen A, Aydin S, Sav A, Bilir A (2005) Effects of pulsed versus conventional radiofrequency current on rabbit dorsal root ganglion morphology. *Eur J Pain* 9:251-256. <https://doi.org/10.1016/j.ejpain.2004.07.002>
- [17] Erdine S, Bilir A, Cosman ER, Cosman ER, Jr. (2009) Ultrastructural changes in axons following exposure to pulsed radiofrequency fields. *Pain Pract* 9:407-417. <https://doi.org/10.1111/j.1533-2500.2009.00317.x>
- [18] Chua NH, Vissers KC, Sluijter ME (2011) Pulsed radiofrequency treatment in interventional pain management: mechanisms and potential indications-a review. *Acta Neurochir (Wien)* 153:763-771. <https://doi.org/10.1007/s00701-010-0881-5>
- [19] Pushparaj H, Hoydonckx Y, Mittal N, Peng P, Cohen SP, Cao X, Bhatia A (2021) A systematic review and meta-analysis of radiofrequency procedures on innervation to the shoulder joint for relieving chronic pain. *Eur J Pain* 25:986-1011. <https://doi.org/10.1002/ejp.1735>
- [20] Tanaka N, Yamaga M, Tateyama S, Uno T, Tsuneyoshi I, Takasaki M (2010) The effect of pulsed radiofrequency current on mechanical allodynia induced with resiniferatoxin in rats. *Anesth Analg* 111:784-790. <https://doi.org/10.1213/ANE.0b013e3181e9f62f>
- [21] Ajmani ML (1994) The cutaneous branch of the human suprascapular nerve. *J Anat* 185 (Pt 2):439-442
- [22] Laumonerie P, Dalmas Y, Tibbo ME, Robert S, Faruch M, Chaynes P, Bonnevalle N, Mansat P (2020) Sensory innervation of the human shoulder joint: the three bridges to break. *J Shoulder Elbow Surg* 29:e499-e507. <https://doi.org/10.1016/j.jse.2020.07.017>
- [23] Kane TP, Rogers P, Hazelgrove J, Wimsey S, Harper GD (2008) Pulsed radiofrequency applied to the suprascapular nerve in painful cuff tear arthropathy. *J Shoulder Elbow Surg* 17:436-440. <https://doi.org/10.1016/j.jse.2007.10.007>
- [24] Gado K, Emery P (1993) Modified suprascapular nerve

- block with bupivacaine alone effectively controls chronic shoulder pain in patients with rheumatoid arthritis. *Ann Rheum Dis* 52:215-218. <https://doi.org/10.1136/ard.52.3.215>
- [25] Eyigor C, Eyigor S, Korkmaz OK, Uyar M (2010) Intra-articular corticosteroid injections versus pulsed radiofrequency in painful shoulder: a prospective, randomized, single-blinded study. *Clin J Pain* 26:386-392. <https://doi.org/10.1097/AJP.0b013e3181cf5981>
- [26] Albishi W, AbuDujain NM, Dakhil AB, Alzeer M (2023) The Utilization of Radiofrequency Techniques for Upper Extremity Pain Management. *Pain Physician* 26:125-135
- [27] Ergonenc T, Beyaz SG (2018) Effects of ultrasound-guided suprascapular nerve pulsed radiofrequency on chronic shoulder pain. *Med Ultrason* 20:461-466. <https://doi.org/10.11152/mu-1543>
- [28] Esparza-Minana JM, Mazzinari G (2019) Adaptation of an Ultrasound-Guided Technique for Pulsed Radiofrequency on Axillary and Suprascapular Nerves in the Treatment of Shoulder Pain. *Pain Med* 20:1547-1550. <https://doi.org/10.1093/pm/pny311>
- [29] Higuchi Y, Nashold BS, Jr., Sluijter M, Cosman E, Pearlstein RD (2002) Exposure of the dorsal root ganglion in rats to pulsed radiofrequency currents activates dorsal horn lamina I and II neurons. *Neurosurgery* 50:850-855; discussion 856. <https://doi.org/10.1097/00006123-200204000-00030>
- [30] Van Zundert J, de Louw AJ, Joosten EA, Kessels AG, Honig W, Dederen PJ, Veening JG, Vles JS, van Kleef M (2005) Pulsed and continuous radiofrequency current adjacent to the cervical dorsal root ganglion of the rat induces late cellular activity in the dorsal horn. *Anesthesiology* 102:125-131. <https://doi.org/10.1097/00000542-200501000-00021>
- [31] Luleci N, Ozdemir U, Dere K, Toman H, Luleci E, Irban A (2011) Evaluation of patients' response to pulsed radiofrequency treatment applied to the suprascapular nerve in patients with chronic shoulder pain. *J Back Musculoskelet Rehabil* 24:189-194. <https://doi.org/10.3233/BMR-2011-0293>
- [32] Orhurhu V, Akinola O, Grandhi R, Urits I, Abd-Elsayed A (2019) Radiofrequency Ablation for Management of Shoulder Pain. *Curr Pain Headache Rep* 23:56. <https://doi.org/10.1007/s11916-019-0791-z>
- [33] Gurbet A, Turker G, Bozkurt M, Keskin E, Uckunkaya N, Sahin S (2005) [Efficacy of pulsed mode radiofrequency lesioning of the suprascapular nerve in chronic shoulder pain secondary to rotator cuff rupture]. *Agri* 17:48-52
- [34] Keskinbora K, Aydinli I (2009) [Long-term results of suprascapular pulsed radiofrequency in chronic shoulder pain]. *Agri* 21:16-21
- [35] Jang JS, Choi HJ, Kang SH, Yang JS, Lee JJ, Hwang SM (2013) Effect of pulsed radiofrequency neuromodulation on clinical improvements in the patients of chronic intractable shoulder pain. *J Korean Neurosurg Soc* 54:507-510. <https://doi.org/10.3340/jkns.2013.54.6.507>
- [36] Arakawa K, Kaku R, Kurita M, Matsuoka Y, Morimatsu H (2018) Prolonged-duration pulsed radiofrequency is associated with increased neuronal damage without further antiallodynic effects in neuropathic pain model rats. *J Pain Res* 11:2645-2651. <https://doi.org/10.2147/JPR.S168064>
- [37] Liu A, Zhang W, Sun M, Ma C, Yan S (2016) Evidence-based Status of Pulsed Radiofrequency Treatment for Patients with Shoulder Pain: A Systematic Review of Randomized Controlled Trials. *Pain Pract* 16:518-525. <https://doi.org/10.1111/papr.12310>
- [38] Sinha P, Sarkar B, Goswami S, Ray Karmakar P, Dasgupta SR, Basu S (2020) Effectiveness of Combination of Ultrasonography-Guided Pulsed Radiofrequency Neuromodulation With Steroid at the Suprascapular Nerve in Chronic Shoulder Pain. *Pain Pract* 20:16-23. <https://doi.org/10.1111/papr.12820>
- [39] Shah RV, Racz GB (2003) Pulsed mode radiofrequency lesioning of the suprascapular nerve for the treatment of chronic shoulder pain. *Pain Physician* 6:503-506. <https://doi.org/10.36076/ppj.2003/6/503>

How to Cite;

Kucukbingoz Ç, Bahşi A, Bayram T, Marufoğlu F, Özbek HT (2023) Comparison of the Effectiveness of Pulse Radiofrequency in the Treatment of Suprascapular Nerve in Chronic Shoulder Pain.. *Eur J Ther.* 29(3):334-340. <https://doi.org/10.58600/eurjther1707>