






Case Report

Preoperative Assessment for Coronary Artery Bypass Graft: Going Back to the Basics

Dimos Karangelis¹ , Konstantinos C. Christodoulou^{1,2} , Efstratios Georgakarakos³ , Aliko Fiska² ,
Dimitrios Mikroulis¹ 

¹Department of Cardiac Surgery Democritus University of Thrace, University Hospital of Alexandroupolis, Alexandroupolis, Greece.

²Laboratory of Anatomy, Medical School, Democritus University of Thrace, Alexandroupolis, Greece.

³Department of Vascular Surgery, University Hospital of Alexandroupolis, Democritus University of Thrace, Alexandroupolis, Greece.

Received: 2023-07-12 / Accepted: 2023-07-23 / Published Online: 2023-07-23

Correspondence

Konstantinos C. Christodoulou
Address: Domnas Visvizi 34, Pylaia,
Thessaloniki, P.C. 55534, Greece
E-mail: [konstantinoschristodoulou@
yahoo.gr](mailto:konstantinoschristodoulou@yahoo.gr)



This work is licensed under a Creative
Commons Attribution-NonCommercial 4.0
International License.

ABSTRACT

As doctors increasingly rely on technological advancements, ever-improving laboratory techniques, and imaging modalities, the importance of a thorough physical evaluation and bedside manner has been noticeably diminished. When it comes to patients scheduled for coronary artery bypass graft (CABG), the preoperative bilateral arm blood pressure (BP) measurement is often omitted; thus, sinister signs of atherosclerotic disease like the brachial gradient are neglected and the surgical plan is jeopardized. We present the case of a 72-year-old male listed for CABG, stressing the necessity of meticulous clinical examination and the routine use of color Doppler ultrasonography (CDUS), prior to surgery. This case aims to highlight the major role of thorough preoperative clinical assessment. The bilateral BP measurement and CDUS are two reliable, expeditious, noninvasive preoperative screening methods, which can detect patients with generalized atherosclerosis, altering, if necessary, the surgical plan, and aiming for the best possible outcome, without complications.

Keywords: clinical examination, arm pressure gradient, cardiac surgery, subclavian artery stenosis, color doppler ultrasonography

INTRODUCTION

The role of comprehensive physical examination and bedside skills has been remarkably lessened nowadays, as physicians tend to depend more on technological advancements, and the ever-improving laboratory and imaging modalities [1]. It seems that technology has evolved from its initial complementing role, into a popular and dominant diagnostic tool, prevailing over clinical skills [1]. In addition, the global Covid-19 pandemic, which severely disrupted medical education, delivered another blow to the already fading from the mid-20th century clinical examination [2]. This is particularly evident in high volume clinical centers, where patients scheduled for coronary artery bypass graft (CABG) are not routinely submitted to preoperative bilateral

arm blood pressure (BP) measurement. Important and potentially tailoring-treatment information is therefore neglected [3].

A typical example is the brachial gradient, a sinister sign of advanced atherosclerotic disease, which may alert the physician for the need to revise his surgical plan. Differential arm pressure will dictate further preoperative evaluation, which can be carried out either with color Doppler ultrasonography (CDUS), or CT angiography [4]. The examination of the subclavian artery (SCA), the left internal thoracic artery (LITA) and the postoperative evaluation of graft patency can be performed using the well-established CDUS technique [4].

We report the case of an elderly patient, with the aim to emphasize on the necessity of the meticulous clinical examination and the routine use of CDUS, prior to CABG surgery.

CASE PRESENTATION

A 72-year-old male, a heavy smoker with no prior medical history, was listed for CABG surgery at our cardiac surgery clinic. During preoperative clinical examination, we found a significant difference in systolic BP between the left (80mmHg) and right (130mm Hg) arm. Following the clinic's protocol, the patient underwent a CDUS for the initial assessment of probable subclavian and/or internal thoracic arteries disease.

Both internal mammary arteries were patent. Notably, there was a systolic flow reversal in the LITA with low/modest peak systolic velocities (~ 20 cm/s). This was particularly evident in the vessel's proximal end, adjacent to the SCA, along with collateral flow through the left intercostal arteries (Figure 1). Regarding the left SCA, the CDUS exhibited low upstroke waveforms (tardus parvus with peak systolic velocities around 40 cm/s) post the occlusion, which corroborate with significant stenosis/occlusion of the proximal left SCA. In addition, there was reversal flow in the left vertebral artery, accompanied by significant peak systolic velocities in the right vertebral artery (120 cm/s); those findings are consistent with subclavian steal syndrome. Subsequently, a preoperative CT carotid angiography confirmed the proximal left SCA occlusion (Figure 2). The

patient, who displayed no evidence of arm claudication, underwent a triple CABG procedure with the right ITA deployed to the left anterior descending artery and the two saphenous vein grafts to an obtuse marginal branch and the right coronary artery, respectively. His postoperative course was uneventful, and the patient was discharged on the 6th postoperative day.

DISCUSSION

CDUS is an easily applicable, noninvasive functional technique for preoperative screening. Up to 7% of the CABG patients have severe SCA disease, according to medical literature [5]. Patel and colleagues in an attempt to decipher its prevalence, showed that the occurrence of significant SCA disease, proximal to the origin of the LITA (stenosis $> 50\%$ of luminal diameter), accounted for 5% of the cases [6]. In the same paper, the authors highlight the infrequency of patients' routine evaluation during coronary angiography, prior to CABG, which leads to failure to preoperatively document cases of LITA disease [6].

LITA is the most preferred conduit for coronary revascularization, as it has exhibited superior long-term patency [7]. However, SCA stenosis or occlusion proximal to the origin of LITA may severely compromise the graft's flow, even if the internal thoracic artery (ITA) per se, is an otherwise disease-free graft. Therefore, this can potentially result in retrograde flow or steal phenomenon from the coronary circulation, with resultant myocardial ischemia [8].

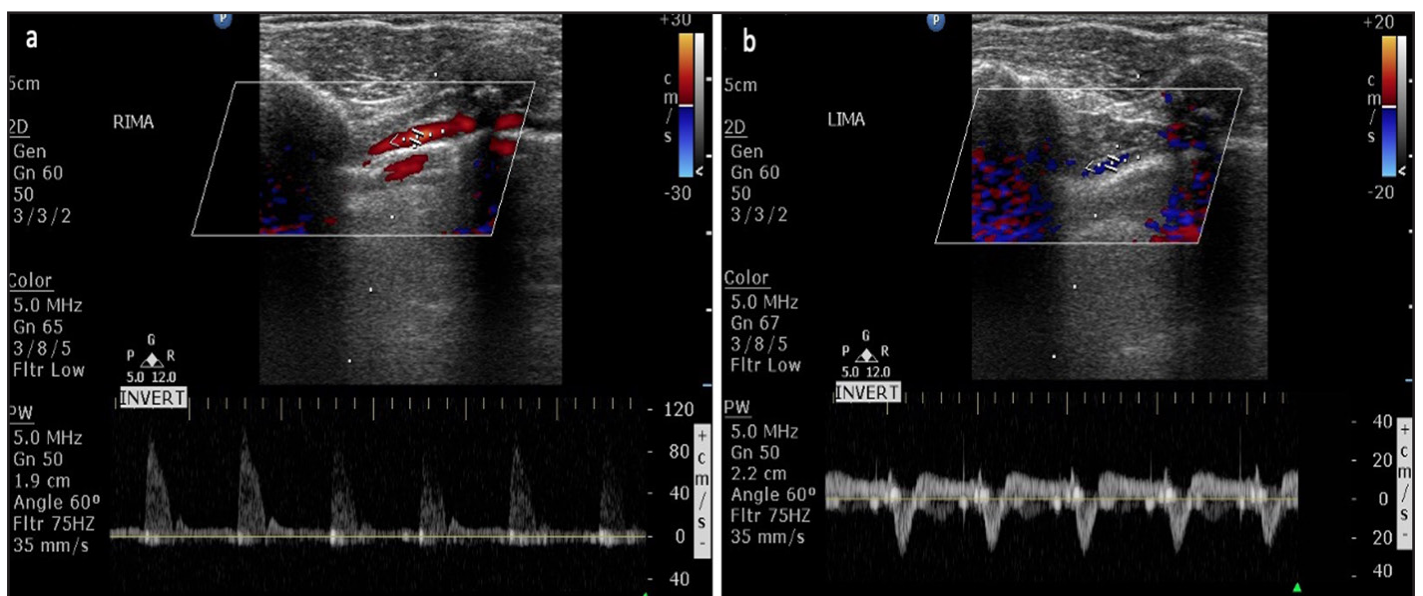


Figure 1a. CDUS of the right ITA; the artery is patent with normal systolic velocities (~ 80 - 100 cm/sec). **b.** CDUS of the LITA depicts low maximum systolic velocities (~ 20 cm/s) and reversal of flow in the systolic phase. ITA: internal thoracic artery, LITA: left internal thoracic artery

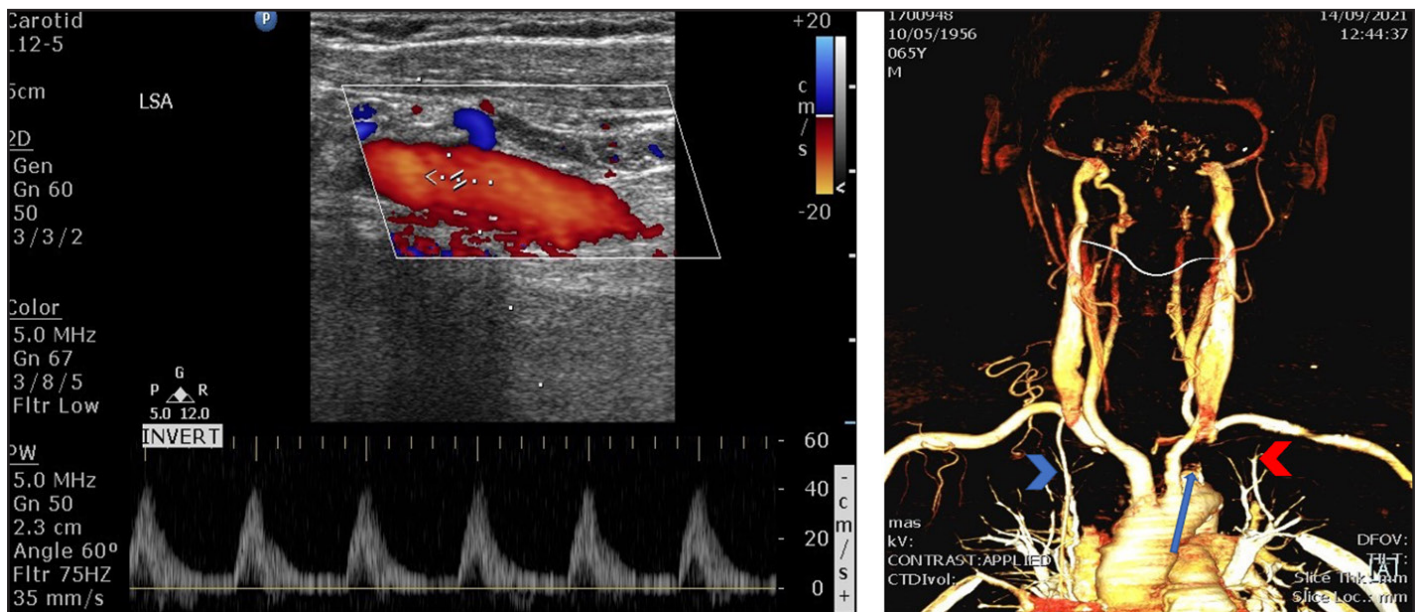


Figure 2. Left side: CDUS of the left SCA shows low upstroke waveforms (tardus parvus with peak systolic velocities of ~ 40 cm/s). Right side: CT angiogram of the carotids; proximal left SCA occlusion is demarcated by a blue arrow. Right ITA is visible (blue chevron) while the LITA is not depicted (red chevron). CDUS: color Doppler ultrasonography, SCA: subclavian artery, ITA: internal thoracic artery, LITA: left internal thoracic artery

In the preoperative setting of CABG, this can have major impact on surgical planning, especially on the grafts' arrangement. The need for surgeons' awareness cannot be overemphasized, since detection of optimal ITA flow prior to CABG can reduce complications caused by post-ITA graft ischemia [4, 6].

The preoperative routine of bilateral arm BP measurement is a simple method to enhance the safety of CABG [3]. This elementary, yet highly important examination can identify, in time, patients with SCA and LITA disease, shaping the surgical plan to achieve optimal revascularization and reduce the likelihood of unfavorable peri- and postoperative complications [9].

CONCLUSIONS

This case raises awareness of the crucial role of an in-depth preoperative clinical assessment, aiming especially to young doctors and nursing staff. In addition, it underscores the efficiency and convenience of CDUS, which represents a cost and time-effective, noninvasive modality for the evaluation of the subclavian and internal thoracic arteries flow and patency. The devoutly performed routine-medical-examination will not only provide a far more tailored treatment, but it will also diminish any chance of severe complications or even death, due to management and surgical mishaps.

Conflict of Interest: None.

Funding: None.

Consent: In order to publish our case with its accompanied images, we received a signed consent form from our patient.

Acknowledgements: None.

All authors had access to the data and a role in writing the manuscript.

REFERENCES

- [1] Feddock CA (2007) The lost art of clinical skills. *Am J Med.* 120(4):374-378. <https://doi.org/10.1016/j.amjmed.2007.01.023>
- [2] Erdevir M, Uyaroglu OA, Ozdede M, Tanriover MD (2021) "COVID-19: The final nail in the coffin for physical examination" Evaluation of the effects of COVID-19 pandemic on physical examination habits of residents in a university hospital: A cross-sectional survey. *Int J Clin Pract.* 75(12):e14988. <https://doi.org/10.1111/ijcp.14988>

- [3] Baribeau Y, Westbrook BM, Charlesworth DC, Hearne MJ, Bradley WA, Maloney CT (2002) Brachial gradient in cardiac surgical patients. *Circulation*. 106(12 Suppl 1):I11-I13.
- [4] Gao J, Zhao Z, Zhu J, Tian H, Liu Y (2021) The Role of Color Doppler Ultrasonography in the Perioperative Period of Coronary Artery Bypass Grafting: Comparison with Transit-Time Flow Measurement. *Cardiology*. 146(5):583-590. <https://doi.org/10.1159/000512430>
- [5] Rogers JH, Calhoun RF, 2nd (2007) Diagnosis and management of subclavian artery stenosis prior to coronary artery bypass grafting in the current era. *J Card Surg*. 22(1):20-25. <https://doi.org/10.1111/j.1540-8191.2007.00332.x>
- [6] Patel P, Shamma NW, Kapalis MJ, Dippel EJ, Lemke J, Harb C (2005) Routine visualization of the left internal mammary artery before bypass surgery: is it necessary? *J Invasive Cardiol*. 17(9):479-481.
- [7] Taggart DP, Benedetto U, Gerry S, Altman DG, Gray AM, Lees B, et al. (2019) Bilateral versus Single Internal-Thoracic-Artery Grafts at 10 Years. *N Engl J Med*. 380(5):437-446. <https://doi.org/10.1056/NEJMoa1808783>
- [8] Abdul Jabbar A, Houston J, Burket M, Il'Giovine ZJ, Srivastava BK, Agarwal A (2017) Screening for subclinical subclavian artery stenosis before coronary artery bypass grafting: Should we do it? *Echocardiography*. 34(6):928-933. <https://doi.org/10.1111/echo.13528>
- [9] Verghese A, Charlton B, Kassirer JP, Ramsey M, Ioannidis JP (2015) Inadequacies of Physical Examination as a Cause of Medical Errors and Adverse Events: A Collection of Vignettes. *Am J Med*. 128(12):1322-1324 e3. <https://doi.org/10.1016/j.amjmed.2015.06.004>

How to Cite;

Karangelis D, Christodoulou KC, Georgakarakos E, Fiska A, Mikroulis D (2023) Preoperative Assessment for Coronary Artery Bypass Graft: Going Back to the Basics. *Eur J Ther*. 29(4):952-955. <https://doi.org/10.58600/eurjther1704>