

# Relationship Between Ostiomeatal Complex Variations and Maxillary Sinus Pathologies in Children and Adolescents Using CBCT

Eda Didem Yalcin<sup>1</sup>, Elif Meltem Aslan Ozturk<sup>2</sup>, Suleyman Bozkaya<sup>3</sup>

<sup>1</sup> Department of Dentomaxillofacial Radiology, Istanbul Health and Technology University, Faculty of Dentistry, Istanbul, Turkey

<sup>2</sup> Department of Dentomaxillofacial Radiology, Ankara Medipol University, Faculty of Dentistry, Ankara, Turkey

<sup>3</sup> Department of Oral and Maxillofacial Surgery, Istanbul Health and Technology University, Faculty of Dentistry, Istanbul, Turkey

## ABSTRACT

**Objective:** The aim of this study is to evaluate relationship between ostiomeatal complex variations (OMC) and maxillary sinus pathologies in children and adolescents using cone-beam computed tomography (CBCT).

**Methods:** CBCT images of 72 patients (44 males and 28 females) aged 7-18 years were evaluated retrospectively. Presence of nasal septal deviation (NSD), nasal septal pneumatization (NSP), concha bullosa (CB), accessory maxillary ostium (AMO), agger nasi cell (ANC), Haller cell (HC), Onodi cell (OC), ethmoid sinusitis and maxillary sinus pathologies were investigated. Maxillary sinus pathologies were classified. Correlations of OMC variations with each other, maxillary sinus pathologies and ethmoid sinusitis were investigated. Chi-square test was used to analyze relationships among variables and distribution of parameters.

**Results:** NSD was determined in 70.8%, NSP in 40.3%, ethmoid sinusitis in 75%, maxillary sinus pathology in 34.8% of images. OMC variations rates were detected as CB 31.3%, AMO 16%, ANC 16%, HC 24.3% and OC 18.8%. The most common maxillary sinus pathology was localized mucosal thickening, with a rate of 15.3% on right and 22.2% on left. Statistically significant differences were determined between almost all OMC variations with each other, and between anatomical variations in OMC with maxillary sinus pathologies except for NSP and AMO ( $p < 0.05$ ). The presence of ethmoid sinusitis was more common in males ( $p = 0.026$ ).

**Conclusion:** Anatomical variations in OMC had no significant effect on maxillary sinus pathology except for NSP and AMO. Besides, most of anatomical variations in OMC were statistically significantly correlated with each other. CBCT visualization of these variations is important for sinonasal surgery and is an effective method in children and adolescents with low radiation dose and high image quality compared to computed tomography.

**Keywords:** Ostiomeatal complex, anatomical variations, maxillary sinus pathologies, children and adolescents, cone-beam computed tomography

## INTRODUCTION

Ostiomeatal complex (OMC) is formed by the maxillary sinus ostium, hiatus semilunaris, infundibulum, frontal recess, ethmoid bulla, uncinat process, frontal sinus ostium and middle turbinate [1]. Anatomical variations of the OMC predispose to infection and cause focal symptoms in some patients thus ethmoid sinusitis and maxillary sinus pathologies may occur [2]. The most common anatomical variations in the OMC were nasal septum deviation, nasal septal pneumatization, concha bullosa, agger nasi cell, Haller cell, and Onodi cell [3]. The structure, size, and location of paranasal sinuses differ in children from adults, and anatomical variations are more common [4]. Allergy,

odontogenic infections, anatomical variations and ostiomeatal occlusions are the most important causes of chronic sinusitis and maxillary sinus pathologies in children and adolescents cases [5, 6].

Nasal septal deviation (NSD) may be developmental or acquired. Intrauterine, perinatal and post-natal traumas, developmental defects, congenital deformities, mouth breathing and finger sucking may cause NSD [7]. Nasal septal pneumatization (NSP) occurs when air cells extend from the sphenoid sinus or crista galli to the nasal septum and can narrow the sphenoethmoidal recess [8].

**How to cite:** Yalcin ED, Ozturk EMA, Bozkaya S (2023) Relationship Between Ostiomeatal Complex Variations and Maxillary Sinus Pathologies in Children and Adolescents Using CBCT. Eur J Ther. 29(2):221-232. <https://doi.org/10.58600/eurjther.20232902-1609.y>

**Corresponding Author:** Eda Didem Yalcin E-mail: [didemyalcn@gmail.com](mailto:didemyalcn@gmail.com)

**Received:** 24.05.2023 • **Accepted:** 04.06.2023 • **Published Online:** 04.06.2023

Concha bullosa (CB) is the pneumatized structure of the middle concha that does not normally contain air [9].

Agger nasi cell (ANC) is formed by the pneumatization of the anterior ethmoid cells into the frontal process of the maxilla [3, 10].

Haller cells (HC), which are formed by the migration of posterior ethmoid cells to the maxillary sinus, are air cells above and adjacent to the maxillary sinus ostium [3, 10].

Onodi cells (OC), also called sphenoid cells, are posterior ethmoid air cells localized in the upper anterior region of the sphenoid sinus [10].

Primary maxillary ostium is an essential structure in the drainage of maxillary sinuses [11]. The accessory maxillary ostium (AMO), located between the uncinat process and the inferior concha and originating from the membranous area of the medial wall of the maxilla, is an anatomical variant that may play a role in the development of maxillary sinusitis [12].

CBCT is one of the most preferred imaging systems to evaluate the anatomical structure of the head and neck region in three dimensions. It is recommended to use CBCT in determination of pathological conditions, developmental anomalies, traumatic injuries, impacted and supernumerary teeth in children and adolescents [13]. It has advantages such as lower radiation dose, less scattered radiation and high image quality compared to CT [14]. Besides, shorter exposure time prevents cooperation difficulties and movement artifacts that may occur in children and adolescents [15]. Maxillary sinus pathologies, ethmoid sinuses and surrounding anatomical structures can be examined in detail with CBCT [16].

There are several studies to determine the prevalence of chronic sinusitis by examining the frequency of anatomical variations of OMC using paranasal CT images in the child and adolescent population [3, 8, 17, 18]. However, as far as we know, in only one study conducted by Shokri et al. [19], this subject was investigated

on CBCT scans, although their study sample included not only pediatric patients but also adults. Therefore, the aim of this study is to retrospectively evaluate the relationship of OMC variations with each other and with maxillary sinus pathologies using CBCT in pediatric patients.

## METHODS

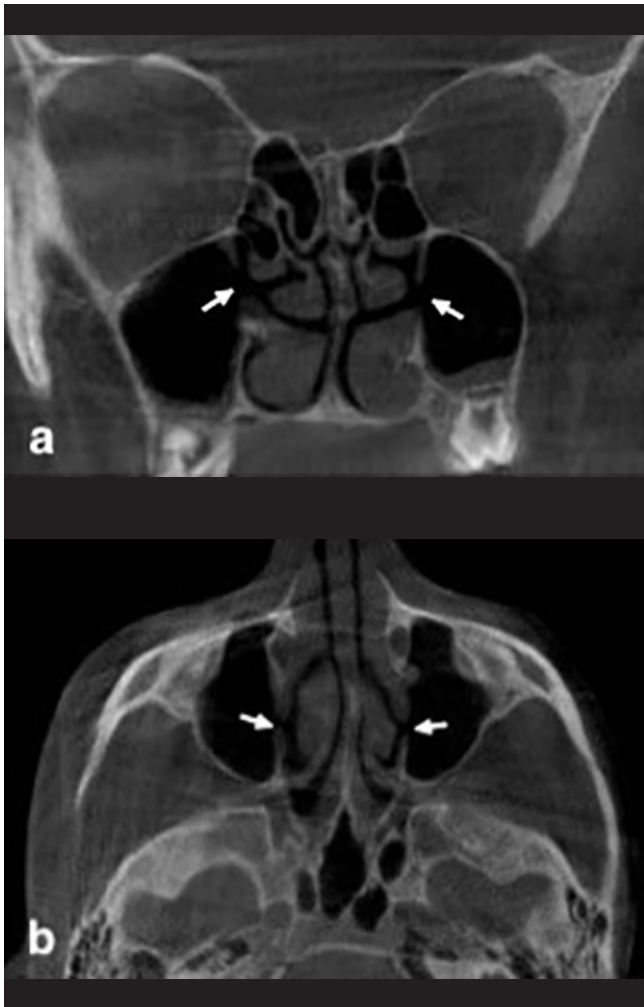
Before the study, the ethical approval was obtained from Clinical Researches Ethics Committee of Gaziantep University (Protocol No: 2020/358). In this study, the images taken with Planmeca Promax 3D (Helsinki, Oy, Finland) CBCT device between 2017-2020 in the Gaziantep University Faculty of Dentistry, Department of Dentomaxillofacial Radiology tomography archive with asymptomatic children and adolescents who underwent CBCT for any dental reason were used. Before the study, "Power Analysis" was carried out so that the data to be obtained from the study could be used and evaluated. The minimum sample size to be examined (number of images) was found to be 68 when  $\alpha=0.05$  and test power  $1-\beta=0.80$ . Multiplanar images were obtained from 16x9, 16x16 FOV (field of view) with 0.4 mm<sup>3</sup> voxel size and 1 mm slice thickness. Inclusion criteria were CBCT images in which the paranasal sinuses could be examined in the study area and no distortion, magnification, artifact, and foreign bodies were seen. Exclusion criteria; syndrome and facial growth disorder, presence of metabolic disease involving the bone, presence of cyst, tumor and fracture line in the examination area, presence of cyst affecting the maxillary sinuses, tumor and trauma in the maxillofacial region, odontogenic infection. CBCT scans of 72 patients (44 males and 28 females) aged 7-18 (mean age: 14.65±2.88 years) were evaluated retrospectively.

## Image Analysis

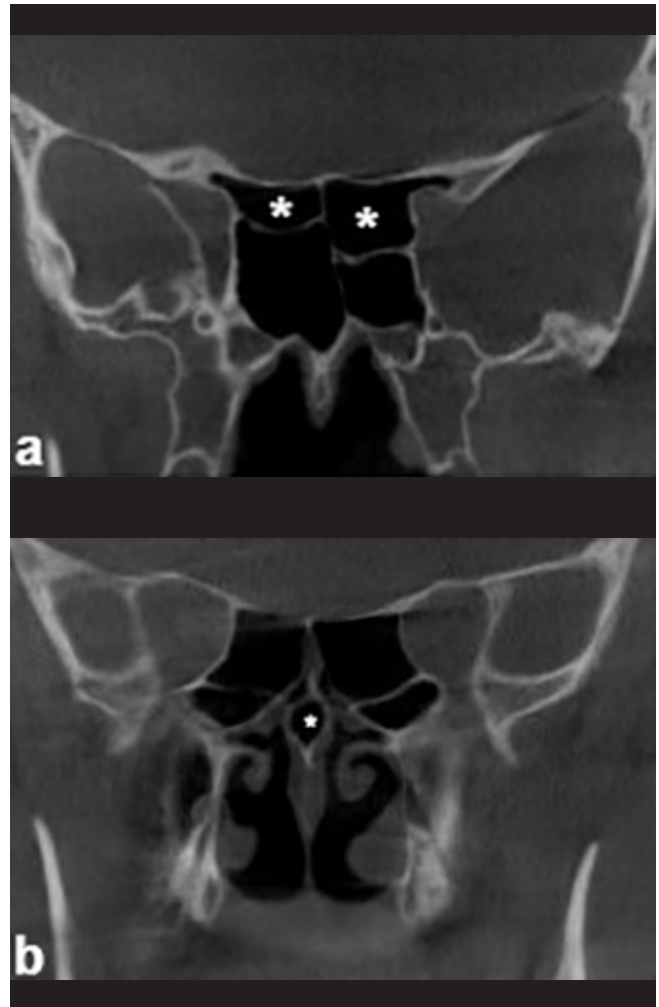
Romexis software **version 11.5** (Helsinki, Oy, Finland) was used to analyze the images. On CBCT images, the presence of AMO (Figure 1), NSD (Figure 2), CB (Figure 2), NSP (Figure 3), OC (Figure 3), HC (Figure 4) and ANC (Figure 5) were investigated. Inflammation of the paranasal sinus membranes is called 'sinusitis' [20]. The accumulation of secretions accompanying ethmoid sinusitis narrows the air space, causing it to appear radiopaque. Inability to distinguish the thin outer walls of ethmoid air cells is an important symptom of ethmoid sinusitis (Figure 6a, 6c) [21]. Mucosal thickening is inflammatory changes in the mucosal inner surface of the paranasal sinuses. It is usually asymptomatic and is the most common pathology in the maxillary sinus. If the membrane thickness is between 2-3 mm, it is thought that there is mucosal thickening, if it is more, other pathologies. When mucosal thickening is seen in one or several walls of the maxillary sinus, localized mucosal thickening (Figure 6a), generalized mucosal thickening (Figure 6a) when it is present in all of its walls, and mucosal thickening that occurs in the form of a dome in the maxillary sinus wall is called polypoidal mucosal thickening (Figure 6b) [22, 23]. Sinus opacification is used to describe the unilateral or bilateral partial (Figure 6c) or total opacification (Figure 6d) of the maxillary sinus. In inflammatory diseases, fungal infections, mucocoeles, mucosal retention cysts and benign neoplasms in the maxillary sinus are replaced by air with a complete radiopaque appearance [24].

### Main Points:

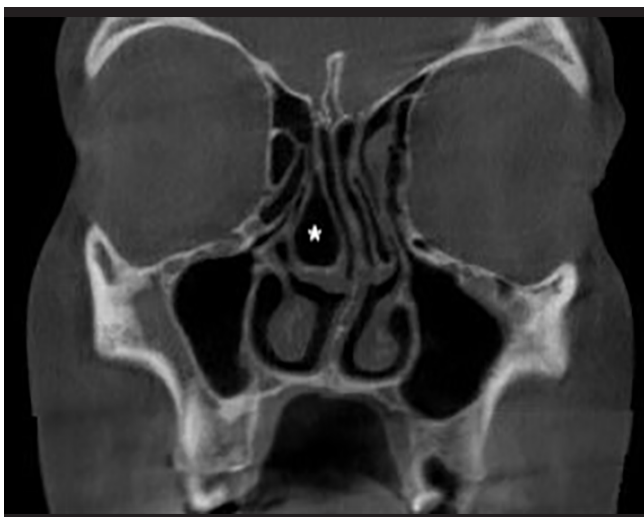- Most of anatomical variations of the ostiomeatal complex in children and adolescents were not associated with maxillary sinus pathology, however, there was a statistically significant relationship between nasal septal pneumatization, accessory maxillary ostium and maxillary sinus pathology.
- Most of anatomical variations in ostiomeatal complex were significantly associated with each other.
- These variations can be visualized with the use of cone-beam computed tomography in children and adolescents with low radiation dose and high image quality compared to computed tomography.



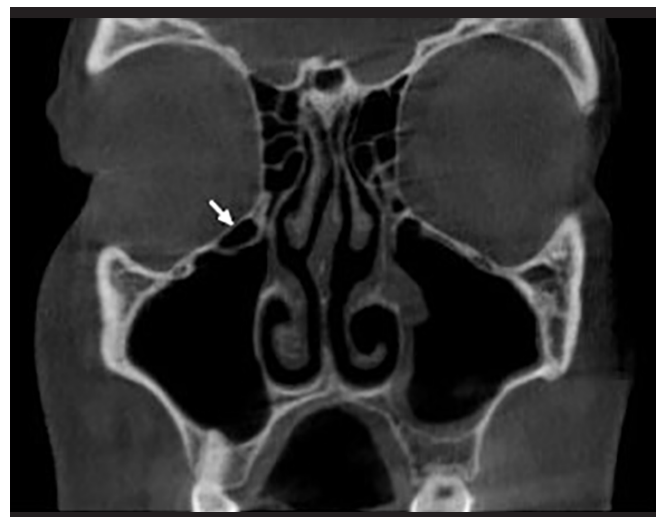**Figure 1.** Coronal (a) and axial (b) CBCT images show right and left accessory maxillary ostium (white arrows). Coronal CBCT image demonstrates mucosal thickening localized in the left maxillary sinus.



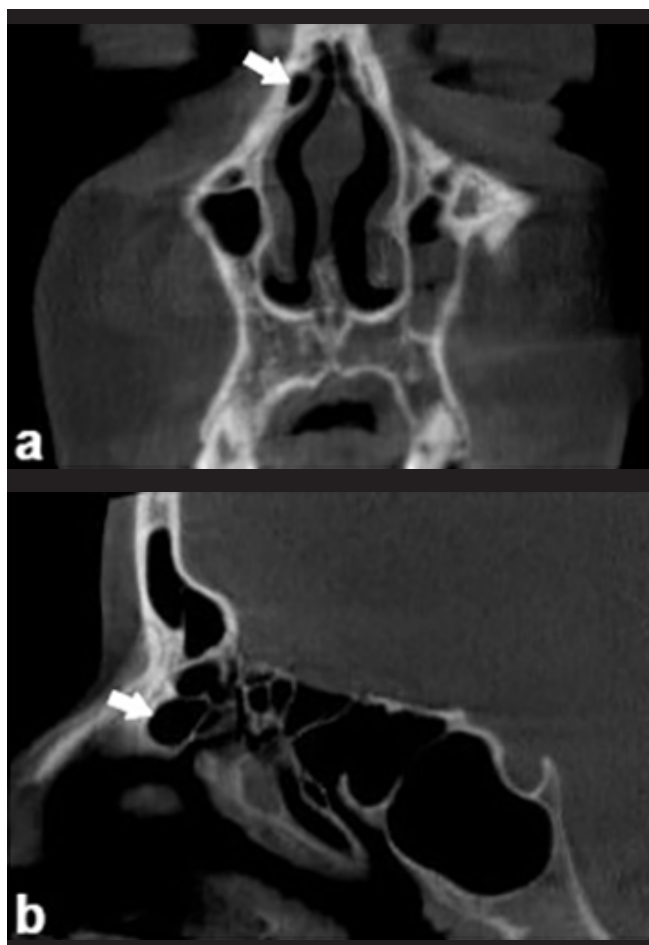
**Figure 3.** On coronal CBCT images: a) right and left Onodi cells (asteriks); b) nasal septal pneumatization (star).



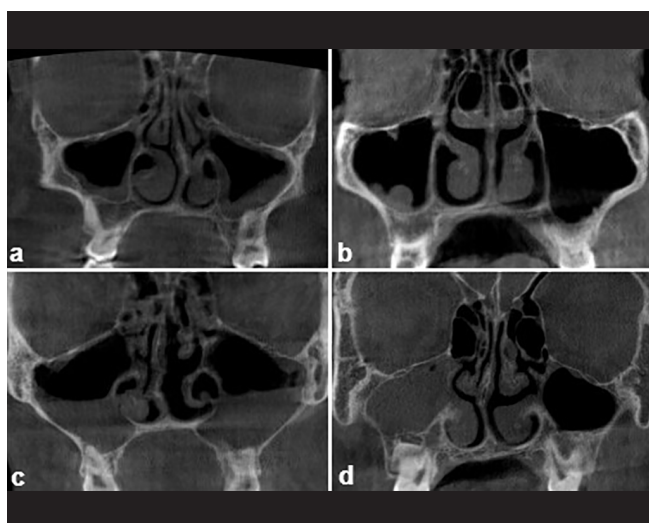
**Figure 2.** Coronal CBCT image shows a large concha bullosa (asteriks) on the right and nasal septal deviation to the left.



**Figure 4.** Coronal CBCT image demonstrates the right Haller cell (white arrow) and localized mucosal thickening in the left maxillary sinus.



**Figure 5.** Coronal (a) and sagittal (b) CBCT images indicate right agger nasi cell (white arrows).



**Figure 6.** Maxillary sinus pathologies on coronal CBCT images: a) ethmoid sinusitis and mucosal thickening localized in the right maxillary sinus, generalized mucosal thickening in the left maxillary sinus; b) polypoidal mucosal thickening in the right maxillary sinus; c) ethmoid sinusitis and partial opacification in the right and left maxillary sinuses; d) total opacification in the right maxillary sinus.

The existence of ethmoid sinusitis and maxillary sinus pathologies were analyzed. Maxillary sinus pathologies were classified as localized mucosal thickening, generalized mucosal thickening, polypoidal mucosal thickening, partial opacification and total opacification (Figure 6). All evaluations were performed by two dentomaxillofacial radiologists, one is research assistant (EMAO), the other with nine year experience (EDY). When disagreement existed among the observers, consensus was reached by discussion. For intra-examiner calibration and reliability of the evaluations, the images were reviewed by the same observers two weeks after the first evaluation.

**Statistical Analysis**

The kappa statistics was applied to calculate the inter-observer and intra-observer agreement. The Chi-square test was used to examine the relationships among the categorical variables. SPSS software version 22.0 (IBM Corp, Armonk, NY) was used to analyze the data. Statistical significance was accepted as  $p < 0.05$ .

**RESULTS**

The coefficient of intra and inter-observer reliability for all assessments was found to be excellent (0.93 and 0.88, respectively). A total of 72 CBCT images of 44 (61.1%) males and 28 (38.9%) females (with a mean age of  $14.23 \pm 3.17$  and  $15.32 \pm 2.25$ , respectively) were investigated. NSD was observed in 70.8%, NSP in 40.3%, and ethmoid sinusitis in 75% of the images examined. The direction of the NSD was 33.3% on the right and 37.5% on the left. The frequency of OMC variations and pathologies are shown in Table 1.

**Table 1.** The frequency of anatomical variations and sinus pathologies.

Variables	Right		Left	
	Present N (%)	Absent N (%)	Present N (%)	Absent N (%)
Concha Bullosa	24 (33.3)	48 (66.7)	21 (29.2)	51 (70.8)
Accessory Maxillary Ostium	13 (18.1)	59 (81.9)	10 (13.9)	62 (86.1)
Agger Nasi Cell	13 (18.1)	59 (81.9)	10 (13.9)	62 (86.1)
Haller Cell	23 (31.9)	49 (68.1)	12 (16.7)	60 (83.3)
Onodi Cell	10 (13.9)	62 (86.1)	17 (23.6)	55 (76.4)
	Present N (%)		Absent N (%)	
Nasal Septum Deviation	51 (70.8)		21 (29.2)	
Nasal Septum Pneumatization	29 (40.3)		43 (59.7)	
Ethmoid Sinusitis	54 (75.0)		18 (25.0)	
Maxillary Sinus Pathology	50 (34.8)		94 (65.3)	

When the OMC variations were examined according to sex, a statistically significant difference was found between the presence of ethmoid sinusitis (p=0.026) and maxillary sinus pathology on the left side with sex (p=0.041). The existence of ethmoid sinusitis and on the left side, the absence of maxillary sinus pathology were significantly higher in males than in females. Distribution of OMC variations by sex is demonstrated in Table 2. The distribution of the classification of maxillary sinus pathologies on the right and left is shown in Table 3. The most common maxillary sinus pathology was localized mucosal thickening with a rate of 15.3% on the right and 22.2% on the left. This is followed by polypoidal mucosal thickening and partial opacification.

In the assessment of the relationship between OMC variations with each other, there was no statistically significant difference between NSD with NSP, ethmoid sinusitis, CB, AMO, ANC, HC and maxillary sinus pathology (p>0.05), while a significant

difference was found between NSD and OC (p=0.028). In the absence of left OC, the rightward orientation of the NSD was observed significantly more. There was no statistically significant difference between NSP with NSD, ethmoid sinusitis, ANC and HC (p>0.05). However, in the absence of NSP, significant difference was determined between the absence of left CB (p=0.018), the absence of right AMO (p=0.043), and the absence of right maxillary sinus pathology (p=0.044). There was no statistically significant difference between ethmoid sinusitis and ANC with all other parameters (p>0.05). No statistically significant difference was found between CB with NSD, ethmoid sinusitis, AMO, ANC, HC and maxillary sinus pathology (p>0.05). There was no statistically significant difference between AMO with NSD, ethmoid sinusitis, CB, ANC and HC (p>0.05). A statistically significant difference was determined between the absence of left AMO, absence of left OC (p=0.034) and absence of left maxillary sinus pathology (p=0.030).

**Table 2.** Distribution of osteomeatal complex (OMC) variations by gender.

Right		Female		Male		P
		Present N (%)	Absent N (%)	Present N (%)	Absent N (%)	
	Concha Bulloza	11 (15.3)	17 (23.6)	13 (18.1)	31 (43.1)	0.393
	Accessory Maxillary Ostium	3 (4.2)	25 (34.7)	10 (13.9)	34 (47.2)	0.196
	Agger Nasi Cell	4 (5.6)	24 (33.3)	5 (6.9)	39 (54.2)	0.715
	Haller Cell	9 (12.5)	19 (26.4)	16 (22.2)	28 (38.9)	0.714
	Onodi Cell	6 (8.3)	22 (30.6)	10 (13.9)	34 (47.2)	0.897
	Maxillary Sinus Pathology	7 (9.7)	21 (29.2)	15 (20.8)	29 (40.3)	0.414
Left		Present N (%)	Absent N (%)	Present N (%)	Absent N (%)	P
	Concha Bulloza	8 (11.1)	20 (27.8)	13 (18.1)	31 (43.1)	0.929
	Accessory Maxillary Ostium	4 (5.6)	24 (33.3)	6 (8.3)	38 (52.8)	0.938
	Agger Nasi Cell	2 (2.8)	26 (36.1)	5 (6.9)	39 (54.2)	0.556
	Haller Cell	8 (11.1)	20 (27.8)	12 (16.7)	32 (44.4)	0.905
	Onodi Cell	8 (11.1)	20 (27.8)	9 (12.5)	35 (48.6)	0.429
	Maxillary Sinus Pathology	15 (20.8)	13 (18.1)	13 (18.1)	31 (43.1)	0.041*
		Female		Male		P
		Present N (%)	Absent N (%)	Present N (%)	Absent N (%)	
	Nasal Septal Deviation	17 (23.6)	11 (15.3)	34 (47.2)	10 (13.9)	0.132
	Nasal Septal Pneumatization	12 (16.7)	16 (22.2)	17 (23.6)	27 (37.5)	0.722
	Ethmoid Sinusitis	17 (23.6)	11 (15.3)	37 (51.4)	7 (9.4)	0.026*

Chi-square test; \*p < 0.05

**Table 3.** Distribution of maxillary sinus pathologies.

Classification of Maxillary Sinus Pathology	Right N (%)	Left N (%)
Generalized Mucosal Thickening	0 (0.0)	2 (2.8)
Localized Mucosal Thickening	11 (15.3)	16 (22.2)
Polypoidal Mucosal Thickening	5 (6.9)	5 (6.9)
Partial Opacification	3 (4.2)	5 (6.9)
Total Opacification	3 (4.2)	0 (0.0)
Absent	50 (69.4)	44 (61.1)
Total	72 (100)	72 (100)

There was no statistically significant difference between HC with NSD, NSP, ethmoid sinusitis, CB, AMO, ANC and maxillary sinus pathology ( $p>0.05$ ). There was only a significant difference between the absence of left HC and absence of left OC ( $p=0.035$ ). There was no statistically significant relationship between OC with NSP, ethmoid sinusitis, CB, ANC and maxillary sinus pathology ( $p>0.05$ ). There was no statistically significant relationship between maxillary sinus pathology with NSD, ethmoid sinusitis, CB, ANC, HC and OC ( $p>0.05$ ). Correlations between anatomical variations are indicated in Table 4 and Table 5. Considering the relationship between the classification of maxillary sinus

pathologies and anatomical variations, a significant relationship was observed between left AMO and maxillary sinus pathologies ( $p=0.002$ ).

When the anatomical variations of OMC were compared on the right and left sides, a significant difference was found between two sides in the CB ( $p < 0.001$ ), AMO ( $p < 0.05$ ), OC ( $p < 0.001$ ), and maxillary sinus pathologies ( $p=0.025$ ). The difference in all these relationships is that in the absence of the parameter on the right, there is absence of the parameter on the left.

**Table 5.** Correlations between anatomical variations of ostiomeatal complex (OMC) and maxillary sinus pathologies.

		Right Maxillary Sinus Pathology		P			Left Maxillary Sinus Pathology		P
		Present N (%)	Absent N (%)				Present N (%)	Absent N (%)	
Right					Left				
Concha Bullosa	Present N (%)	7 (9.7)	17 (23.6)	0.856	Concha Bullosa	Present N (%)	10 (13.9)	11 (15.3)	0.330
	Absent N (%)	15 (20.8)	33 (45.8)			Absent N (%)	18 (25.0)	33 (45.8)	
Accessory Maxillary Ostium	Present N (%)	6 (8.3)	7 (9.7)	0.177	Accessory Maxillary Ostium	Present N (%)	7 (9.7)	3 (4.2)	0.030*
	Absent N (%)	16 (22.2)	43 (59.7)			Absent N (%)	21 (29.2)	41 (56.9)	
Agger Nasi Cell	Present N (%)	3 (4.2)	10 (13.9)	0.518	Agger Nasi Cell	Present N (%)	5 (6.9)	5 (6.9)	0.437
	Absent N (%)	19 (26.4)	40 (55.6)			Absent N (%)	23 (31.9)	39 (54.2)	
Haller Cell	Present N (%)	6 (8.3)	17 (23.6)	0.573	Haller Cell	Present N (%)	4 (5.6)	8 (11.1)	0.665
	Absent N (%)	16 (22.2)	33 (45.8)			Absent N (%)	24 (33.3)	36 (50.0)	
Onodi Cell	Present N (%)	4 (5.6)	6 (8.3)	0.485	Onodi Cell	Present N (%)	7 (9.7)	10 (13.9)	0.825
	Absent N (%)	18 (25.0)	44 (61.1)			Absent N (%)	21 (29.2)	34 (47.2)	

Chi-square test; \* $p < 0.05$

**Table 4.** Correlations between anatomical variations of ostiomeatal complex (OMC).

	RIGHT						LEFT					
	Concha Bullosa	Accessory Maxillary Ostium	Agger Nasi Cell	Haller Cell	Onodi Cell	Maxillary Sinus Pathology	Concha Bullosa	Accessory Maxillary Ostium	Agger Nasi Cell	Haller Cell	Onodi Cell	Maxillary Sinus Pathology
	P	P	P	P	P	P	P	P	P	P	P	P
<b>Concha Bullosa</b>	*****	0.386	0.665	0.074	0.335	0.856	*****	0.151	0.417	0.297	0.980	0.330
<b>Accessory Maxillary Ostium</b>	0.386	*****	0.062	0.225	0.475	0.177	0.151	*****	0.702	0.128	0.034*	0.030*
<b>Agger Nasi Cell</b>	0.665	0.062	*****	0.920	0.110	0.518	0.417	0.702	*****	0.761	0.608	0.437
<b>Haller Cell</b>	0.074	0.225	0.920	*****	0.887	0.573	0.297	0.128	0.761	*****	0.035*	0.665
<b>Onodi Cell</b>	0.335	0.475	0.110	0.887	*****	0.485	0.980	0.034*	0.608	0.035*	*****	0.825
<b>Maxillary Sinus Pathology</b>	0.856	0.177	0.518	0.573	0.485	*****	0.330	0.030*	0.437	0.665	0.825	*****

Chi-square test; \*p < 0.05

## DISCUSSION

In this study, the presence of OMC variations and maxillary sinus pathologies in children and adolescents were examined and the relationships of the variations with maxillary sinus pathologies were investigated using CBCT images. Although there are many studies in the literature on anatomical variations and chronic sinusitis in pediatric patients, [3,8,17,25,26] as far as we know, our study is the first CBCT study to classify maxillary sinus pathologies and examine their relationship with OMC in the children. In this study, the most common observed pathologies in the OMC were maxillary sinus pathologies and ethmoid sinusitis which are also the most common pathologies in males, and the most common variation was CB in this region. Significant relationship was found between AMO and maxillary sinus pathologies.

CBCT is preferred as an alternative to CT in the examination of craniofacial anomalies and pathologies. Compared to CT, the presence of isotropic voxels in CBCT prevents distortion in multi-plane reconstruction images, and the lower radiation dose compared to CT is an important advantage [27]. The use of CBCT in children is controversial due to the radiation dose and immature anatomical and biological structures and their greater susceptibility to radiation damage [28,29]. Dentists should adhere to the principles of ALARA (as low as reasonably achievable) and ALARP (as low as reasonably feasible), an appropriately sized imaging field should be used, and the radiation dose should be kept at the optimum level to solve clinical problems. The dosage should be adjusted and limited according to the age and body weight of the child. CBCT should not be used routinely for children and adolescents, but rather for undiagnosed complex cases such as bone disorders of the temporomandibular joint, presence of oral and maxillofacial pathology, evaluation of impacted teeth, and orthodontic problems [30]. This study was conducted by retrospectively evaluating the available images of patients aged 7-18 years, who applied to our clinic and were requested CBCT according to the SEDENTEX-CT [31] guidelines and CBCT indications.

The reported prevalence of NSD in children ranges from 28.9% to 70.8% [19, 32]. There are differences in the prevalence of NSD between studies as various classifications are used and different age groups may show different results [32]. NSD can cause recurrent rhinosinusitis, upper airway infections, and middle ear problems. Aramani et al. [25] detected NSD at a rate of 74.1% in their study on CT images of 54 patients with chronic sinusitis aged 13-70 years. Kim et al. [17] found NSD in 44.3% of the cases in their study with CT images of 113 pediatric patients with chronic sinusitis who underwent endoscopic sinus surgery, and observed that the prevalence of NSD increased with age. Fadda et al. [26] found NSD in 58.5% of the cases on CT images of 140 patients with chronic sinusitis aged 13-77 years. Al-Qudah et al. [8] detected NSD larger than 3 mm in 18% of the cases on CT images of 65 pediatric patients with chronic sinusitis. In the study conducted by Shokri et al. [19] on CBCT images of 250 patients between the ages of 10-55 years, NSD was determined with a rate of 70.8% in patients aged 10-25 years. In our study,

similar to the literature, the frequency of NSD was 70.8%, and no significant relationship was found between sex and NSD.

Sivaslı et al. [3] found NSP in 6% of the cases in their study with CT images of 47 pediatric patients with chronic sinusitis. NSP was determined at a rate of 38% in the study of Al-Qudah et al. [8]. In the study of Shokri et al. [19], NSP was detected at a rate of 64.7%, and a statistically significant relationship was observed between NSD and NSP. In the present study, NSP was detected in 40.7% of the cases. This difference in the literature may be due to the limited number of studies on this subject, differences in ethnic origin, imaging method, and the number of cases. Shokri et al. [19] examined the correlation between NSP and anatomical variations and did not find statistically significant results, and in our study, different from the literature, a significant relationship was followed between NSP with AMO and CB.

When the pathologies in the paranasal sinuses were examined, Kim et al. [17] found the rate of maxillary sinusitis as 95.5%, divided ethmoid sinusitis as anterior ethmoid and posterior ethmoid sinusitis, and they observed it as 91.1% and 68.1%, respectively. They found no statistically significant difference between maxillary sinusitis with NSD and between CB with maxillary and ethmoid sinusitis. In the studies of Sivaslı et al. [3], maxillary sinusitis were observed in 51% of the cases, anterior ethmoid sinusitis in 15% of the cases, posterior ethmoid sinusitis in 16% of the cases. Also, an inverse correlation was found between maxillary sinusitis and the presence of ANC. In the study of Al-Qudah et al. [8], maxillary and anterior ethmoid sinusitis were determined in 46% of the cases, maxillary and posterior ethmoid sinusitis in 29% of the cases, and maxillary sinusitis in only 17% of the cases. Fadda et al. [26] detected maxillary sinusitis in 67.1% of the cases, anterior ethmoid sinusitis in 54.3%, and posterior ethmoid sinusitis in 10% of the cases. In the present study, ethmoid sinusitis was observed in 75% of the cases, maxillary sinus pathologies in 34.7% of the cases, and significant relationship was found between left NSD and left maxillary sinus pathology. Unlike other studies, we examined the presence of sinusitis without separating the ethmoid sinus as anterior ethmoid and posterior ethmoid sinus. This may explained that the frequency of ethmoid sinusitis in our study was more than the other study results. In addition, a significant relationship was detected between NSP with right maxillary sinus pathology. It may be though that the maxillary sinus pathologies may be a factor triggering the formation of NSP due to anatomical proximity.

Kim et al. [17] observed CB at a rate of 32.7% and did not find a significant relationship between CB and ipsilateral ethmoid and maxillary sinusitis. Sivaslı et al. [3] found the rate of CB as 58.0% and Al Qudah et al. [8] remarked it as 51.0%. Sivaslı et al. [3] found a significant relationship between CB and ANC. Al Qudah et al. [8] did not observe a significant relationship between CB and maxillary sinusitis. Köse et al. [33] did not find a statistically significant relationship between CB and NSD and maxillary sinus mucosal thickening. Fadda et al. [26] stated CB with a rate of 49.3% and found a significant relationship between bilateral CB



and bilateral maxillary sinusitis. In our study, CB was observed as 31.3%. Besides, a significant relationship was found between left CB and NSP.

In the study of Ali et al. [34] examining the CBCT images of 201 patients between the ages of 16-85, AMO was detected at a rate of 28.4%. Both AMO and maxillary sinusitis were observed in 71.9% of these patients, and a significant relationship was found between the presence of AMO and maxillary sinusitis. Shokri et al. [19] stated the presence of AMO at a rate of 58.5%, and no significant relationship was found between AMO and sex. In the current study, unlike the other study results, a lower rate of AMO (16%) was found, however, consistent with the literature, no significant relationship was determined between sex. AMO is an anatomical variation associated with the development of maxillary sinusitis in several studies [35-37], and in our study, similar to the literature, a significant relationship was found between left AMO and left maxillary sinus pathologies.

In the study of Kim et al. [17], HC was detected in 34.5% of the cases and 3.5% were on the right, 5.3% were on the left, and 25.7% were bilateral. Also, no significant relationship was observed between HC with maxillary and ethmoid sinusitis. Sivaslı et al. [3] determined HC in 30.0% of the cases, and they concluded that although most patients with HC had maxillary sinus involvement, this relationship was not statistically significant. Al Qudah et al. [8] found HC at a rate of 20.0%, and no significant correlation indicated between HC and maxillary sinusitis. Shokri et al. [19] detected HC at a rate of 69.4% in the group under the age of 25 in their study, and found a significant relationship between HC and NSD. Shpilberg et al. [38] determined HC in 39.1% of the cases and did not remark a significant relationship between HC and sinonasal disease. In the study of Fadda et al. [26], HC was determined at a rate of 22.8%, and found a significant association between HC and maxillary sinusitis. In the present study, HC was observed as 24.3%, and there was no significant correlation between the presence of HC and sex. Since HC is adjacent to the maxillary sinus ostium, it is considered a factor in narrowing of the infundibulum, in this case, recurrent maxillary sinusitis can occur [39, 40]. However, in this study, a significant relationship between HC with maxillary sinus pathology and ethmoid sinusitis was not determined.

The reported prevalence of ANC varies widely among researchers. In the study conducted by Al Quadah and Mardini [41], on CT images of 50 children aged 4-15 years, ANC was detected bilaterally in 94.0% of the cases. Kim et al. [17] observed ANC in 69.0% of the cases and found that the relationship between ANC with frontal sinusitis was not significant. In the study of Sivaslı et al. [3], ANC was detected bilaterally at a rate of 15.0%, and a significant relationship was found between ANC and CB. In addition, an inverse correlation was determined between the presence of ANC and maxillary sinusitis. Al Qudah et al. [8] found ANC at a rate of 63.0% and observed that the relationship between ANC with frontal sinusitis was not significant. Shokri et al. [42] determined ANC in 62.7% of patients under the age of 25, and stated a significant relationship between ANC and HC.

Although the prevalence of OC is uncertain, it is thought to range

from 1.3% to 42% [43]. Kim et al. [17] observed OC in 9.8% of the cases and found that the relationship between OC with sphenoid sinusitis was not significant. Sivaslı et al. [3] detected it as 6.0%, and Fadda et al. [26] as 8.5%. Cohen et al. [18] remarked OC in 15.7% of the cases, and did not find a significant relationship between OC with age groups. However, they found a significant relationship between OC and HC. Shokri et al. [19] determined OC in 57.0% of patients under the age of 25, and observed that there was no significant relationship between OC with other anatomical variations. In the current study, the OC rate was found as 18.8%, and no significant relationship was determined between OC with maxillary sinus pathologies and ethmoid sinusitis.

Anatomical variations in the nose and paranasal sinuses are common in children, and the structure of the paranasal sinuses is also quite different from those in adults. Anatomical variations of the nasal cavity and paranasal sinuses are factors that may contribute to occlusion of the ostiomeatal unit [8]. Obstruction of the OMC can lead to the development of pediatric chronic sinusitis with many reasons such as infection, allergies, immune disorders and mucociliary transport disorders [17]. During endoscopic sinus surgery, which is one of the chronic sinusitis treatments, the optic nerve, orbit, tear drainage system and brain tissues are at greater risk of injury due to the narrow intranasal space and thin bone anatomy in children. Anatomical variation is typically eliminated during surgery in adults, but the risk of abnormal facial bone growth in children may prevent the surgeon from doing this [8, 17]. For this reason, in the diagnosis and treatment phase, knowing and the imaging of anatomical variations of OMC is of great importance in terms of affecting the growth and development of the child, quality of life and preventing surgical complications.

In this study, we revealed that most of the anatomical variations of OMC in children and adolescents were not associated with maxillary sinus pathology and ethmoid sinusitis. This may be due to the anatomical variations not being large enough to cause mechanical occlusion. In addition, age, ethnicity, presence of systemic disease, genetic factors and the imaging method used may cause this. The difference results in the literature may be due to the reasons we mentioned above.

The limitation of this study was that the medical history and systemic diseases of the patients were not known since the study was retrospective. Besides, the sample size in this study is limited because the use of CBCT indication in children and adolescents is limited. In the future studies, the number of subjects can be increased and the cases can be divided into age groups.

## CONCLUSION

In this study, anatomical variations in OMC had no significant effect on maxillary sinus pathology except for NSP and AMO. However, most of these variations were statistically significantly correlated with each other. This may be due to the anatomical variations not being large enough to cause mechanical occlusion. OMC variations are of great importance in endoscopic sinus surgery due to their proximity to the surrounding anatomical

structures. CBCT is a successful imaging method for examining sinonasal region anatomy in children and adolescents with its low radiation dose, high image quality and low cost compared to medical CT.

**Peer-review:** Externally peer-reviewed.

**Informed Consent:** Informed consent is not necessary due to the retrospective nature of this study.

**Conflict of Interest:** The authors have no conflict of interest to declare.

**Financial Disclosure:** The authors declared that this study has received no financial support.

**Author Contributions:** Concept – EDY, EMAO; Design – EDY, EMAO; Supervision – EDY, EMAO, S B; Resources – EDY, EMAO; Materials – EDY, EMAO, S B; Data Collection and/or Processing – EDY, EMAO; Analysis and/or Interpretation – EDY, EMAO, S B; Literature Search – EDY, EMAO; Writing Manuscript – EDY, EMAO; Critical Review – EDY, EMAO, SB.

**Ethical approval:** This retrospective study was approved by the Ethical Committee of Gaziantep University (Decision No: 2020/358) and conducted in the Dentomaxillofacial Radiology Department of Gaziantep University, Faculty of Dentistry.

## REFERENCES

- 1- Ritter L, Lutz J, Neugebauer J, Scheer M, Dreiseidler T, Zinser MJ (2011) Prevalence of pathologic findings in the maxillary sinus in cone-beam computerized tomography. *Oral Surg Oral Med Oral Pathol Oral Radiol Endod.* 111(5):634-640. <https://doi.org/10.1016/j.tripleo.2010.12.007>
- 2- Mamatha H, Shamasundar N, Bharathi M, Prasanna L (2010) Variations of ostiomeatal complex and its applied anatomy: a CT scan study. *Indian J Sci Technol.* 3(8):904-907.
- 3- Sivaslı E, Şirikçi A, Bayazit Y, Gümüşburun E, Erbagci H, Bayram M (2002) Anatomic variations of the paranasal sinus area in pediatric patients with chronic sinusitis. *Surg Radiol Anat.* 24(6):399-404. <https://doi.org/10.1007/s00276-002-0074-x>
- 4- Medina J, Hernandez H, Tom LW, Bilaniuk L (1997) Development of the paranasal sinuses in children. *Am J Rhinol.* 11(3):203-210. <https://doi.org/10.2500/105065897781751857>
- 5- Kennedy DW, Zinreich SJ, Rosenbaum AE, Johns ME (1985) Functional endoscopic sinus surgery: theory and diagnostic evaluation. *Arch Otolaryngol.* 111(9):576-582. <https://doi.org/10.1001/archotol.1985.00800110054002>
- 6- Kretzschmar DP, Kretzschmar CJL (2003) Rhinosinusitis: review from a dental perspective. *Oral Surg Oral Med Oral Pathol Oral Radiol Endod.* 96(2):128-135. [https://doi.org/10.1016/S1079-2104\(03\)00306-8](https://doi.org/10.1016/S1079-2104(03)00306-8)
- 7- Beale TJ, Madani G, Morley SJ (2009) Imaging of the paranasal sinuses and nasal cavity: normal anatomy and clinically relevant anatomical variants. *Seminars in Ultrasound, CT and MRI; WB Saunders.* 30(1):2-16. <https://doi.org/10.1053/j.sult.2008.10.011>
- 8- Al-Qudah M (2008) The relationship between anatomical variations of the sino-nasal region and chronic sinusitis extension in children. *Int J Pediatr Otorhinolaryngol.* 72(6):817-821. <https://doi.org/10.1016/j.ijporl.2008.02.006>
- 9- Tomomatsu N, Uzawa N, Aragaki T, Harada K (2014) Aperture width of the osteomeatal complex as a predictor of successful treatment of odontogenic maxillary sinusitis. *Int J Oral Maxillofac Surg.* 43(11):1386-1390. <https://doi.org/10.1016/j.ijom.2014.06.007>
- 10- Kantarci M, Karasen RM, Alper F, Onbas O, Okur A, Karaman A (2004) Remarkable anatomic variations in paranasal sinus region and their clinical importance. *Eur J Radiol.* 50(3):296-302. <https://doi.org/10.1016/j.ejrad.2003.08.012>
- 11- Kumar H, Choudhry R, Kakar S (2001) Accessory maxillary ostia: topography and clinical application. *J Anat Soc India.* 50(1):3-5.
- 12- Sarna A, Hayman LA, Laine FJ, Taber KH (2002) Coronal imaging of the osteomeatal unit: anatomy of 24 variants. *J Comput Assist Tomogr.* 26(1):153-157.
- 13- Kang B-C, Yoon S-J, Lee J-S, Al-Rawi W, Palomo JM (2011) The use of cone beam computed tomography for the evaluation of pathology, developmental anomalies and traumatic injuries relevant to orthodontics. *Seminars in Orthodontics; WB Saunders.* 17:20-33. <https://doi.org/10.1053/j.sodo.2010.08.005>
- 14- Katheria BC, Kau CH, Tate R, Chen J-W, English J, Bouquot J (2010) Effectiveness of impacted and supernumerary tooth diagnosis from traditional radiography versus cone beam computed tomography. *Pediatr Dent.* 32(4):304-309. PMID: 20836949
- 15- Korbmacher H, Kahl-Nieke B, Schöllchen M, Heiland M (2007) Value of two cone-beam computed tomography systems from an orthodontic point of view. *J Orofac Orthop.* 68(4):278-289. PMID: 17639276
- 16- Naitoh M, Suenaga Y, Kondo S, Gotoh K, Arijii E (2009) Assessment of maxillary sinus septa using cone-beam computed tomography: etiological consideration. *Clin Implant Dent Relat Res.* 11:52-58. <https://doi.org/10.1111/j.1708-8208.2009.00194.x>
- 17- Jun Kim H, Jung Cho M, Lee J-W, Tae Kim Y, Kahng H, Sung Kim (2006) The relationship between anatomic variations of paranasal sinuses and chronic sinusitis in children. *Acta Otolaryngol.* 126(10):1067-1072. <https://doi.org/10.1080/00016480600606681>
- 18- Cohen O, Adi M, Shapira-Galitz Y, Halperin D, Warman M (2019) Anatomic variations of the paranasal sinuses in the general pediatric population. *Rhinology.* 57(3):206-212. PMID: 30778427
- 19- Shokri A, Faradmal MJ, Hekmat B (2019) Correlations between anatomical variations of the nasal cavity and

- ethmoidal sinuses on cone-beam computed tomography scans. *Imaging Sci Dent.* 49(2):103. <https://doi.org/10.5624/isd.2019.49.2.103>
- 20- Fokkens WJ, Lund VJ, Mullol J (2012) European position paper on rhinosinusitis and nasal polyps, A summary for otorhinolaryngologists. *Rhinology.* 50(1):1-12. <https://doi.org/10.4193/rhino12.000>
- 21- White SC, Pharoah MJ (2014) *Oral radiology-E-Book: Principles and interpretation*, Elsevier Health Sciences.
- 22- Pelinsari Lana J, Moura Rodrigues Carneiro P, de Carvalho Machado V (2012) Anatomic variations and lesions of the maxillary sinus detected in cone beam computed tomography for dental implants. *Clin Oral Implants Res.* 23(12):1398-1403. <https://doi.org/10.1111/j.1600-0501.2011.02321.x>
- 23- Rege ICC, Sousa TO, Leles CR (2012) Occurrence of maxillary sinus abnormalities detected by cone beam CT in asymptomatic patients. *BMC Oral Health.* 12:1-7. <https://doi.org/10.1186/1472-6831-12-30>
- 24- Dave M, Loughlin A, Walker E (2020) Challenges in plain film radiographic diagnosis for the dental team: a review of the maxillary sinus. *Br Dent J.* 228(8):587-594. <https://doi.org/10.1038/s41415-020-1524-8>
- 25- Aramani A, Karadi R, Kumar S (2014) A study of anatomical variations of osteomeatal complex in chronic rhinosinusitis patients-CT findings. *J Clin Diagn Res.* 8(10):KC01. <https://doi.org/10.7860/JCDR/2014/9323.4923>
- 26- Fadda G, Rosso S, Aversa S, Petrelli A, Ondolo C, Succo G (2012) Multiparametric statistical correlations between paranasal sinus anatomic variations and chronic rhinosinusitis. *Acta Otorhinolaryngol Ital.* 32(4):244. PMID: 23093814
- 27- Farman AG, Scarfe WC (2009) The basics of maxillofacial cone beam computed tomography. *Seminars in Orthodontics*, Elsevier. <https://doi.org/10.1053/j.sodo.2008.09.001>
- 28- Scarfe WC, Farman AG, Sukovic P (2006) Clinical applications of cone-beam computed tomography in dental practice. *J Can Dent Assoc.* 72(1):75-80.
- 29- Scarfe WC (2012) Radiation risk in low-dose maxillofacial radiography. *Oral Surg Oral Med Oral Pathol Oral Radiol.* 114(3):277-280. <https://doi.org/10.1016/j.oooo.2012.07.001>
- 30- Affairs ADACoS (2012) The use of cone-beam computed tomography in dentistry: an advisory statement from the American Dental Association Council on Scientific Affairs. *J Am Dent Assoc.* 143(8):899-902. <https://doi.org/10.14219/jada.archive.2012.0295>
- 31- Theodorakou C, Walker A, Horner K, Pauwels R, Bogaerts R, Jacobs Dds R (2012) Estimation of paediatric organ and effective doses from dental cone beam CT using anthropomorphic phantoms. *Br J Radiol.* 85(1010):153-160. <https://doi.org/10.1259/bjr/19389412>
- 32- Šubarić M, Mladina R (2002) Nasal septum deformities in children and adolescents: a cross sectional study of children from Zagreb, Croatia. *Int J Pediatr Otorhinolaryngol.* 63(1):41-48. [https://doi.org/10.1016/S0165-5876\(01\)00646-2](https://doi.org/10.1016/S0165-5876(01)00646-2)
- 33- Köse E, Canger, EM, Göller Bulut D (2018) Cone beam computed tomographic analysis of paranasal variations, osteomeatal complex disease, odontogenic lesion and their effect on maxillary sinus. *Meandros Med Dent J.* 19(4):310. <https://doi.org/10.4274>
- 34- Ali IK, Sansare K, Karjodkar FR, Vanga K, Salve P, Pawar AM (2017) Cone-beam computed tomography analysis of accessory maxillary ostium and Haller cells: Prevalence and clinical significance. *Imaging Sci Dent.* 47(1):33. <https://doi.org/10.5624/isd.2017.47.1.33>
- 35- Bani-Ata M, Aleshawi A, Khatatbeh A, Al-Domaidat D, Alnussair B, Al-Shawaqfeh R (2020) Accessory maxillary ostia: prevalence of an anatomical variant and association with chronic sinusitis. *Int J Gen Med.* 13:163. <https://doi.org/10.2147/IJGM.S253569>
- 36- Yenigun A, Fazliogullari Z, Gun C, Uysal II, Nayman A, Karabulut AK (2016) The effect of the presence of the accessory maxillary ostium on the maxillary sinus. *Eur Arch Otorhinolaryngol.* 273:4315-4319. <https://doi.org/10.1007/s00405-016-4129-8>
- 37- Ghosh P, Kumarasekaran P, Sriraman G (2018) Incidence of accessory ostia in patients with chronic maxillary sinusitis. *Int J Otorhinolaryngol Head Neck Surg.* 4(2):443-447.
- 38- Shpilberg KA, Daniel SC, Doshi AH, Lawson W, Som PM (2015) CT of anatomic variants of the paranasal sinuses and nasal cavity: poor correlation with radiologically significant rhinosinusitis but importance in surgical planning. *AJR Am J Roentgenol.* 204(6):1255-1260. <https://doi.org/10.2214/AJR.14.13762>
- 39- Laine F, Smoker W (1992) The ostiomeatal unit and endoscopic surgery: anatomy, variations, and imaging findings in inflammatory diseases. *AJR Am J Roentgenol.* 159(4):849-857. <https://doi.org/10.2214/ajr.159.4.1529853>
- 40- Stammberger H, Wolf G (1988) Headaches and sinus disease: the endoscopic approach. *Ann Otol Rhinol Laryngol.* 97(5):3-23. <https://doi.org/10.1177/000348948809705501>
- 41- Al-Qudah M, Mardini D (2015) Computed tomographic analysis of frontal recess cells in pediatric patients. *Am J Rhinol Allergy.* 29(6):425-429. <https://doi.org/10.2500/ajra.2015.29.4243>
- 42- Shokri A, Miresmaeili A, Farhadian N, Falah-Kooshki S, Amini P, Mollaie N (2017) Effect of changing the head position on accuracy of transverse measurements of the maxillofacial region made on cone beam computed tomography and conventional posterior-anterior cephalograms. *Dentomaxillofac Radiol.* 46(5):20160180. <https://doi.org/10.1259/dmfr.20160180>

- 43- Bolger WE, Parsons DS, Butzin CA (1991) Paranasal sinus bony anatomic variations and mucosal abnormalities: CT analysis for endoscopic sinus surgery. *Laryngoscope*. 101(1):56-64. <https://doi.org/10.1288/00005537-199101000-00010>