

Diagnoses of false negative Meckel's diverticulum in a 14 month old boy using radioisotope scanning

Ondört aylık bir erkek çocukta yalancı negatif meckel divertikülünün teşhisi

Sabri Zincirkeser¹, Zeki Çelen¹, Mustafa Yılmaz¹, Ercan Sivaslı²

¹Gaziantep Üniversitesi Tıp Fakültesi Nükleer Tıp ABD.

²Gaziantep Üniversitesi Tıp Fakültesi Çocuk Sağlığı ve Hastalıkları ABD.

Abstract

A 14-month-old boy with painless rectal bleeding for two days was referred to our department. He had an equivocal Meckel's diverticulum which showed rapid washout of activity on radioisotope scan. This scintigraphic finding was later confirmed on surgery and histopathologically. Radioisotope scanning with pertechnetate is a simple, non-invasive and valuable test for pre-operative diagnosis of Meckel's diverticulum. However, rapid Tc99m-pertechnetate washout may be one of false negative causes. If in doubt, study should be repeated the next day and it is more convenient to image patient in prone position and dynamic oblique views should be taken.

Key words: Meckel's diverticulum, radionuclide imaging, rapid washout.

Özet

İki gündür ağrısız rektal kanaması olan 14 aylık bir erkek çocukta yapılan sintigrafik tetkikte, hızlı aktivite temizlenmesi gösteren şüpheli Meckel divertikülü görüntümü izlendi. Bu sintigrafik bulgu daha sonra cerrahi ve histopatoloji ile doğrulandı. Ameliyat öncesi Meckel divertikülünün teşhisinde perteknetat ile radyoizotop görüntüleme kolay, noninvaziv ve değerli bir yöntemdir. Ayrıca, hızlı Tc99m - perteknetat temizlenmesi yanlış negatif sebeplerden birisi olabilir ve şüpheli durumlarda çalışma bir sonraki gün prone pozisyonda ve dinamik oblik imajlar alınarak tekrarlanmalıdır.

Anahtar kelimeler: Meckel divertikülü, radyonüklid görüntüleme, hızlı temizlenme.

Gaziantep Üniversitesi Tıp Dergisi 2007, 1:5-7

Introduction

The first comprehensive embryologic and pathologic description of Meckel's diverticulum was made by Johan Friedrich Meckel in 1809 (1). Meckel's diverticulum is present in about 3 percent of the general population. It is a remnant of the omphalomesenteric duct (vitelline duct), that arises from the fetal yolk sac and connects the umbilicus with primitive intestine in an area that will eventually develop into the ileum. This normally occurs during the 5th to 7th week of gestation. It is usually located on the anti-mesenteric border of terminal ileum, 45 cm to 100 cm proximal to the ileocecal valve. It is a true diverticulum as it contains all the layers of intestinal wall. Its length varies from 0.5 to 5.6 cm and has a blood supply independent of that of contiguous ileum. Most Meckel's diverticula are asymptomatic throughout an

individual's life. Less than 20% of the cases of Meckel's diverticulum become symptomatic and may cause bleeding, intussusception, volvulus, diverticulitis, or present as obstruction, perforation or hernia (2,3). These may become symptomatic at any age but 70% of symptomatic patients are below the age of 30 years. Meckel's diverticulum contains normal ileal mucosa in majority of the cases and ectopic mucosa (heterotopic tissue) in remaining cases (2,3). Approximately 25 percent contain ectopic gastric mucosa, and those patients that have a propensity to bleed. The examiner's experience is also important. It appears that future research should focus on upgrading the sensitivity with the detection of smaller areas of gastric mucosa. Detection of up to 1cm² of ectopic gastric mucosa is reported (4).

Rapid Tc99m - Pertechnetate washout in Meckel's diverticulum is one of false negative causes (5). We report here a case of bleeding Meckel's diverticulum which showed rapid washout diagnosed on a radioisotope scan prior to surgery.

Case report

A 14-month-old boy was referred for radioisotope scan for a suspected bleeding Meckel's diverticulum. He had a clinical history of melena for two days.

✉ Yazışma Adresi:

Yrd.Doç.Dr.Sabri Zincirkeser

Gaziantep Üniversitesi Tıp Fakültesi Nükleer Tıp ABD.

Tlf: 0342 3606060-77567

Cep : 05324678353

E mail : szincirkeser@yahoo.com

Passage of clots and traces of blood followed stool. There was no associated complaint of abdominal pain or vomiting and child was feeding normally. Differential diagnosis included bleeding Meckel's diverticulum, angiomalformation and duplication of gut. Abdominal ultrasonography did not reveal any abnormality. At the time of presentation in Nuclear Medicine department, the patient was hemodynamically stable and his systemic review was unremarkable. He has been also taking syrup ranitidine (20mg/kg/ in 3 divided doses) and the last dose was given 1 hour before scanning. Feeding was withheld 4 hours before scanning. Acquisition was started just after the injection of 145 MBq of Tc99m-pertechnetate while patient in supine position and in anterior projection. Sequential images of anterior abdomen at 2 minutes interval were acquired for 30 minutes with oblique views at 45 and 60 minutes. Scan showed Tc99m-pertechnetate uptake in stomach at 5 minutes. At this time there was also radioisotope uptake seen slightly in the right iliac fossa but did not persist as usual Meckel's diverticulum, even it decreased intensity with time. Also there was not any significant activity in oblique views which were acquired at 30 and 45 minutes. The study was repeated the next day. Same activity uptake pattern was seen clearly on early oblique views which obtained the patient in prone position at 5 minutes and disappeared again. It was located anteriorly and away from the urinary tract on oblique views. Therefore, this site of radioisotope secretion in right iliac fossa was reported abnormal and a high probability of a Meckel's diverticulum containing ectopic gastric mucosa. Patient underwent laparotomy after scanning. A Meckel's diverticulum was found that was resected and end to end anastomosis was done. Gross and microscopic examination of the resected tissue confirmed a Meckel's diverticulum 4 cm proximal of ileocecal valve and 3 cm in diameter. Microscopy also showed evidence of ectopic gastric mucosa and focal ulcer.

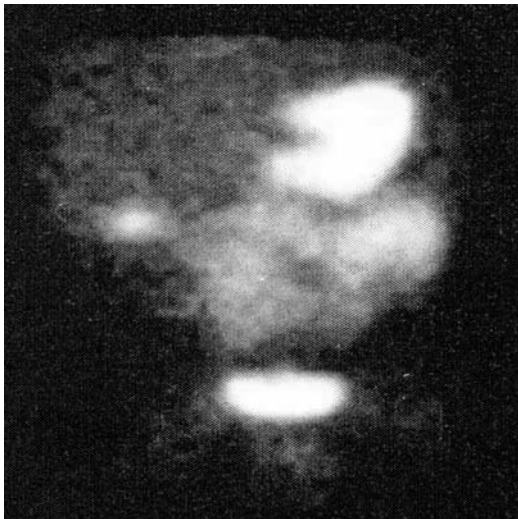


Figure 1. Meckel's diverticulum in a 14-month-old boy

Discussion

Diagnosis of symptomatic Meckel's diverticulum may be problematic (6,7). Routine investigations are not helpful in the diagnosis but do help in the management of these patients. X-ray abdomen and ultrasound are not helpful in the diagnosis of Meckel's diverticulum except where obstruction is the presenting symptom (2,6,7). Technetium-99m-pertechnetate ($^{99m}\text{TcO}_4$) abdominal scintigraphy was initially proposed by Harden et al. in 1967 (8). Jewett et al (9) first reported the use of technetium ($^{99m}\text{TcO}_4$) scanning for demonstration of a Meckel's diverticulum in 1970. Scintigraphic detection of Meckel's diverticulum depends upon the localization of injected pertechnetate within ectopic gastric mucosa contained in the diverticulum (10). Intravenously injected Tc99m-pertechnetate diffuses into the extracellular fluid space and is selectively cleared from the circulation by the thyroid, salivary glands and choroid plexus of the brain and gastric mucosa (10). Thus, this test visualizes gastric mucosa both in the stomach and in ectopic sites e.g., Meckel's diverticulum, esophagus, duplication cysts. Mechanism for gastric affinity and uptake is not entirely clear. In addition, pertechnetate is also secreted into the lumen of gut and is free to move along to adjacent segments of the bowel. The prior use of H₂ blocking agents as in our study reduces the gastric secretion of pertechnetate (11). Overnight fasting also helps in this regard. For acquisition, patient is generally positioned supine with the gamma camera over the abdomen and pelvis. In our opinion, it is more convenient to lie the patient prone on the surface of the camera. Early dynamic phase (angiogram phase) of the study allows detection of the actively bleeding diverticulum and it is also important for an abnormal scan shows an area of pertechnetate uptake that is remote from, but synchronous with the normal gastric mucosa. Most commonly this will be seen in right iliac fossa but it can be almost anywhere in the abdomen.

False positive studies can occur due to renal activity, ureteric activity, transfer of the activity from stomach to the proximal small bowel due to peristalsis, surgically treatable lesions such as abscess, appendicitis, peptic ulceration and hemangioma, or by presence of simple gastric mucosa in gut duplication. Confusion is avoided by assessing time of arrival of activity in the suspected area, whether activity is fixed or moving with time and by acquiring oblique views. For example, renal activity appears early and gradually diminishes as tracer passes into the bladder.

False negative results are obtained in the patients in whom the Meckel's diverticulum does not contain gastric mucosa, due to necrosis of these cells within the diverticulum, activity in normal structures obscuring the abnormal focus, small diverticuli, rapid washout of ^{99m}Tc pertechnetate like our study. In the rapid washout condition, prone position may show more amount activity due to closer patient position to the detector. Therefore, we obtained early oblique, images in prone position in our case.

Meckel's diverticulum radioisotope scanning is a simple, accurate, non-invasive and valuable method with a sensitivity of 85 to 90 percent and a similar specificity for pre-operative diagnosis of Meckel's diverticulum (12-14). It requires an hour to perform, and carries a very low radiation burden. Diagnosis by this non-invasive test helps to prepare the patient for surgery and eliminates the need for emergency exploratory laparotomies. In addition to this, if there is rapid wash-out, care should be taken for avoiding false negative results, if in doubt, study repeated the next day and early dynamic oblique views should be taken in prone position like in our study or glucagon (15) may be used for slowing bowel movements if still in doubt.

References

1. Debartolo HM, Van Heerden JA. Meckel's diverticulum. *Ann Surg* 1976;183:30-33.
2. Mackey WC, Dineen P. A fifty-year experience with Meckel's diverticulum. *Surg Gyne Obstet* 1983;156:56-64.
3. Martin JP, Connar PD, Charles K. Meckel's diverticulum. *Am Fam Physician* 2000;61:1037-42.
4. Papatolios T, Giannoulis E, Theocharidis A. The Scintiscan of Meckel's Diverticulum and its Complications. *Hell J Nucl Med* 2000;3:156-159.
5. Feuerstein IM, Mukherji SK, Leftridge CA False-negative delayed imaging in Meckel's diverticulum. *Clin Nucl Med* 1985;10:889-90.
6. Natta F, Passarelli E, Rosso MV. Meckel's diverticulum personal Experience. *Minerva Chir* 1994;49:529-32.
7. Bemelman WA. Meckel's diverticulum in Amsterdam experience in 136 patients. *World J Surg* 1995;19:734-7
8. Harden R, Alexander WD, Kennedy J. Isotope uptake and scanning of stomach in man with Tc99m-Perthchnetate *Lancet* 1967;1:1305-1307.
9. Jewett TC Jr, Duszynski DO, Allen JE. The visualization of Meckel's diverticulum with 99m Tc-Perthchnetate. *Surgery* 1970;68: 567-70.
10. Sfakianakis GN, Conway JJ. Detection of ectopic gastric mucosa in Meckel's diverticulum and in other aberrations by scintigraphy. *J Nucl Med* 1981;22:647-54.
11. Petrokubi RJ, Baum S, Rhorer GV. Cimetidine administration resulting in improved perthchnetate imaging of Meckel's diverticulum. *Clin Nucl Med* 1978;3:385-8.
12. Menon AA, Memon GA, Ansar AG. Symptomatic Meckel's diverticulum. *JCPSP* 1999;11:476-9.
13. St-Vil, Brandt ML, Panic S. Meckel's diverticulum in children : a 20-year study review. *J Pediatr Surg* 1991; 26:1289-92.
14. Enge I, Dahl F. Radiology in acute abdominal disease due to Meckel's diverticulum. *Br J Radiol* 1964;37:775-80.
15. Necheles H, Sporn J, Walker L. Effect of glucagon on gastrointestinal motility. *Am J Gastroenterol* 1966;45: 34-39.