

Iliac Artery Injury With Foreign Body: A Unique Case Of Child Abuse

Yabancı Cisimle İliak Arter Yaralanması: Nadir Bir Çocuk İstismar Olgusu

Yrd.Doç.Dr. Aysun BARANSEL ISIR¹, Doç.Dr. Mehmet TOKDEMİR², Uzman.Dr. Ergün PARMAKSIZ³
Doç.Dr.Ali RAHMAN⁴, Doç.Dr. Ahmet KAZEZ³

¹Gaziantep University Medical School Department of Forensic Medicine

²Fırat University Medical School Department of Forensic Medicine

³Fırat University Medical School Department of Pediatric Surgery

⁴Fırat University Medical School Department of Heart, Vessel Surgery Medicin

Abstract

The aim of this study is to discuss physical abuse part of a case by presenting a rarely seen injury which is vaginal bleeding 8-month-old girl with an unknown story. At further analyze and operation, she was operated on for a 4.2 cm long foreign body which caused both perforation in the uterus and injury to the right iliac artery. Four days after the operation, she had sudden loss of vision, intracranial bleeding and generalized convulsion. Three months later, it was encountered that she had an amputated distal phalanx in the 5th finger on the right hand. Social and medico-legal management of physical abuse is suboptimal in Turkey. In this way, an emphasis is made on the necessity of subject keeping in mind when injuries without any sufficient reliable data are encountered as the physical abuse.

Key Words: Child abuse, foreign body, iliac artery injury, phalanx amputation.

Özet

Bu çalışmada öyküsü alınmayan ancak vajinal kanama ile acil olarak getirilen 8 aylık bir kız çocuğunun maruz kaldığı nadir bir yaralanma sunularak, konunun fiziksel istismar boyutunu tartışmak amaçlandı. Yapılan ileri tetkikler ve operasyon neticesinde uterus perforasyonu ve sağ iliak arter yaralanmasına neden olduğu görülen 4.2 cm uzunluğunda vajinal yabancı cisim (çöp) tespit edilerek çıkartıldı. Operasyonun 4. gününde ani görme kaybı, beyin kanaması ve buna bağlı generalize konvülsiyon ve 3 ay sonraki kontrolde sağ el 5. parmak distal falanks amputasyonu tespit edildi. Türkiye’de, fiziksel istismar olgularının sosyal ve tıp-hukuk yönetimi yeterli seviyede değildir. Bu nedenle, öyküde yetersizlik veya fiziksel bulgular arasında çelişki tespit edilen yaralanmalarda fiziksel istismarın akılda tutulması gerektiği vurgulanmıştır. **Anahtar Kelimeler:** Çocuk istismarı, yabancı cisim, iliak arter yaralanması, falanks amputasyonu.

Gaziantep Tıp Dergisi 2008, 18-22.

INTRODUCTION

Child abuse is still a clandestine problem in many countries. Child abuse and neglect, which thrives on a variety of factors has been recognized as a major public health issue since 1960s (1). These factors may be related to the child, individual caretakers, families, environment, socioeconomic status, and culture (2). There are several forms of child abuse such as psychological abuse, physical abuse, sexual abuse, and neglect in addition to other varieties including ritual abuse, witnessing domestic violence, or exposure to other dangerous or damaging stimuli that fall under one of the above major categories (3).

In 1985, World Health Organization described child abuse and neglect as “known or unknown behaviors of adults, environment, and country, which influence the physical and psychosocial growth of a child.

Physical abuse is the most frequently confirmed type of child abuse involving acts of caretakers that injure a child. In addition to physical harm, there may be emotional and social consequences of physical abuse, and fatality is not uncommon. The National Center on Child Abuse and Neglect described physical child abuse, which can also be referred to as “non-accidental injury” as: “The physical injury or maltreatment of a child under the age of eighteen by a person who is responsible for the child's welfare under circumstances which indicate that the child's health or welfare is harmed or threatened thereby” (4,5).

✉ Yazışma Adresi:
Yrd. Doç. Dr. Aysun BARANSEL ISIR,
Gaziantep Üniversitesi Adli Tıp AD
Adres: Gaziantep Üniversitesi Tıp Fakültesi
Şehitkamil / Gaziantep
Tel: 0532 701 47 12
Fax: 0342 338 50 00
E-mail: aybaransel@yahoo.com

Inflicted injuries most commonly involve the head including injuries to the face, teeth, eyes, and mouth. Other injuries may occur on genitalia, chest, back, thighs and upper arms (6,7). Among these injuries, head injury is the most important one because of the high risk of fatality involved (8,9).

In the present rare case, the child abuse is characterized by an injury with a foreign body (chip) in vagina that caused uterus perforation and right iliac artery injury. The patient also had old bleeding sites in the cortical and subcortical regions in both sites as well as in the left occipital zone.

CASE REPORT

An 8-month-old girl was referred to Forensic Medicine Clinic by her mother with a complaint of vaginal bleeding for two days. She was a well developed, well nourished ill-appearing infant. Vital signs included heart rate, 148/minute; body temperature, 37.4 C; respiratory rate, 40/minute; and arterial blood pressure, 70/50 mmHg.

On abdominal examination, although there was no pain or defense, a 2x2 cm pulsating mass was palpated in the right lower quadrant. On genital examination, the hymen was intact, but there was fresh blood clot in the vagina. The rest of physical exam was within normal limits including neurologic exam. Laboratory investigation revealed white blood cell count, 24.700/mm³; hemoglobin, 5.4 gr/dL; hematocrit, 16%; platelet count 441.000/mm³.

Pelvic ultrasonography was performed, and revealed a thin wire shaped foreign body in the uterus and a hematoma in the retroperitoneal region on the right side. The foreign body (chip) was hyperechoic and approximately 4 cm in length (Fig. 1).

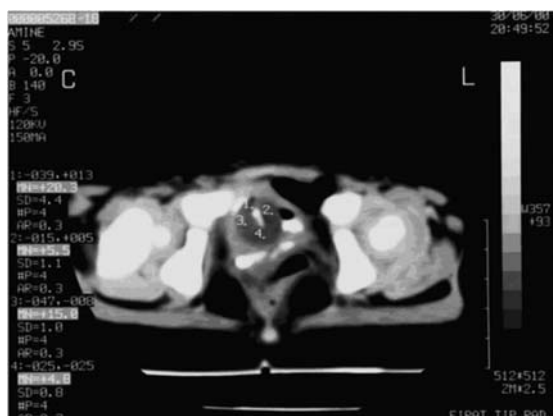


Figure 1. Pelvic ultrasonography. Note the hematoma on right retroperitoneal region.

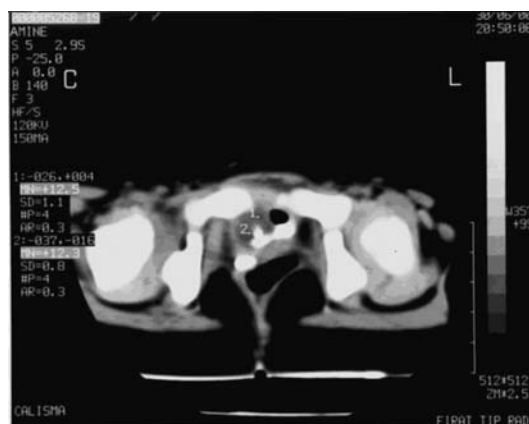

Figure 1. Pelvic tomography. Note the hematoma on right retroperitoneal region.

The patient was transferred to the operating room both for exploration of the abdomen and removal of the foreign body. Rectoscopy revealed no abnormality. On laparoscopy, a 4.2 cm long foreign body (chip) was removed from the uterus. The patient also had uterus perforation and pseudoaneurysm in the right common iliac artery due to penetration by the chip (Fig. 2). The iliac artery pseudoaneurysm was repaired using a 0.5x14 mm graft.

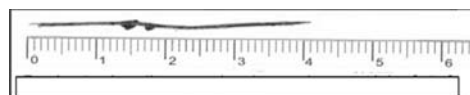


Figure 2. The 4.2 cm in long foreign body (chip) removed from the uterus.

The perforation in the uterus was repaired primarily. The patient had a sudden loss of vision on day four of admission and operation and generalized seizures on day six of admission.

Computed tomography (CT) performed on day four of the brain showed scattered areas of bleeding, infarction and edema in the supratentorial, left occipital, parietooccipital, cortical and subcortical regions (Fig. 3). Repeat head CT on day 12 of admission revealed an infarction zone in the occipital region.

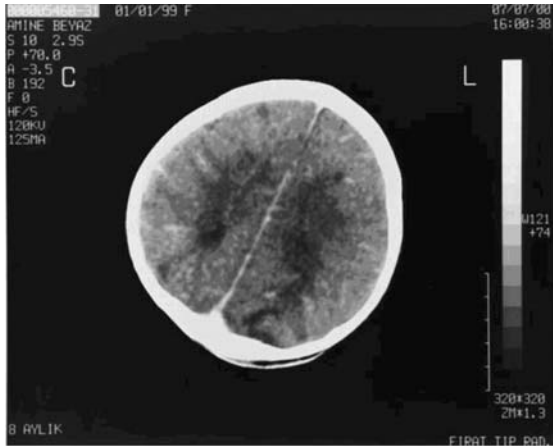

Figure 3. Brain tomography. Note the previous bleeding, edema and infarction zones in the cortical and subcortical regions on both side, and in the left occipital zone.

The patient was treated medically and her symptoms gradually recovered, with subsequent discharge from the hospital on day 13 of the admission. Since pediatric surgery staff did not consider physical abuse in differential diagnosis, Department of Forensic Medicine, Regional Department of Social Services, Law Enforcement Agencies, or Attorney General's Office was not notified.

On follow-up at clinic, three months after discharge, she was noted to have an amputated distal phalanx of the right fifth finger. The parents stated that patient's 6 year old brother caused the amputation. As seen in figure 4, the amputation appeared to be at least four weeks old raising concern for a non-credible explanation for an injury.

The fact that reported history of trauma was inconsistent with the observed injury, concern for physical abuse was raised and consultation from the Department of Forensic Medicine was ordered. Upon the inconsistent testimonies of the parents the situation has been conveyed to the judgment. However due to having, in the region, no organization in this regard, social service specialists could not informed for the event. From the statements of the father who was unemployed during the trial, it was determined that he was unable to sustain the second child because of having low social-economical level, besides the child was borne in unjustly treated condition as the conclusion of unwelcome pregnancy, the father was mentally depressed, the daughters are not being loved as respect to the lived region, he used to have experienced despondency while he glanced over his child, therefore he was in the mood of having a harmful effect on the child.

No information afterward has been obtained as regard to trial conclusion. Based on these findings, she introduced the possibility of physical abuse and recommended consulting of forensic medicine physician.

DISCUSSION

The violence is applied in different forms in child abuse. To call a child "stupid" or "bad", shaking, choking, biting, kicking, burning, poisoning, holding under water, or any other harmful or/and dangerous application of force or restraint are violence. Some of them may result in dead as well. Despite the fact that children have been abused throughout the human history, maltreatment has been a major social problem since the last 40 years. According to some of the studies, the first cause of death among very young children is child abuse (10). In the USA, 2.8 million doubtful abuse cases were investigated between 1986 and 1993, and the physical abuse rate was found to be 20.4% (11-13). In Turkey, child abuse can also be encountered though the accurate rate for this condition is still unclear.

Physical child abuse is seen by the existence of lesions which are formed at different time and characteristics on various parts of the body. However, almost all researchers agree that diagnosis of child abuse is completely based on a detailed history. Despite this contention, it is rather difficult to get a true history because child is usually abused by parents and relatives. After a major trauma, the history given is usually based on an accidental event, which is not true in general (4,5).

The diagnosis of non-accidental injury must be suspected when there is discordance between the history and physical findings. In this case, occurrence of the event could not be understood precisely because it was questionable whether a thorough history could be obtained from the parents. However, the present case seems a form of physical abuse in light of the physical findings of the patient. Anogenital impalement injuries occur rarely. In general, sexual abuse should be considered in the differential diagnosis (14,15).

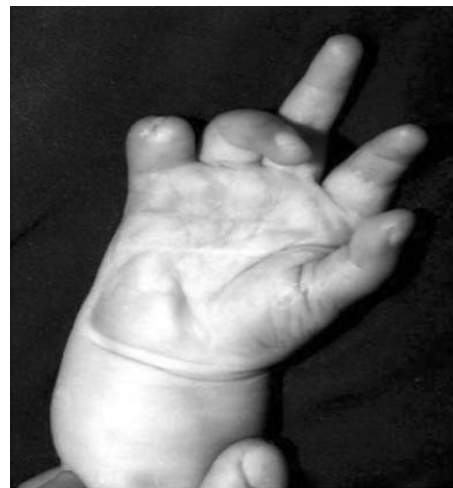

Figure 4. Note the amputated distal phalanx of the 5th finger in the right hand.

The effects caused by using direct blunt forces particularly in the head have been the most frequent causes of death. In child abuse, head injuries are the most common causes of death in children less than 1 year of age (16). The age distribution for abuse cases with head-trauma ranges from 3 weeks to 11 months with an mean age of 4 months (17). The age of the patient in this case is within these limits. The possibility of recurrence and severity of abuse may increased when children return home and are being forced to live with same person or in the same environment (5).

Likewise, our patient also had additional intracranial bleeding sites as well as amputated finger tip in 3 months follow up. Based on these knowledge and our findings, it can be said that it was impossible for the 8-month old infant to insert the foreign body into her uterus, sudden loss of vision, intracranial bleeding and generalized convulsion, and distal phalanx amputation.

Therefore this case was attributed to physical abuse. In this case, when the baby has been brought with vaginal bleeding, it would be a fault to think about the case is a child physical abuse. So in these cases, history should be taken and physical examination should be performed properly, when the child abuse is detected in its earliest phase. Close observation is needed for the possibility of recurrent abuse. Early detection of an abuse may prevent fatal complications.

Although it was deemed that, even though it was late, our case has been subjected to the physical abuse, no information has been able to provided to any social service institution in respect to the protection of the be said child. It is pity that this situation is one of the samples indicating that unavailability of sufficient organization in our country, as regard to child abuse. For this reason, Turkey is in need of significant remodeling in legal, social, and medical management of child abuse and neglect. Institutions and governments should provide physical, psychological, security and educational support for abused children.

Child abuse is mostly seen in the families with low socioeconomic level, especially, in non-educated families (18). It was suggested that there may be a strong relation between child abuse and poverty (19). In this case, the unemployed father was considered to be an important factor involved in the abuse.

There must be multidisciplinary approach involving all of the professionals, doctors, legal specialists, nurses and social assistants for this kind of child abuse. Especially, when there is an incompatibility between the story and the physical findings, and when there are lesions happened at different times and places when there is a suspicious case, "the diagnosis of non-accidental injury, child abuse, must always kept in mind by everyone". Consequently, a different and new lesion to physical abuse on infant and child which is presented in this study is considered as an unique and interesting child abuse.

REFERENCES

1. Kempe CH, Silverman FN, Steele BF, Droegemuller W, Silver HK. The battered child syndrome. *JAMA*. 1984;251:3288-3294.
2. Belsky J. Child Maltreatment: An ecological integration. *Am Psychol*. 1980;35:320-335.
3. Cicchetti D, Carlson VK. Child Maltreatment. Theory and research on the causes and consequences of child abuse and neglect. Cambridge. 1989.
4. Kaplan HI, Sadock BJ. *Comprehensive Textbook of Psychiatry*. Baltimore: Williams and Wilkins. 1999.
5. Leonardi DF, Vedovato JW, Werlang PM, Torres OM. Child burn: accident, neglect or abuse. A case report. *Burns* 1999;25(1):69-71.
6. Ledbetter DJ, Hatch EI, Feldman KW, Ligner CL, Tapper D. Diagnostic and surgical implications of child abuse. *Arch Surg*. 1988;123:1101-1105.
7. Ellerstein NS. Cutaneous manifestations of child abuse and neglect. *Am J Dis Child*. 1979;133:906-909.
8. Meservy CJ, Towbin R, McLauren RL, Myers PA, Ball W. Radiographic characteristics of skull fractures resulting from child abuse. *Am J Radiol*. 1987;149:173-175.
9. Hiss J, Kahana T. The medicolegal implications of bilateral cranial fractures in infants. *J Trauma*. 1995;38:32-34.
10. Acik Y, Deveci SE, Yildirim AM, Okur Mİ. Bir Fiziksel İstismar Olgusu. *Cocuk Forumu*. 1999;2:18-22.
11. Murry SK, Baker AW, Lewin L. Screening Families with Young Children for Child Maltreatment Potential. *Pediatr Nurs*. 2000;26(1):47-54.
12. Guler N, Uzun S, Boztas Z, Aydogan S. The Behaviours of Mothers who Perform Physical or Emotional Abuse/Neglect of Their Children. *Cukurova Universitesi Tip Fakultesi Dergisi*. 2002;24(3):128-134.
13. Cowen PS. Child neglect; Injuries of Omission. *Pediatr Nurs*. 1999;25(4):401-418.
14. Rothamel T, Burger D, Debertain AS, Kleemann WJ. Vagino-rectal impalement injury in a 2 year old child caused by sexual abuse or an accident? *Forensic Sci Int*. 2001;119(3):330-333.
15. Ozkara E, Karatosun V, Gunal I, Oral R. Trans-metatarsal amputation as a complication of child sexual abuse. *J Clin Foren Med*. 2004;11:129-132.

16.Bar-on ME, Zanga JR. Child Abuse: a model for the use of structured clinical forms. *Pediatrics*. 1996;98:429-433.

17.Billmire ME, Myers PA. Serious Head Injury in Infants: Accident or Abuse? *Pediatrics*. 1985;75:340-342.

18.Çolođlu S, Kulusayın O. Dövmüş Çocuk Sendromu. *Adli Tıp Dergisi*. 1985;1(2):179-185.

19. Pelton L. Child abuse and neglect the myth of classlessness. *Am J Orthopsychiatry*. 1978;48:608-617.