






Unilateral *Brucella* Dacryoadenitis

Alper Mete¹ , Ayşe Özlem Mete² , Sabit Kimyon¹ , İbrahim Edhem Yılmaz¹ ,
Necdet A Bekir¹ 

¹Department of Ophthalmology, Gaziantep University School of Medicine, Gaziantep, Turkey

²Clinic of Infectious Diseases, Gaziantep 25 Aralık Public Hospital, Gaziantep, Turkey

ABSTRACT

Brucellosis is a multi-systemic disease with the involvement of several organs and tissues. Ocular brucellosis is a rare type of the disease and manifests most commonly with uveitis, choroiditis, keratitis, and optic neuropathy. Here we report a 49-year-old female, who presented with unilateral dacryoadenitis. Ocular examination, magnetic resonance imaging of the orbits, serology, and blood culture confirmed the diagnosis of brucellosis. Rifampicin and ciprofloxacin were given to the patient for 6 weeks. At the first month control examination, patient's ocular findings was completely resolved. Therefore we suggest that brucellosis should be considered in the differential diagnosis of patients with dacryoadenitis, particularly in endemic regions.

Keywords: Brucellosis, dacryoadenitis, ocular brucellosis

INTRODUCTION

Brucellosis is a zoonotic disease and is a serious health care problem in some regions, such as the Middle East, Mediterranean, and Central and South American regions. In most developed countries, it has been eradicated or is under control (1). Four species are found to infect humans: *Brucella melitensis*, *B. abortus*, *B. canis*, and *B. suis*. The most commonly isolated pathogen is *B. melitensis*, which is known to be the most virulent species (2). Turkey is also an endemic country, especially in its middle and southeastern regions (3). Usually, the microorganisms are transmitted to humans via the gastrointestinal tract from unpasteurized dairy products. Individuals belong to some occupations, such as farmers and veterinarians, can be directly infected by contact of the skin, blood, or conjunctiva (4).

Brucellosis is a multi-systemic disease with many organ and tissue involvement, which makes it a diagnostic challenge (5). Ocular brucellosis is a rare type of the disease and manifests most commonly with uveitis, choroiditis, keratitis, optic neuritis, and optic neuropathy (5-9).

Here we report a case of unilateral dacryoadenitis caused by brucellosis, which was confirmed by serology. To the best of our knowledge, only a few brucellosis-related dacryoadenitis cases have been reported in existing literature.

CASE PRESENTATION

A 49-year-old female Caucasian presented to the Ophthalmology Department of Gaziantep University School of Medicine with complains of slight pain and swelling in the superotemporal region of the right eye for a month. She also had a history of fever, malaise, generalized arthralgia, sweating, and lower back pain lasting for 6 months. She had been treated for 2 months due to brucellosis. However, it was not properly controlled because of inappropriate use of drugs on account of socioeconomic problems.

Complete ocular examination was performed. Her right eyelid was displaced temporally with mild proptosis, and the left eyelid was normal (Figure 1). Visual acuity was 20/20 in both eyes. Intraocular pressure was 18 and 16 mmHg in right and left eye, respectively. Slit-

ORCID IDs of the authors: A.M. 0000-0002-1712-5163; A.Ö.M. 0000-0003-0994-4465; N.B. 0000-0002-6755-2550; S.K. 0000-0001-91949841; İ.E.Y. 0000-0003-1154-425X.

Corresponding Author: Ayşe Özlem Mete **E-mail:** ayseozlem_ornek@hotmail.com

Received: 14.08.2017 • **Accepted:** 27.10.2017

©Copyright by 2018 Gaziantep University School of Medicine – Available online at www.eurjther.com

Figure 1. a-c. Temporally displaced right eyelid with mild proptosis

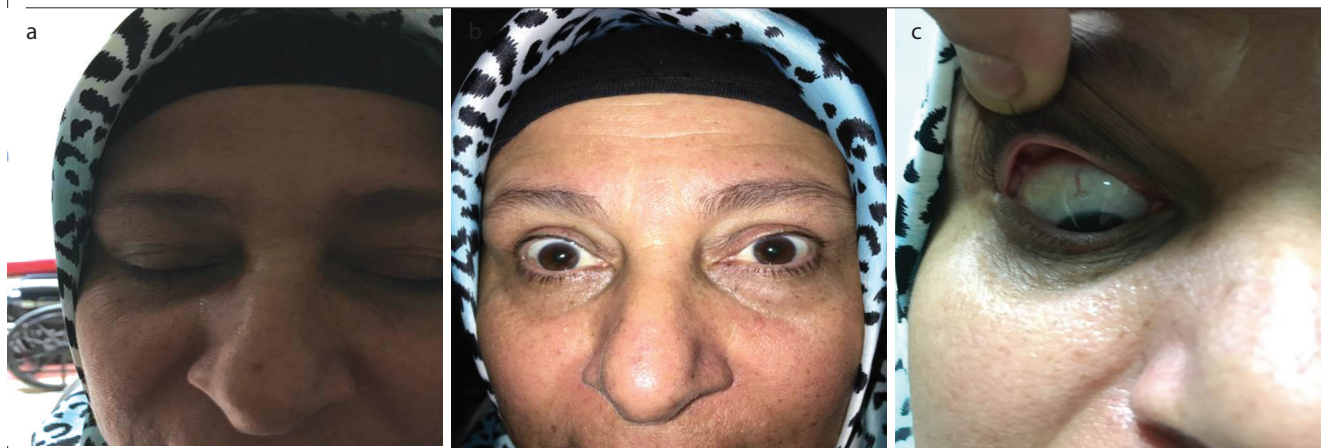
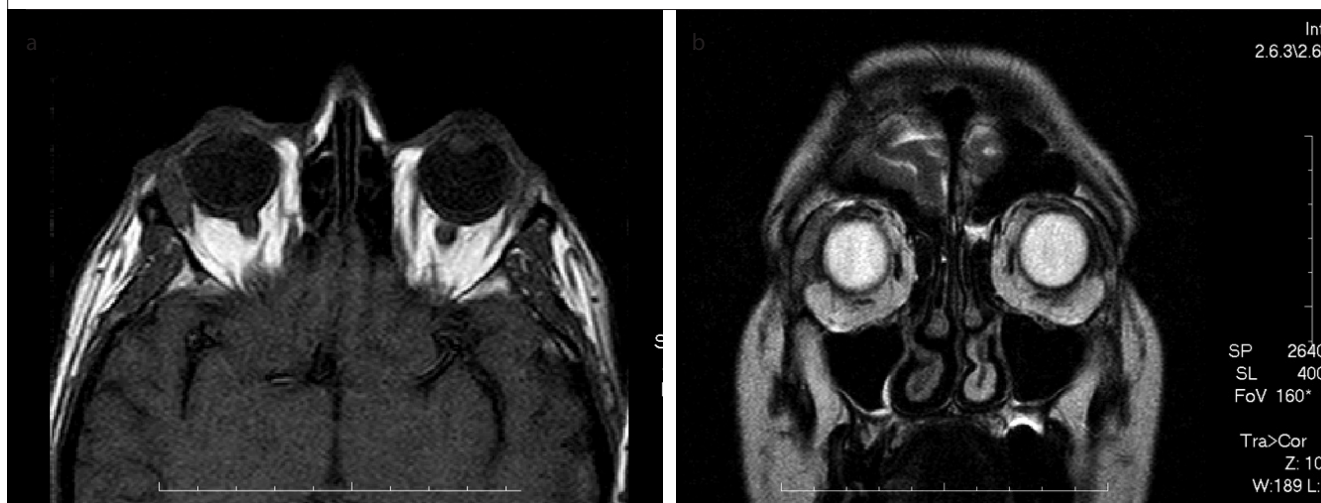


Figure 2. a, b. Axial and coronal magnetic resonance imaging shows unilateral right lacrimal gland enlargement



lamp examination and funduscopy findings were normal bilaterally. Direct and indirect pupillary light reflexes were normal. The Hertel exophthalmometry measurement was 19 mm in the right eye and 17 mm in the left eye. There was no restriction in the movement of either eyes, but lateral gaze with the right eye was painful. Laboratory examination results were hemoglobin (Hgb), 15.2 g/dL (13.6-17.2); C-reactive protein, 13.42 mg/L (0-5); erythrocyte sedimentation rate, 24 mm/h (1-20); white blood cell, $8.99 \times 10^3/\mu\text{L}$ (3.98-10.04) [neutrophil: 41.6% (34-71), lymphocyte: 48.3% (19.3-51.7)]; brucella immune capture agglutination test (Vircell Microbiologists, Granada, İspanya), positivetiter of 1/320; toxoplasma IgM, negative; cytomegalovirus IgM, negative; Epstein-Barr virus viral capsid antigen (EBV VCA) IgM, negative; and Gruber-Widal (Salmonella agglutination) test, negative. There was no growth on blood culture (BacT/Alert 3D, bioMerieux, Fransa). Magnetic resonance imaging showed marked contrast enhancement lateral to the lateral rectus muscle including the surrounding tissue, which was interpreted as an accompanying myositis of the lateral rectus muscle (Figure 2).

Oral rifampicin (600 mg/day), ciprofloxacin (1,500 mg/day), and lansaprazole (30 mg/day) were given to the patient for 6 weeks. At the first month control examination, patient's findings were

resolved without any sequelae and ophthalmic examination finding was normal.

Informed consent was obtained from the patient for the publication of this case report and images.

DISCUSSION

Brucellosis is a frequent disease in the southeastern region of Turkey. Although ocular involvements are uncommon, it may cause morbidity if left undiagnosed. Ocular brucellosis cases are mostly reported from endemic regions. In two different studies, Rolando (2) and Sungur (1) showed that the most frequent ocular manifestation is uveitis. Tabbara and Al-Kassimi (10) reported a patient with uveitis. The patient was not responsive to steroid treatment and the attacks were recurrent. They found that she had a paravertebral brucellar abscess, and she responded to systemic antibiotics and recovered. Although lacrimal gland infection with *B. melitensis* is infrequent, there are brucellosis cases that support exocrine gland involvement, such as mastitis and pancreatitis (11, 12). To the best of our knowledge, this case is the third case of *B. melitensis* infection after two dacryoadenitis cases reported by Bekir et al. (13, 14).

Diagnosis of ocular involvement of brucellosis is based on clinical ophthalmic examinations, microbiological culture of the associated ocular structure, and serology. Al Faran reported that *B. melitensis* is a causative organism of endophthalmitis by standard tube agglutination and culture of aqueous humor and vitreous (15). In our case, we confirmed the diagnosis based on serology and clinical findings.

Eye involvement of brucellosis can exist in both chronic and acute phases of the disease, but mostly occur in the chronic phase (2, 7). Patients not seeking medical care until the disease has progressed to the chronic phase, late diagnosis because of the diagnostic challenge, or like in our case, patient noncompliance to the treatment are the reasons why the brucellosis complicates.

Standard treatment of brucellosis is rifampin and doxycycline for 6-8 weeks. In case of ocular involvement, a combination of local and systemic corticosteroids for 2-4 weeks with antibiotic therapy leads to considerable improvement (2, 8). We treated our patient with rifampin and ciprofloxacin combination without corticosteroids for 6 weeks. The patient completely recovered.

Therefore, in this case, we conclude that the lacrimal gland is one of the glands that can be affected in brucellosis.

CONCLUSION

In conclusion, particularly in endemic regions, eye involvement of brucellosis should be considered. Through routine ophthalmic examination of brucellosis patients, the risk of blindness may be decreased.

Informed Consent: Informed consent was obtained from patient.

Peer-review: Externally peer-reviewed.

Author Contributions: Concept - A.M., S.K.; Design - N.A.B.; Supervision - N.A.B.; Resource - İ.A.Y., N.A.B.; Materials - İ.A.Y., N.A.B.; Data Collection and/or Processing - İ.E.Y., N.A.B.; Analysis and/or Interpretation - İ.A.Y., N.A.B.; Literature Search - A.Ö.M.; Writing - A.Ö.M., A.M., S.K.; Critical Reviews - A.Ö.M., A.M., S.K., N.A.B.

Conflict of Interest: No conflict of interest was declared by the authors.

Financial Disclosure: The authors declared that this study has received no financial support.

REFERENCES

1. Sungur GK, Hazirolan D, Gurbuz Y, Unlu N, Duran S, Duman S. Ocular involvement in brucellosis. *Can J Ophthalmol* 2009;44: 598-601. [\[CrossRef\]](#)
2. Rolando I, Olarte L, Vilchez G, Lluncor M, Otero L, Paris M, et al. Ocular manifestations associated with brucellosis: a 26-year experience in Peru. *Clin Infect Dis* 2008;46: 1338-45. [\[CrossRef\]](#)
3. Pappas G, Papadimitriou P, Akritidis N, Christou L, Tsianos EV. The new global map of human brucellosis. *The Lancet Infectious* 2006; 6: 91-99 [\[CrossRef\]](#)
4. <https://www.cdc.gov/brucellosis/transmission/index.html>
5. Solera J, Martinez-Alfaro E, Espinosa A. Recognition and optimum treatment of brucellosis. *Drugs* 1997; 53: 245-56. [\[CrossRef\]](#)
6. Ghasemi Barghi R, Meraat H, Pahlevan AA. A review on ophthalmic manifestations of brucellosis and reporting a case of ophthalmic brucellosis. *Iran Red Crescent Med J* 2011; 13: 352-3.
7. Güngör K, Bekir NA, Namıduru M. Ocular complications associated with brucellosis in an endemic area. *Eur J Ophthalmol* 2002; 12: 232-7. [\[CrossRef\]](#)
8. Rabinowitz R, Schneck M, Levy J, Lifshitz T. Bilateral multifocal chorioiditis with serous retinal detachment in a patient with brucella infection: case report and review of the literature. *Arch Ophthalmol* 2005; 123: 116-8. [\[CrossRef\]](#)
9. Güngör K, Bekir NA, Namıduru M. Recurrent episcleritis associated with brucellosis. *Acta Ophthalmol Scand* 2001; 79: 76-8. [\[CrossRef\]](#)
10. Tabbara KF, al-Kassimi H. Ocular brucellosis. *Br J Ophthalmol* 1990; 74: 249-50. [\[CrossRef\]](#)
11. Gasser I, Almirante B, Fernandez-Perez F, Mendoza C. Bilateral mammary abscess and uveitis caused by brucella melitensis - report of a case. *Infection* 1991; 19: 44-5. [\[CrossRef\]](#)
12. Odeh M, Oliven A. Acute pancreatitis associated with brucellosis. *J Gastroenterol Hepatol* 1995; 10: 691-2. [\[CrossRef\]](#)
13. Bekir NA, Güngör K, Namıduru M. Brucella melitensis dacryoadenitis: a case report. *Eur J Ophthalmol* 2000; 10: 259-61. [\[CrossRef\]](#)
14. Bekir NA, Güngör K. Bilateral dacryoadenitis associated with brucellosis. *Acta Ophthalmol Scand* 1999; 77: 357-8.
15. Al Faran MF. Brucella melitensis endogenous endophthalmitis. *Ophthalmologica* 1990; 201: 19-22. [\[CrossRef\]](#)

How to cite:

Metel A, Metel AÖ, Kimyon S, Yılmaz İE, Bekir NA, Unilateral *Brucella* Dacryoadenitis. *Eur J Ther* 2018; 24: 61–3.